

# Severe acute respiratory syndrome coronavirus 2 pneumonia and pulmonary embolism in a 66-year-old woman

Igor A. Harsch, Marcin Skiba, Peter C. Konturek

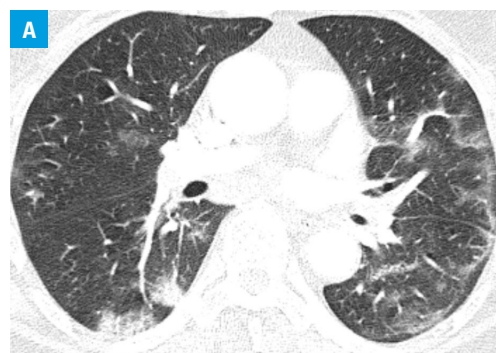
Department of Internal Medicine II, Thuringia Clinic "Georgius Agricola," Saalfeld, Germany

Elevated levels of D-dimer are discussed as a marker for an unfavorable outcome in severe acute respiratory syndrome coronavirus 2 infections. Zhang et al<sup>1</sup> reported significantly higher levels of D-dimer (as well as C-reactive protein and procalcitonin) as associated with a more severe course of the disease in an analysis of the records of 140 hospitalized patients with coronavirus disease 2019 (COVID-19). The authors discussed the elevated D-dimer levels as indicative of a sustained inflammatory response and disturbed coagulation after the infection. Other authors confirmed that elevated D-dimer levels are a negative prognostic factor, for example, Zhou et al<sup>2</sup> in a retrospective multicenter cohort study in 191 patients.

So far, there is limited data on whether SARS-CoV-2 infection also favors thromboembolic events. Danzi et al<sup>3</sup> recently reported the case of a 75-year-old patient (sinus rhythm on electrocardiogram) with a severe bilateral SARS-CoV-2 pneumonia and concomitant acute pulmonary embolism (no strong predisposing risk factors for venous thromboembolism). Xie et al<sup>4</sup> also reported 2 cases from Wuhan (57- and 70-year-old men) in which SARS-CoV-2 pneumonia was complicated by acute pulmonary embolism. Coronavirus disease 2019 with changes in the lung could theoretically induce a hypercoagulable state. The vascular response to (systemic) hypoxia is controlled by hypoxia-inducible transcription factors. The target genes of hypoxia-inducible transcription factors include factors regulating thrombus formation.<sup>5</sup>

We report the case of a 66-year-old woman who tested positive for COVID-19 one week before the admission. She was admitted to our clinic due to atrial fibrillation and because she felt as if she was about to faint (March 31, 2020). Furthermore, she complained of a light cough and rhinitis; she had no fever. For about 3 months,

she had had recurrent infections of the upper respiratory tract and reported loss of taste. She did not complain of chest pain and was hemodynamically stable. It could not be clarified whether the atrial fibrillation was a new-onset pathology or (very likely) a rather long-standing disorder. Otherwise, the patient was healthy, she was not hypertensive and did not have diabetes mellitus or thyroid disorders nor was she obese (body mass index, 25.2 kg/m<sup>2</sup>). We determined D-dimer levels for risk stratification of the severity of the disease and found they were elevated at 14 903 µg/l (reference range <230 µg/l). C-reactive protein levels were elevated with 95.9 mg/l (reference range <5 mg/l), procalcitonin levels were normal. Thus, we performed an unenhanced computed tomography scan of the thorax (FIGURE 1A) as well as computed tomography pulmonary angiography (FIGURE 1B). Bipulmonary ground-glass opacities with transition to consolidations compatible with COVID-19



**FIGURE 1 A** – axial unenhanced chest computed tomography showing bipulmonary ground-glass opacities, especially in the upper lobes, and opacities with a small consolidation in the peripheral dorsal portions emphasized on both sides in the lower lobes. A circumscribed consolidation in the posterior lobe is visible.

## Correspondence to:

Prof. Igor A. Harsch, MD, PhD,  
Department of Internal Medicine II,  
Thuringia Clinic Saalfeld "Georgius  
Agricola," Rainweg 68, 07318  
Saalfeld/Saale, Saalfeld, Germany,  
phone: +49(0)3671/541569,  
email: iharsch@thueringen-kliniken.de

Received: April 5, 2020.

Revision accepted: April 21, 2020.

Published online: May 1, 2020.

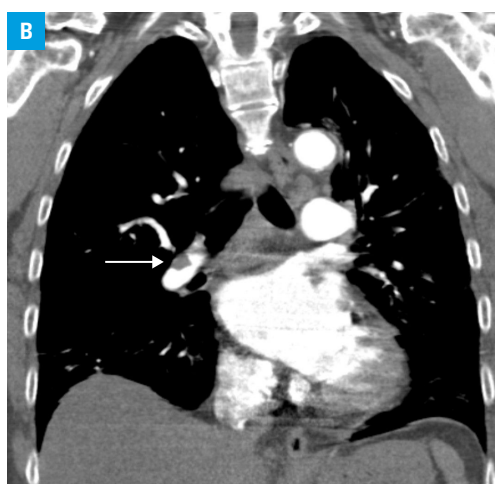
Pol Arch Intern Med. 2020;

130 (5): 438-439

doi:10.20452/pamw.15333

Copyright by the Author(s), 2020

**FIGURE 1 B** – coronal computed tomography showing contrast medium cutouts on the right in the right pulmonary artery (arrow) as well as bipulmonary at the segment no. 10 of the lung



viral pneumonia could be visualized. The imaging also demonstrated pulmonary arterial emboli on both sides in the lower lobes. Further, genetic risk factors such as loss of function mutations (deficiencies of antithrombin, protein C, protein S) and gain of function mutations (such as prothrombin mutation G20210A, factor V Leiden) were excluded and the patient was treated with apixaban. She was discharged on April 3, 2020. A specific therapy of the SARS-CoV-2 pneumonia, apart from inhalations, was not required.

Our as of yet limited database allows no conclusions about an elevated risk for pulmonary embolism in patients with SARS-CoV-2 pneumonia and with preexisting risk factors for such events as present in the current case. Analyzing the datasets of Zhou et al,<sup>2</sup> D-dimer levels were about 10-fold higher in the nonsurvivor group. In the case reported here, D-dimer levels were 65-fold higher. The case exemplifies that the presence of elevated D-dimer levels should not only be regarded as a risk factor for an unfavorable course of SARS-CoV-2 pneumonia but should also prompt physicians to exclude pulmonary embolism in patients with established risk factors for such events.

## ARTICLE INFORMATION

**ACKNOWLEDGEMENTS** The author is grateful to Roman Harsch (BA Translation) for language editing.

**CONFLICT OF INTEREST** None declared.

**OPEN ACCESS** This is an Open Access article distributed under the terms of the Creative Commons AttributionNonCommercialShareAlike 4.0 International License (CC BY-NC-SA 4.0), allowing third parties to copy and redistribute the material in any medium or format and to remix, transform, and build upon the material, provided the original work is properly cited, distributed under the same license, and used for noncommercial purposes only. For commercial use, please contact the journal office at pamw@mp.pl.

**HOW TO CITE** Harsch IA, Skiba M, Konturek PC. Severe acute respiratory syndrome coronavirus 2 pneumonia and pulmonary embolism in a 66-year-old woman. *Pol Arch Intern Med.* 2020; 130: 438-439. doi:10.20452/pamw.15333

## REFERENCES

- 1 Zhang JJ, Dong X, Cao YY, et al. Clinical characteristics of 140 patients infected with SARS-CoV-2 in Wuhan, China. *Allergy.* 2020 Feb 19. [Epub ahead of print].
- 2 Zhou F, Yu T, Du R, et al. Clinical course and risk factors for mortality of adult inpatients with COVID-19 in Wuhan, China: a retrospective cohort study. *Lancet.* 2020; 395: 1054-1062.

3 Danzi GB, Loffi M, Galeazzi G, Gherbesi E. Acute pulmonary embolism and COVID-19 pneumonia: a random association? *Eur Heart J.* 2020 Mar 30. [Epub ahead of print].

4 Xie Y, Wang X, Yang P, Zhang S. COVID-19 complicated by acute pulmonary embolism. *Radiology: Cardiothoracic Imaging.* 2020; 2: e200067.

5 Gupta N, Zhao YY, Evans CE. The stimulation of thrombosis by hypoxia. *Thromb Res.* 2019; 181: 77-83.