

Comparison of conventional and ultrasound-guided needle biopsy techniques in the diagnosis of sarcoidosis: a randomized trial

Maciej Gnass¹, Artur Szlubowski¹, Jerzy Soja², Piotr Kocoń³, Lucyna Rudnicka⁴, Adam Ćmiel⁵, Krzysztof Śladek², Jarosław Kuźdżał³

¹ Endoscopy Unit, John Paul II Hospital, Jagiellonian University Medical College, Kraków, Poland

² Department of Medicine, Jagiellonian University Medical College, Kraków, Poland

³ Department of Thoracic Surgery, John Paul II Hospital, Jagiellonian University Medical College, Kraków, Poland

⁴ Department of Pathology, John Paul II Hospital, Kraków, Poland

⁵ Department of Applied Mathematics, AGH University of Science and Technology, Kraków, Poland

KEY WORDS

endobronchial
ultrasound,
endoscopic
ultrasound-guided
needle aspiration,
sarcoidosis,
transbronchial needle
aspiration

ABSTRACT

INTRODUCTION Endoscopic biopsy techniques are useful in the diagnosis of sarcoidosis. There is a need for randomized trials to establish where these procedures fit in the diagnosis of sarcoidosis.

OBJECTIVES The aim of the study was to compare the diagnostic yield of conventional transbronchial needle aspiration (TBNA) with endobronchial ultrasound-guided TBNA (EBUS-TBNA) and endoscopic ultrasound-guided fine needle aspiration (EUS-FNA) in stages I and II of pulmonary sarcoidosis.

PATIENTS AND METHODS Patients suspected of sarcoidosis were randomized to undergo TBNA or EBUS-TBNA or EUS-FNA. Patients with negative TBNA and EBUS-TBNA results underwent EUS-FNA and those with negative EUS-FNA results—EBUS-TBNA. If both tests were negative, patients in stage I were scheduled for mediastinoscopy (MS) and those in stage II—for transbronchial lung biopsy (TBLB).

RESULTS In 100 patients, 34 TBNA, 30 EBUS-TBNA, and 36 EUS-FNA procedures were performed at baseline. TBNA was positive in 20 patients (58.8%); EBUS-TBNA, in 23 (76.7%); and EUS-FNA, in 31 patients (86.1%). In patients with negative biopsy results, the second procedure was performed. The results of EUS-FNA were positive in 9 patients and of EBUS-TBNA—in none. Of 17 patients with negative results of both procedures, MS was performed in 6 patients and was positive in 2. In the remaining 11 patients, sarcoidosis was confirmed by TBLB. Sensitivity and accuracy of TBNA compared with EBUS-TBNA and EUS-FNA were 62.5% and 64.7%, 79.3% and 80%, and 88.6% and 88.9%, respectively. Sensitivity and accuracy of EBUS-TBNA were higher ($P = 0.139$) and of EUS-FNA were significantly higher compared with TBNA ($P = 0.012$).

CONCLUSIONS In stages I and II of pulmonary sarcoidosis, endoscopic ultrasound is a reasonable approach but EUS-FNA seems to be the method of choice.

INTRODUCTION Sarcoidosis is a benign systemic granulomatous disorder of unknown etiology characterized by frequent pulmonary involvement. It is the most prevalent interstitial lung disease.^{1,2} A cytological and molecular mechanism and possible environmental triggers leading to the development of this systemic inflammatory disease, which can involve any tissue or organ, are still the subject of numerous interesting studies.¹⁻⁴ However, despite these efforts,

the pathomechanism of the disease remains unknown.

There are 5 stages of sarcoidosis based on chest radiography. Stage 0 is diagnosed when the chest radiograph shows no abnormalities, and stage I—when only mediastinal and/or hilar lymphadenopathy occurs. In stage II, lymphadenopathy is accompanied by lung involvement (nodular infiltration especially in the middle and upper areas). The diagnosis is established if a clinical and

Correspondence to:

Maciej Gnass, MD, Samodzielna Pracownia Endoskopii, Krakowski Szpital Specjalistyczny im.

Jana Pawła II, ul. Prądnicka 80, 31-202 Kraków, Poland, phone: +48 12 614 00 00, fax: +48 12 614 22 15,

e-mail: m.gnass@gmail.com

Received: December 11, 2014.

Revision accepted: March 19, 2015.

Published online: March 20, 2015.

Conflict of interest: none declared.

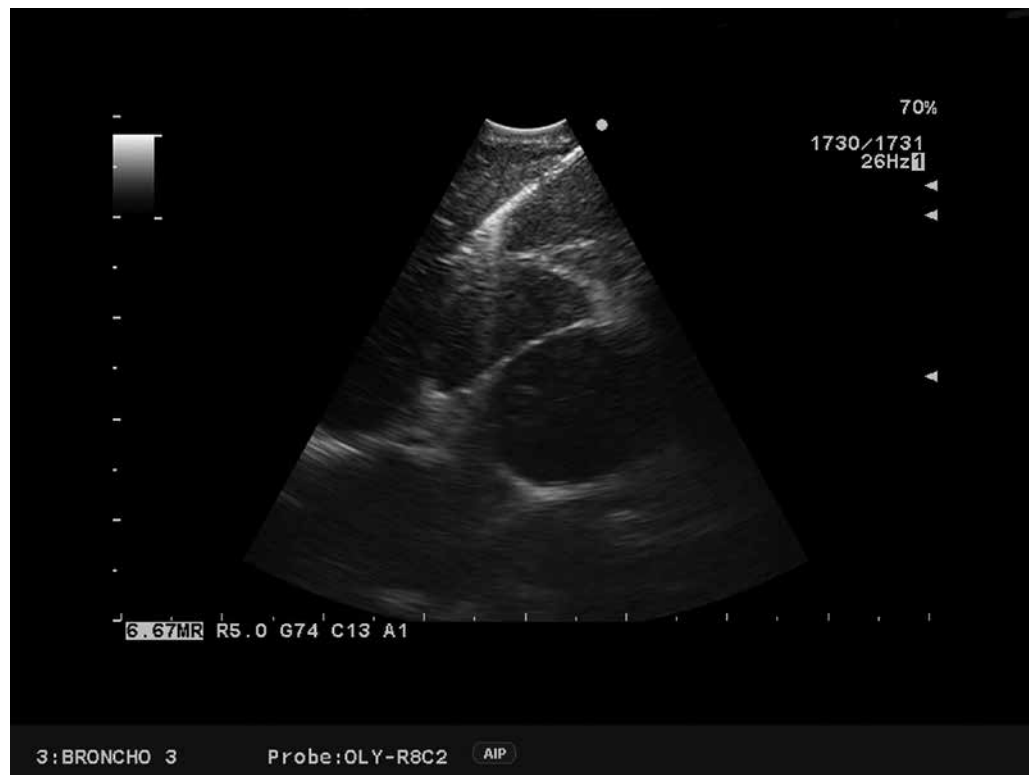
Pol Arch Med Wewn. 2015;

125 (5): 321-328

Copyright by Medycyna Praktyczna,

Kraków 2015

FIGURE 1 Endo-bronchial ultrasound-guided transbronchial needle aspiration imaging of right paratracheal nodes in sarcoidosis



radiological assessment, especially that based on high-resolution computed tomography, is supported by histological evidence of noncaseating epithelioid cell granulomas.⁵ According to current recommendations, diagnostic workup should include conventional bronchoscopy with endobronchial biopsy and transbronchial lung biopsy (TBLB). However, TBLB involves the risk of pneumothorax and hemoptysis and is not used as a standard technique in stage I. If the diagnosis of sarcoidosis is not confirmed by bronchoscopic findings, more invasive surgical procedures such as mediastinoscopy (MS) or video-assisted thoracic surgery (VATS) lung biopsy may be required. MS is associated with the best diagnostic yield for stages I and II of sarcoidosis.⁶ However, risk and cost-benefit analyses and the development of minimally invasive endoscopic procedures such as conventional (standard) transbronchial needle aspiration (TBNA) and endoscopic ultrasound techniques such as endobronchial and endoscopic ultrasound-guided fine needle aspiration (EBUS-TBNA and EUS-FNA, respectively) have markedly decreased the use of MS in this setting.⁶⁻¹⁴ Endosonography was introduced into clinical practice after numerous studies and showed excellent results in lung cancer staging and very promising results in sarcoidosis.¹³⁻¹⁸ However, it is unknown which of the following minimally invasive endoscopic techniques—TBNA, EBUS-TBNA, and EUS-FNA—could be the method of choice in patients suspected of stage I or II sarcoidosis and what would be its sensitivity, specificity, accuracy, positive predictive value (PPV), and negative predictive value (NPV).

Importantly, biopsy techniques presented above have not exactly the same range of lymph node stations for biopsy access. Using MS,

paratracheal (stations 2 and 4) and subcarinal (station 7) lymph nodes can be biopsied. Extended MS or VATS allows to reach also preaortic (5) and aortopulmonary window (6) lymph nodes, while TBNA allows to obtain samples from stations 2, 4, and 7. Both ultrasound methods (either EBUS-TBNA or EUS-FNA) allow the endoscopist to access stations 2, 4, and 7, except right paratracheal stations 2R and 4R, which are not accessible for EUS-FNA. Additionally, hilar (station 10), interlobar (station 11), and lobar (station 12) lymph nodes can be reached only by EBUS-TBNA, and paraesophageal (station 8) and pulmonary ligament (station 9) lymph nodes exclusively by EUS-FNA. In our study, the 3 biopsy techniques share the diagnostic area of stations 2, 4, and 7, which can be verified by MS.

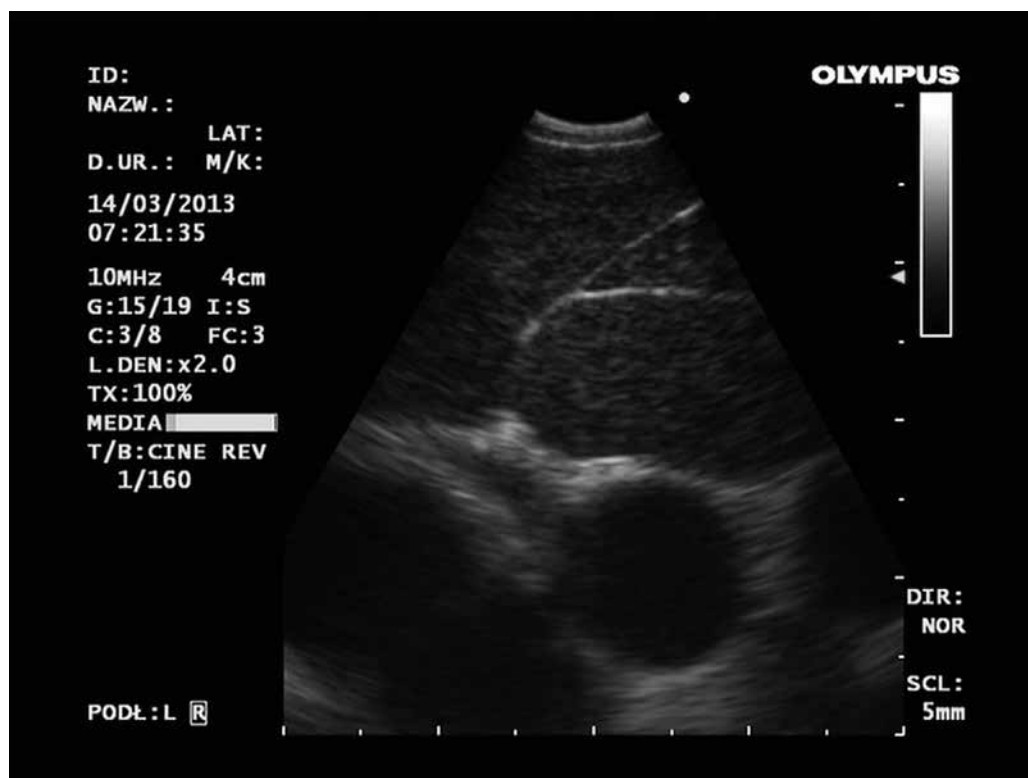This randomized study was designed to compare the diagnostic yield of TBNA with that of EBUS-TBNA and EUS-FNA, with the use of 21/22-gauge cytological needles, in patients clinically and radiologically suspected of sarcoidosis with mediastinal and hilar lymphadenopathy.

PATIENTS AND METHODS **Study design** This randomized controlled single-center, open-label study was conducted over a period of 1 year, since January 2012 to February 2013. The study was approved by the Ethics Committee of the Jagiellonian University in Kraków, and written informed consent was obtained from all patients.

The study was performed at the Endoscopy Unit and Department of Thoracic Surgery at John Paul II Hospital, Jagiellonian University, Kraków, Poland.

The study included a group of consecutive patients meeting the following inclusion criteria: age of 18 years or older; suspicion of sarcoidosis at

FIGURE 2 Endoscopic ultrasound imaging of subcarinal nodes in sarcoidosis



clinical stage I or II; enlarged mediastinal lymph nodes on computed tomography (short axis ≥ 10 mm); and the general condition allowing to perform MS, VATS, and TBLB.

The exclusion criteria were as follows: lack of patient's consent, a history of a bleeding disorder that could not be corrected, and sarcoidosis treatment using systemic corticosteroids and lasting more than 30 days before endoscopy.

Patients were randomized at the time of standard bronchoscopy to undergo conventional TBNA using 21/22-gauge needles or EBUS-TBNA or EUS-FNA using 22-gauge needles as a method additional to other bronchoscopy procedures. In each patient, 1 to 3 nodal stations were punctured and 3 to 5 passes were performed at each site.

All procedures were performed by 3 experienced endoscopists under local anesthesia and intravenous conscious sedation (fentanyl, 0.05–0.1 mg; midazolam, 1–5 mg).

In the TBNA group, the BF 1T180 video bronchoscope (Olympus Medical Systems Corporation, Tokyo, Japan) with the working channel of 3.0-mm was used. The biopsy was performed using the MW-122 (22-gauge/13 mm) or the SW-121 (21-gauge/15 mm) cytological needles (Conmed Endoscopic Technologies, Utica, United States) or the NA-411D-1521 (21-gauge/15 mm) (Olympus Medical Systems Corporation). All the biopsies were performed through the macroscopically normal bronchial wall. The preferred method of the biopsy was the pushing technique.

In the EBUS-TBNA group, after standard bronchoscopy, EBUS-TBNA was performed using the BF-UC160F-OL8 and BF-UC180F video bronchoscopes (Olympus Medical Systems Corporation), and intravenous sedation was added if necessary. The ultrasound videobronchoscopes were 6.9-mm

and 6.3-mm wide and had 2.0-mm and 2.2-mm working channels, respectively, and the oblique optical system of 35°. The 7.5 MHz EU-C60 and 5-12MHz EU-ME1 ultrasound processors were used, enabling tissue imaging at a depth of 20–50 mm. For biopsy, a cytological 40-mm 22-gauge needle with a guide wire and marking facilitating its ultrasound visualization was used (NA-201SX-4022, Olympus Medical Systems Corporation). All the biopsies were performed through the macroscopically normal bronchial wall (FIGURE 1).

In the EUS-FNA group, when standard video bronchoscopy was finished, the patient was turned over to his or her left side, and intravenous sedation was added if necessary. EUS-FNA was performed using GF-UCT160-OL5 video gastroscope (Olympus Medical Systems Corporation). The gastroscope's diameter was 14.6 mm, and it had the working channel of 3.7, optical system of 55°, and EU-C60 7.5 MHz ultrasound processor, enabling tissue imaging at a depth of 20 to 50 mm (FIGURE 2). For biopsy, a cytological 80-mm 22-gauge needle with a guide wire and marking facilitating its ultrasound visualization was used (NA-200H-8022, Olympus Medical Systems Corporation). EBUS-TBNA and EUS-FNA of lymph nodes of 5 mm or higher on the short axis were performed. The cytological smear of all biopsies was performed and fixed using ethanol (96%). The standard hematoxylin–eosin staining was used. Rapid on-site cytological evaluation was not performed. Samples from each lymph node station were placed separately and were reviewed by 2 clinical and research pathologists who were blinded to the sampling method.

All patients with negative TBNA or EBUS-TBNA results underwent EUS-FNA and those with negative EUS-FNA results underwent EBUS-TBNA.

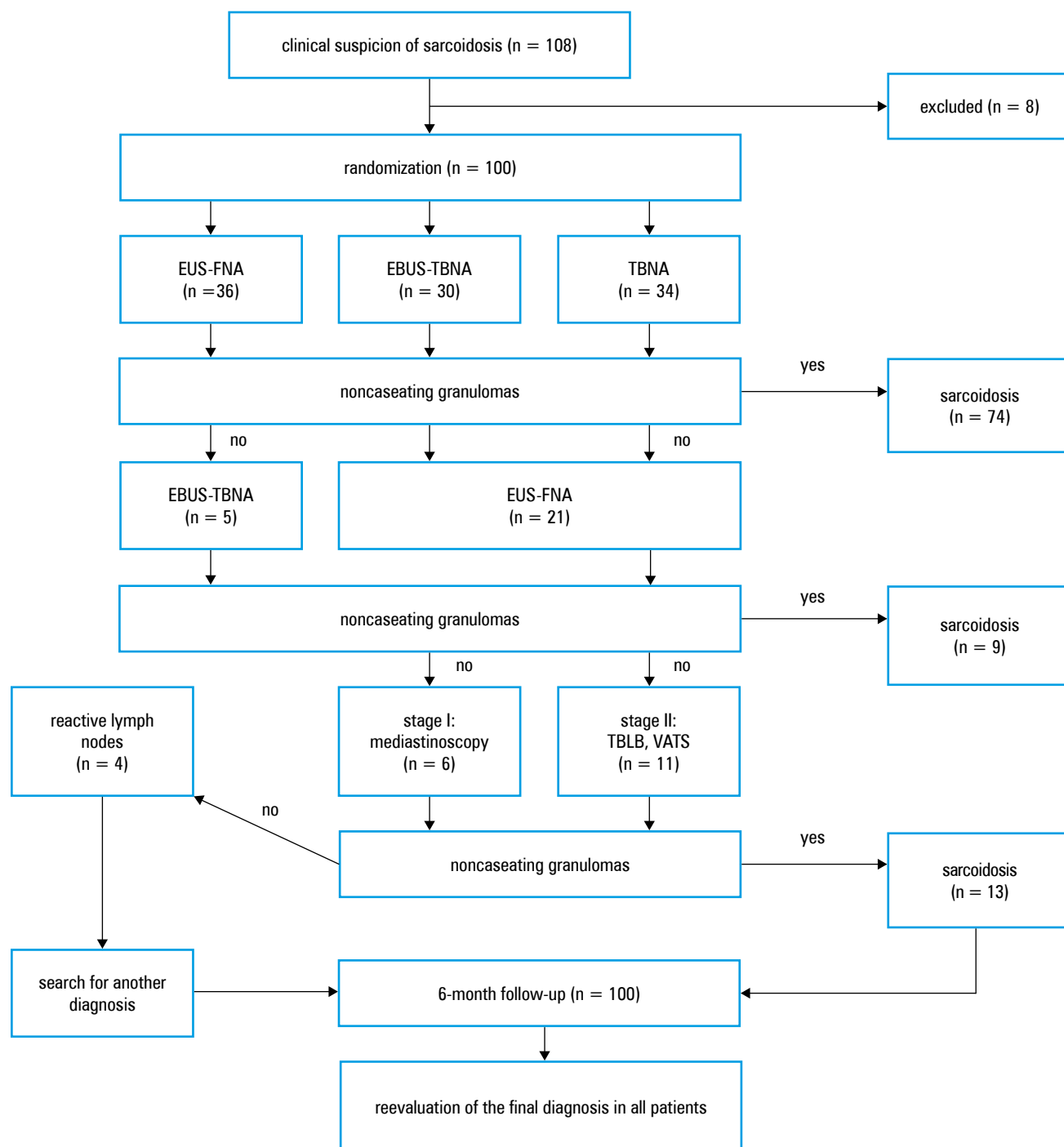


FIGURE 3 Flow chart of 108 patients suspected of pulmonary sarcoidosis

Abbreviations: EBUS-TBNA, endobronchial ultrasound-guided transbronchial needle aspiration; EUS-FNA, endoscopic ultrasound-guided fine needle aspiration; TBLB, transbronchial lung biopsy; TBNA, transbronchial needle aspiration; VATS, video-assisted thoracic surgery

If the results of both biopsy techniques were negative, patients with stage I sarcoidosis were then scheduled for MS and those with stage II sarcoidosis—for TBLB. The material from all biopsies was also cultured for tuberculosis. All patients were reevaluated during a 6-month follow-up (FIGURE 3).

Statistical analysis The sensitivity, specificity, accuracy, PPV, and NPV (including 95% confidence interval) were calculated using the GraphPad In-Stat 3.05 software (GraphPad Software, United States). The bootstrap method was used (using Statistica™ [Statsoft, United States]) to compare

the diagnostic values of different medical tests. Additionally, 2-sided uncorrected χ^2 test was used to compare the diagnostic yield of the 3 methods on the per-patient basis. The level of significance was set at a *P* value of 0.05 or less.

RESULTS A total of 108 patients were enrolled to this single-center study, of whom 8 were excluded. The data of 100 patients suspected of sarcoidosis were included in the final analysis. The primary outcome was the diagnostic yield for detecting noncaseating granulomas in 96% of the patients with the final diagnosis of sarcoidosis.

TABLE 1 Clinical characteristics of the patients

Characteristics	TBNA (n = 34)	EBUS-TBNA (n = 30)	EUS-FNA (n = 36)	<i>P</i> value
women/men	15/18	12/17	17/21	0.381
age, y	44.3 ± 14.2 (27–71)	42.9 ± 11.6 (24–59)	43.5 ± 12.1 (22–61)	0.907
smokers	7	3	4	
comorbidities				
ischemic heart disease	2	1	1	
arterial hypertension	2	1	2	
diabetes	1	0	1	

Data are presented as number or means ± standard deviation (range).

Abbreviations: see [FIGURE 3](#)

There were 44 women and 56 men at a mean age of 43.7 ± 13.1 years (range, 22–71 years). The major symptoms were cough (27%), fever (24%), articular pain (17%), and mild dyspnea (10%), but most of the patients were asymptomatic. Fourteen patients were current smokers. None of the patients had received sarcoidosis treatment with systemic corticosteroids for longer than 30 days before the endoscopy. The general condition of the patients allowed to perform endoscopic lung and mediastinal biopsy under mild sedation. In the study group, 5 patients had arterial hypertension; 4 patients, ischemic heart disease; and 2 patients, diabetes. There was no significant difference between the groups ([TABLE 1](#)).

In 100 patients, 34 standard TBNA, 30 EBUS-TBNA, and 36 EUS-FNA procedures were performed at baseline. The main study outcome measure of the diagnostic yield was 20 positive results for 34 TBNA procedures (58.8%) compared with 23 positive results for 30 EBUS-TBNA procedures (76.7%), and 31 positive results for 36 EUS-FNA procedures (86.1%), which means an absolute increase between the EBUS-TBNA and TBNA groups of 17.9% ($P = 0.129$) and between the EUS-FNA and TBNA groups of 27.3% ($P = 0.01$). The diagnostic sensitivity and accuracy of TBNA in comparison with EBUS-TBNA and EUS-FNA calculated on the per-patient basis were 62.5% and 64.7%, 79.3% and 80%, and 88.6% and 88.9%, respectively. The main outcome measures including the diagnostic yield of all methods per patient are presented in [TABLE 2](#). The sensitivity and accuracy of EUS-FNA were significantly higher compared with those of standard TBNA ($P =$

0.012 and $P = 0.015$, respectively). The sensitivity and accuracy of EBUS-TBNA was higher, but not significantly, compared with those of standard TBNA ($P = 0.139$ and $P = 0.163$, respectively). A comparison between the diagnostic yield of all 3 techniques is presented in [TABLE 3](#).

In 14 patients with negative results of standard TBNA and in 7 patients with negative results of EBUS-TBNA, EUS-FNA was performed, while in 5 patients with negative results of EUS-FNA, EBUS-TBNA was performed as the second procedure. Among them, EUS-FNA was positive in 9 patients and EBUS-TBNA—in none. In 17 patients with negative biopsy results, MS was performed in 6 patients, and sarcoidosis was confirmed in 2. In the remaining 11 patients, sarcoidosis was confirmed by TBLB. None of the patients required VATS lung biopsy.

A total of 164 mediastinal and hilar nodal stations were biopsied: subcarinal (7), 98; lower right paratracheal (4R), 16; lower left paratracheal (4L), 10; right hilar (10R), 20; left hilar (10L), 16; and paraesophageal (8), 4. The majority of the biopsies (60%) were performed in station 7.

Additional outcome measures included the diagnostic yield of the 3 methods calculated on the per lymph-node basis. When analyzed on the per-biopsy basis, significant differences between endosonography and TBNA in the diagnostic yield in mediastinal stations were observed, and no differences were revealed if mediastinal and hilar lymph node stations were biopsied by each method alone ([TABLE 4](#)).

No serious complications of any biopsy method were observed. A small bleeding at biopsy sites was not considered a complication. In 3 patients (2 after EBUS-TBNA and 1 after EUS-FNA), nausea was observed, most probably due to conscious sedation. There were no readmissions to the hospital due to pain or dysphagia for pain or dysphagia after EUS-FNA.

DISCUSSION A substantial body of data indicate that conventional TBNA allows to diagnose stage I or II sarcoidosis during initial bronchoscopic assessment, although the method relies on “blind” needle puncture guided only by computed tomography and is highly operator-dependent. Endosonography has become a standard technique showing high diagnostic yield for the diagnosis and staging of lung cancer, but its role in the diagnosis of sarcoidosis has not been clearly defined.^{7,11,14,15} EBUS-TBNA and EUS-FNA are

TABLE 2 Diagnostic yield of biopsy techniques calculated on the per-patient basis in diagnosing pulmonary sarcoidosis

Biopsy technique	Sensitivity, %	Specificity, %	Accuracy, %	PPV, %	NPV, %
TBNA	62.5 (44–79)	100 (16–100)	64.7 (48–79)	100 (83–100)	14.3 (2–43)
EBUS-TBNA	79.3 (60–92)	100 (25–100)	80 (62–91)	100 (85–100)	14.3 (4–58)
EUS-FNA	88.6 (73–97)	100 (25–100)	88.9 (74–96)	100 (89–100)	20 (5–72)

Data are presented as percentage (confidence interval).

Abbreviations: NPV, negative predicted value; PPV, positive predictive value; others, see [FIGURE 3](#)

TABLE 3 Comparison between the diagnostic yield of biopsy techniques calculated on the per-patient basis

Diagnostic yield	Biopsy techniques (<i>P</i> value)		
	TBNA/EBUS	TBNA/EUS	EBUS/EUS
sensitivity	0.139	0.012	0.306
accuracy	0.163	0.015	0.312
NPV	0.237	0.818	0.817

Abbreviations: see [FIGURE 3](#) and [TABLE 2](#)

minimally invasive techniques by which mediastinal and hilar lymph nodes can be aspirated under real-time ultrasound control from either the esophagus or large airways. Studies on the diagnostic value of both endosonographic methods showed their high yield in the diagnosis of sarcoidosis.^{13,14} There are only a few randomized controlled studies showing the superiority of EBUS-TBNA over standard TBNA^{19,20} and over routine bronchoscopic techniques including endobronchial and transbronchial lung biopsy.²¹ Only 2 small prospective studies reported a significantly higher yield for EBUS-TBNA (85%–94%) compared with TBLB (31%–37%) to detect granulomas.^{22,23}

It has not been established so far which of the techniques should be the method of choice in pulmonary sarcoidosis. Our study is novel because we compared 3 biopsy methods including EUS-FNA, which is rarely used by pulmonologists in the diagnosis of mediastinal adenopathy.

With the growing experience of pathologists, the demonstration of noncaseating epithelioid granulomas based on cytological material is feasible and reliable.^{9,13,24} Some authors point out the necessity for obtaining histological core tissue biopsies with a 19-gauge needle because histological evaluation is more reliable in the exclusion of lymphoproliferative disorders and tuberculosis (currently 19-gauge needles are available only for TBNA and EUS).^{25,26}

In our study, we compared cytological biopsies using 21/22-gauge needles, which makes the results more reliable. The results presented separately for all biopsy techniques (TBNA, 58.8%; EBUS-TBNA, 76.7%; and EUS-FNA, 86.1%) are consistent with other reports (TBNA, 46%–78%; EBUS-TBNA, 82%–93%; and EUS-FNA, 82%–100%).^{13,14,24,25,27} This prospective randomized study confirmed the superiority of

endosonographic methods over standard TBNA, demonstrating a significant increase in the diagnostic yield for EUS-FNA and a nonsignificant increase for EBUS-TBNA. It also showed a significantly higher sensitivity and accuracy of EUS-FNA compared with standard TBNA (*P* = 0.012). Moreover, a positive tendency was observed in higher sensitivity and accuracy of EBUS-TBNA compared with standard TBNA, which is consistent with other reports.^{19,20,24} No significant differences between the sensitivity and accuracy of EUS-FNA and EBUS-TBNA were observed, and additional studies on a higher number of patients are necessary to compare the diagnostic yield between both techniques.

When analyzed on the per-biopsy basis, there were significant differences between EUS-FNA and TBNA. As recommended, we performed 3 to 5 passes with standard TBNA for each station, and, although there are no recommendations for EBUS-TBNA and EUS-FNA, we also performed 3 to 5 passes with endosonographic methods, which might have resulted in an increased diagnostic yield on the per lymph-node basis.^{16,17,20,28} No differences were observed when any of the stations was biopsied by each method alone, which may be caused by the systemic character of granulomatous disease.

In all patients, the diagnosis was confirmed by the cytological and histological examination. Moreover, the patients were reviewed by an expert clinician 6 months after the biopsy was performed. Of 21 patients with negative TBNA and EBUS-TBNA results, sarcoidosis was diagnosed in 9 by EUS-FNA, but none of the 5 patients with negative EUS-FNA results had the diagnosis confirmed by EBUS-TBNA. This makes EUS-FNA a possible referral method for transbronchial techniques. MS was performed in 6 patients and reactive benign nodes were found in 4. It resulted in a small number of true negative patients, which is related to the strict inclusion criteria specifying that sarcoidosis is mainly based on clinical and radiological features. This also might have resulted in low and hardly reliable NPV. No specific diagnosis other than sarcoidosis was confirmed by endoscopies, MS, and TBLB or during clinical follow-up. No complications were noted after biopsies (a small bleeding at biopsy site was not treated as a complication) or after conscious sedation.

TABLE 4 Comparison between diagnostic yields of biopsy techniques calculated on the per lymph-node basis

Biopsy technique	Lymph node station	Sensitivity, %	Accuracy, %	PPV, %
TBNA	paratracheal (2, 4)	75 (43–95)	76.9 (48–93)	100 (66–100)
	subcarinal (7)	62.5 (44–79)	64.7 (48–79)	100 (83–100)
EUS-FNA	paratracheal (2, 4)	92.3 (64–100)	92.9 (63–99)	100 (74–100)
	subcarinal (7)	91.9 (82–97)	92.2 (83–96)	100 (94–100)

Data are presented as percentage (confidence interval).

Abbreviations: see [FIGURE 3](#) and [TABLE 2](#)

Conclusions In stages I and II of pulmonary sarcoidosis, the diagnostic yield of EBUS-TBNA and EUS-FNA are higher compared with that of TBNA, but the difference was significant only in the case of EUS-FNA. The use of endosonographic techniques is a reasonable approach but EUS-FNA seems to be the method of choice in patients suspected of sarcoidosis.

Contribution statement MG and AS conceived the idea for the study. MG, AS, JS, and PK contributed to the design of the research. MG, AS, JS, PK, LR, KS, and JK were involved in data collection. MG and AC analyzed the data. AS, JS, KS, and JK reviewed the manuscript. All authors edited and approved the final version of the manuscript.

REFERENCES

- 1 American Thoracic Society, European Respiratory Society, World Association of Sarcoidosis and Other Granulomatous Disorders. Statement on sarcoidosis: joint statement of the American Thoracic Society (ATS), the European Respiratory Society (ERS) and the World Association of Sarcoidosis and Other Granulomatous Disorders (WASOG) adopted by the ATS Board of Directors and by the ERS Executive Committee, February 1999. *Am J Respir Crit Care Med*. 1999; 160: 736-755.
- 2 Helbig G, Torba K, Pająk J, Kyrccz-Krzemien S. Sarcoidosis with bone marrow involvement, *Pol Arch Med Wewn*. 2014; 124: 427-428.
- 3 Osińska I, Wołosz D, Domagala-Kulawik J. Association between M1 and M2 macrophages in bronchoalveolar lavage fluid and tobacco smoking in patients with sarcoidosis. *Pol Arch Med Wewn*. 2014; 124: 359-364.
- 4 Piotrowski WJ, Mlynarski W, Fendler W, et al. Chemokine receptor CXCR3 ligands in bronchoalveolar lavage fluid: associations with radiological pattern, clinical course, and prognosis in sarcoidosis. *Pol Arch Med Wewn*. 2014; 124: 395-402.
- 5 Costabel U, Ohshimo S, Guzman J. Diagnosis of sarcoidosis. *Curr Opin Pulm Med*. 2008; 14: 455-461.
- 6 Venissac N, Alifano M, Mouroux J. Video-assisted mediastinoscopy: experience from 240 consecutive cases. *Ann Thorac Surg*. 2003; 76: 208-212.
- 7 Medford AR. Endobronchial ultrasound-guided transbronchial needle aspiration. *Pol Arch Med Wewn*. 2010; 120: 459-467.
- 8 Soja J, Szlubowski A, Kocot P, Czajkowski W, et al. Usefulness of transbronchial needle aspiration for initial lung cancer staging. *Pol Arch Med Wewn*. 2010; 120: 264-269.
- 9 Trisolini R, Tinelli C, Cancellieri A, et al. Transbronchial needle aspiration in sarcoidosis: yield and predictors of a positive aspirate. *J Thorac Cardiovasc Surg*. 2008; 135: 837-842.
- 10 Gasparini S, Zuccatosta L, De Nictolis M. Transbronchial needle aspiration of mediastinal lesions. *Monaldi Arch Chest Dis*. 2000; 55: 29-32.
- 11 Cetinkaya E, Yildiz P, Altin S, Yilmaz V. Diagnostic value of transbronchial needle aspiration by Wang 22-Gauge cytology needle in intrathoracic lymphadenopathy. *Chest*. 2004; 125: 527-531.
- 12 Szlubowski A, Kuzdzal J, Soja J, et al. Transbronchial needle aspiration as a diagnostic method in lung cancer and non-malignant mediastinal adenopathy. *Pneumonol Alergol Pol*. 2007; 75: 5-12.
- 13 Wong M, Yasufuku K, Nakajima T, et al. Endobronchial ultrasound: new insight for the diagnosis of sarcoidosis. *Eur Respir J*. 2007; 29: 1182-1186.
- 14 Annema JT, Veselic M, Rabe KF. Endoscopic ultrasound-guided fine-needle aspiration for the diagnosis of sarcoidosis. *Eur Respir J*. 2005; 25: 405-409.
- 15 Herth FJ, Eberhardt R, Vilmann P, et al. Real-time endobronchial ultrasound guided transbronchial needle aspiration for sampling mediastinal lymph nodes. *Thorax*. 2006; 61: 795-798.
- 16 Szlubowski A, Kuzdzal J, Kolodziej M, et al. Endobronchial ultrasound-guided needle aspiration in the non-small cell lung cancer staging. *Eur J Cardiothorac Surg*. 2009; 35: 332-335.
- 17 Annema JT, Rabe KF. EUS in Non-Small Cell Lung Cancer. In: Hawes H, Fockens P, eds. *Endosonography*. Saunders Elsevier. 2006; 7: 61-72.
- 18 Szlubowski A, Zieliński M, Soja J, et al. A combined approach of endobronchial and endoscopic ultrasound-guided needle aspiration in the radiologically normal mediastinum in non-small-cell lung cancer staging – a prospective trial. *Eur J Cardiothorac Surg*. 2010; 37: 1175-1179.
- 19 Herth F, Becker HD, Ernst A. Conventional vs endobronchial ultrasound guided transbronchial needle aspiration: a randomized trial. *Chest*. 2004; 125: 322-325.
- 20 Tremblay A, Stather DR, MacEachern P, et al. A randomized controlled trial of standard vs endobronchial ultrasonography-guided transbronchial

needle aspiration in patients with suspected sarcoidosis. *Chest*. 2009; 136: 340-346.

- 21 von Bartheld MB, Dekkers OM, Szlubowski A, et al. Endosonography vs conventional bronchoscopy for the diagnosis of sarcoidosis: the GRANULOMA randomized clinical trial. *JAMA*. 2013; 309: 2457-2464.
- 22 Navani N, Booth HL, Kocjan G, et al. Combination of endobronchial ultrasound-guided transbronchial needle aspiration with standard bronchoscopic techniques for the diagnosis of stage I and stage II pulmonary sarcoidosis. *Respirology*. 2011; 16: 467-472.
- 23 Oki M, Saka H, Kitagawa C, et al. Prospective study of endobronchial ultrasound-guided transbronchial needle aspiration of lymph nodes versus transbronchial lung biopsy of lung tissue for diagnosis of sarcoidosis. *J Thorac Cardiovasc Surg*. 2012; 143: 1324-1329.
- 24 Fritscher-Ravens A, Sriram PV, Topalidis T, et al. Diagnosing sarcoidosis using endosonography-guided fine needle aspiration. *Chest*. 2000; 118: 928-935.
- 25 Wang KP, Johns CJ, Fuenning C, Terry PB. Flexible transbronchial needle aspiration for the diagnosis of sarcoidosis. *Ann Otol Rhinol Laryngol*. 1989; 98: 298-300.
- 26 Morales CF, Patefield AJ, Strollo PJ Jr, Schenk DA. Flexible transbronchial needle aspiration in the diagnosis of sarcoidosis. *Chest*. 1994; 106: 709-711.
- 27 Oki M, Saka H, Kitagawa C, et al. Real-time endobronchial ultrasound-guided transbronchial needle aspiration is useful for diagnosing sarcoidosis. *Respirology*. 2007; 12: 863-868.
- 28 Garwood S, Judson MA, Silvestri G, et al. Endobronchial ultrasound for the diagnosis of pulmonary sarcoidosis. *Chest*. 2007; 132: 1298-1304.

Porównanie biopsji igłowej wykonywanej metodą konwencjonalną oraz pod kontrolą ultrasonografii w diagnostyce sarkoidozy: badanie z randomizacją

Maciej Gnass¹, Artur Szlubowski¹, Jerzy Soja², Piotr Kocoń³, Lucyna Rudnicka⁴, Adam Ćmiel⁵, Krzysztof Sładek², Jarosław Kuźdżał³

¹ Samodzielna pracownia Endoskopii, Szpital Jana Pawła II w Krakowie, Uniwersytet Jagielloński, Collegium Medicum, Kraków

² Wydział Lekarski, Uniwersytet Jagielloński, Collegium Medicum, Kraków

³ Oddział Chirurgii Klatki Piersiowej, Szpital Jana Pawła II w Krakowie, Uniwersytet Jagielloński, Collegium Medicum, Kraków

⁴ Zakład Patomorfologii, Szpital Jana Pawła II w Krakowie, Collegium Medicum, Kraków

⁵ Wydział Matematyki Stosowanej, Akademia Górniczo-Hutnicza w Krakowie, Collegium Medicum, Kraków

SŁOWA KLUCZOWE

*endobronchial
ultrasound,
endoscopic
ultrasound-guided fine
needle aspiration,
sarkoidoza,
transbronchial needle
aspiration*

STRESZCZENIE

WPROWADZENIE Endoskopowe techniki biopsyjne są użyteczne w diagnostyce sarkoidozy. Istnieje potrzeba prowadzenia badań z randomizacją w celu ustalenia ich miejsca w diagnostyce sarkoidozy.

CELE Celem niniejszego badania było porównanie wartości diagnostycznej konwencjonalnej przezoskrzelowej aspiracyjnej biopsji igłowej (*transbronchial needle aspiration* – TBNA) z wewnątrzoskrzelową (*endobronchial ultrasound-guided TBNA* – EBUS-TBNA) i endoskopową biopsją cienkoigłową wykonywaną pod kontrolą ultrasonografii (*endoscopic ultrasound-guided fine needle aspiration* – EUS-FNA) w stadium I i II sarkoidozy płucnej.

PACJENCI I METODY U pacjentów z podejrzeniem sarkoidozy wykonano w sposób losowy TBNA lub EBUS-TBNA, lub EUS-FNA. U pacjentów z ujemnym wynikiem badania TBNA i EBUS-TBNA wykonano badanie EUS-FNA, natomiast u pacjentów z ujemnym wynikiem EUS-FNA wykonano EBUS-TBNA. W przypadku ujemnego wyniku obu badań pacjentów w stadium I sarkoidozy kwalifikowano do mediastinoskopii (MS), a w stadium II – do przezoskrzelowej biopsji płuca (*transbronchial lung biopsy* – TBLB).

WYNIKI U 100 pacjentów przeprowadzono wyjściowo 34 zabiegi TBNA, 30 EBUS-TBNA i 36 EUS-FNA. Wynik TBNA był dodatni u 20 (58,8%), EBUS-TBNA u 23 (76,7%) a EUS-FNA u 31 (86,1%) pacjentów. W grupie pacjentów z ujemnym wynikiem biopsji przeprowadzono drugą procedurę. EUS-FNA dała wynik dodatni u 9 pacjentów, a EBUS-TBNA u żadnego. Spośród 17 pacjentów z ujemnym wynikiem po obu procedurach u 6 wykonano MS, której wynik był dodatni u 2 z nich. U pozostałych 11 pacjentów diagnozę sarkoidozy potwierdzono za pomocą TBLB. Czulość i dokładność TBNA w porównaniu z EBUS-TBNA i EUS-FNA wyniosły odpowiednio 62,5% i 64,7%, 79,3% i 80,0% oraz 88,6% i 88,9%. Czulość i dokładność EBUS-TBNA były wyższe ($p = 0,139$), a EUS-FNA znamienne wyższa w porównaniu z TBNA ($p = 0,012$).

WNIOSKI Użycie ultrasonografii endoskopowej w stadium I i II sarkoidozy płucnej jest racjonalnym podejściem, ale EUS-FNA wydaje się metodą z wyboru.

Adres do korespondencji:

lek. Maciej Gnass, Samodzielna
Pracownia Endoskopii, Krakowski
Szpital Specjalistyczny
im. Jana Pawła II, ul. Prądnicka 80,
31-202 Kraków, tel.: 12 614 00 00,
fax: 12 614 22 15,
e-mail: m.gnass@gmail.com
Praca wpłynęła: 11.12.2014.
Przyjęta do druku: 19.03.2015.
Publikacja online: 20.03.2015.
Nie zgłoszono sprzeczności
interesów.

Pol Arch Med Wewn. 2015;
125 (5): 321-328
Copyright by Medycyna Praktyczna,
Kraków 2015