

Infective endocarditis of the aortic valve in a patient with a coronary artery fistula

Marta Kamińska¹, Janina Lewkowicz², Adam Łukasiewicz³,
Tomasz Hirnle², Robert Trzciński², Bożena Sobkowicz¹

¹ Department of Cardiology, Medical University of Białystok, Białystok, Poland

² Department of Cardiac Surgery, Medical University of Białystok, Białystok, Poland

³ Department of Radiology, Medical University of Białystok, Białystok, Poland

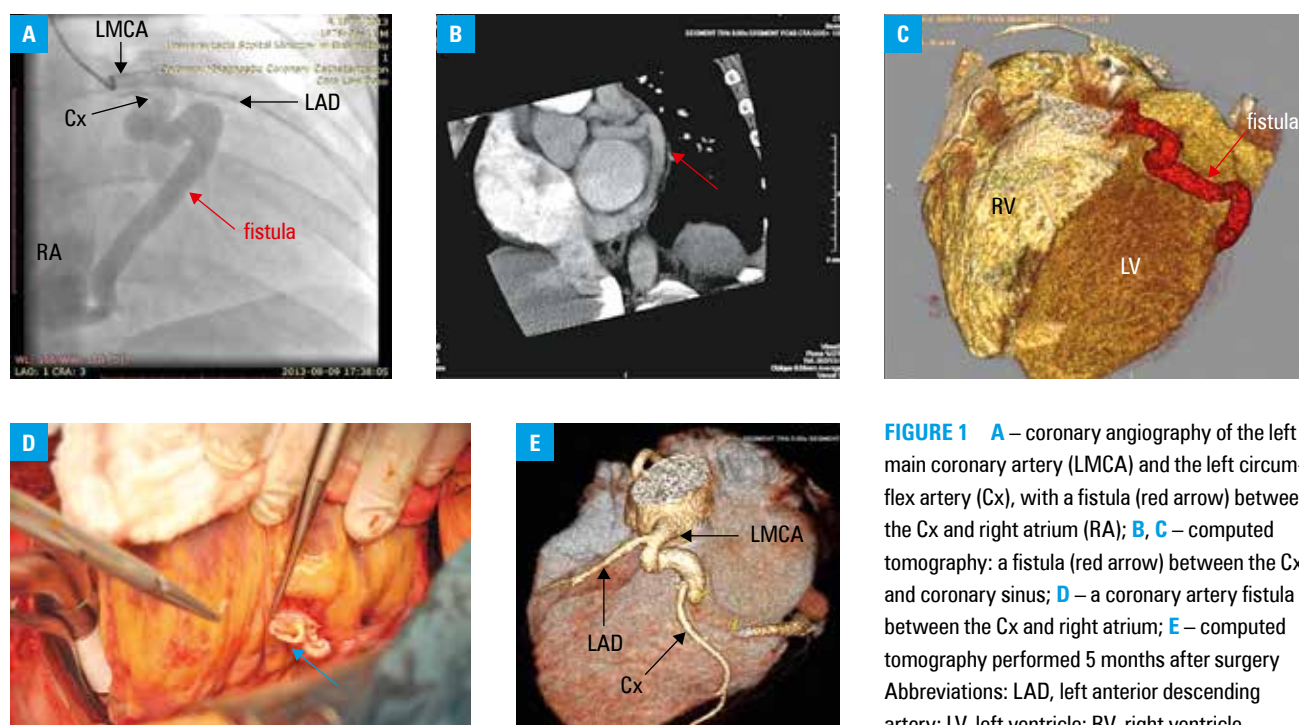


FIGURE 1 **A** – coronary angiography of the left main coronary artery (LMCA) and the left circumflex artery (Cx), with a fistula (red arrow) between the Cx and right atrium (RA); **B, C** – computed tomography: a fistula (red arrow) between the Cx and coronary sinus; **D** – a coronary artery fistula between the Cx and right atrium; **E** – computed tomography performed 5 months after surgery
Abbreviations: LAD, left anterior descending artery; LV, left ventricle; RV, right ventricle

A 38-year-old man was admitted to our institution because of acute biventricular heart failure. He reported dry cough, reduced exercise tolerance, exertional dyspnea, and a single episode of fever 4 months earlier, with a sudden deterioration 2 weeks before admission. Laboratory tests showed an increased leukocyte count, elevated C-reactive protein level, and evidence of renal and liver failure. Blood cultures were negative. Transthoracic echocardiography revealed tricuspid aortic valve, ruptured left coronary leaflet with a mobile vegetation protruding into the left ventricular outflow tract (15 × 3 mm), and significant aortic regurgitation. The left ventricle was dilated (71 mm) with reduced ejection fraction (EF,

35%). Transesophageal echocardiography demonstrated marked dilation of the left main coronary artery (LMCA), up to 1 cm with turbulent flow. Invasive coronary angiography showed ectasia of both LMCA and the left circumflex artery (Cx), with a communication between the Cx and the right atrium (**FIGURE 1A**). Computed tomography (CT) revealed a fistula between the Cx and coronary sinus (**FIGURE 1BC**). A surgical evaluation confirmed inflammatory destruction of the left coronary cusp and a coronary artery fistula (CAF) between the Cx and right atrium (**FIGURE 1D**). The patient underwent uneventful mechanical aortic valve implantation (Sorin 27) and occlusion of the CAF.

Correspondence to:

Marta Kamińska, MD, PhD, Klinika Kardiologii, Uniwersytet Medyczny w Białymstoku, ul. Marii Skłodowskiej-Curie 24A, 15-276 Białystok, Poland, phone: +48 85 8318 656, fax: +48 85 8318 604, e-mail: apile1@wp.pl
Received: June 16, 2015.
Accepted: June 30, 2015.
Published online: July 3, 2015.
Conflict of interest: none declared.
Pol Arch Med Wewn. 2015; 125 (7-8): 584-585
Copyright by Medycyna Praktyczna, Kraków 2015

At 5 months, the patient was free from symptoms, and EF significantly improved (51%). A follow-up CT scan confirmed the epicardial closure of the fistula with normal flow in the Cx (FIGURE 1E).

This case illustrates an uncommon association between a CAF and infective endocarditis of the aortic valve. The CAF is a rare congenital vascular anomaly that constitutes from 0.1% to 0.4% of cases with congenital heart disease¹ and is an incidental finding in 0.1% of coronary angiograms.² CAFs are mostly asymptomatic; however, some of them may cause myocardial ischemia, arrhythmias, or congestive heart failure and are associated with risk of complications such as infective endocarditis, coronary rupture, or sudden death.³ Infective endocarditis has been reported to occur in 4% to 10% of patients with a CAF.^{4,5} In the literature (publications between 2000 and 2015), we identified 18 reports of patients with a CAF complicated by infective endocarditis. In our patient, in the absence of positive blood culture results, we were unable to determine the cause of infective endocarditis. Therefore, the CAF could either cause or contribute to the rapid progression of the disease with a deterioration of the patient's clinical status.

REFERENCES

- 1 Wilkins CE, Betancourt B, Mathur VS, et al. Coronary artery anomalies. *Tex Heart Inst J*. 1988; 15: 166-173.
- 2 Vavuranakis M, Bush CA, Boudoulas H. Coronary artery fistulas in adults: incidence, angiographic characteristics, natural history. *Cathet Cardiovasc Diagn*. 1995; 35: 116-120.
- 3 Said SA. Current characteristics of congenital coronary artery fistulas in adults: A decade of global experience. *World J Cardiol*. 2011; 3: 267-277.
- 4 Tirilomis T, Aleksic I, Bisch T, et al. Congenital coronary artery fistulas in adults: surgical treatment and outcome. *Int J Cardiol*. 2005; 98: 57-59.
- 5 Liberthson RR, Sagar K, Berkoben JP, et al. Congenital coronary arteriovenous fistula. Report of 13 patients, review of the literature and delineation of management. *Circulation*. 1979; 59: 849-54.