

Rapidly progressive interstitial lung fibrosis in a patient with amyopathic dermatomyositis and anti-MDA5 antibodies

Jacek Górka¹, Wojciech Szczeklik¹, Anna Włodarczyk¹,
Piotr Łoboda², Łukasz Chmura³, Jacek Musiał¹

¹ Department of Allergy and Immunology, University Hospital, Jagiellonian University, Medical College, Kraków, Poland

² Division of Radiology, Department of Allergology and Immunology, University Hospital, Jagiellonian University, Medical College, Kraków, Poland

³ Department of Pathomorphology, Jagiellonian University, Medical College, Kraków, Poland

Clinically amyopathic dermatomyositis (CADM) is a unique subset of dermatomyositis, with typical skin manifestations of dermatomyositis but little or no evidence of muscle inflammation.^{1,2} CADM may be complicated by rapidly progressive interstitial lung disease, which is usually life-threatening and resistant to immunosuppressive therapy.³ Anti-MDA5 antibodies (also known as CADM-140) have been described in dermatomyositis, especially in CADM.⁴ Anti-MDA5-positive patients are characterized by rapidly progressive interstitial lung disease and a very high mortality rate at 6 months.⁵ Interestingly, the role of anti MDA-5 antibodies in Caucasian population is not well established.

A 59-year-old man with a 3-week history of nonproductive cough, fever, fatigue, and swollen joints was hospitalized with an initial diagnosis of acute pneumonia. On admission, a chest computed tomography scan revealed bilateral infiltrations with atelectasis in the lower lobes of the lungs (**FIGURE 1A**). During the first hospital day, the patient's condition rapidly deteriorated with increased tachypnea. An arterial gas analysis showed a pH of 7.26, pO₂ of 55 mmHg, and pCO₂ of 62 mmHg. He was transferred to an intensive care unit where he was intubated and mechanical ventilation was initiated.

On admission to the intensive care unit, several signs suggesting amyopathic dermatomyositis such as mechanic's hands, Gottron sign, and palmar papules were noted. Laboratory tests showed no evidence of myositis (creatinine kinase levels were within the reference range, while the levels of alanine transaminase and aspartate transaminase were slightly elevated). A wide-spectrum antimicrobial treatment started earlier was modified and continued but all microbiological cultures

(arterial and venous blood, bronchoalveolar lavage, urine) yielded negative results. High doses of corticosteroids were initiated and an enzyme-linked immunosorbent assay for serum antinuclear antibodies and an immunoprecipitation assay for autoimmune inflammatory myopathy serum antibodies were performed.

Despite treatment and modifications of ventilator settings, pulmonary compliance (respiratory rate, 30 bpm; tidal volume, ≈410 ml; peak inspiratory pressure, 34 cm H₂O) and arterial blood oxygenation decreased with signs of severe respiratory acidosis (PaO₂, 67.7 mmHg; PaCO₂, 95.7 mmHg; pH, 7.08; FiO₂, 1.0). On hospital day 5, prone ventilation was started but no significant improvement in respiratory function parameters was observed. Venovenous extracorporeal membrane oxygenation was introduced (**FIGURE 1B**).

Despite these efforts, the patient's status deteriorated rapidly with the development of multi-organ dysfunction (acute kidney injury, liver failure) and excessive bleeding, most probably due to disseminated intravascular coagulation. Previously ordered autoantibody tests were highly positive for anti-MDA5 antibodies. The patient died on day 8. On autopsy, a gross examination revealed an uneven surface of the visceral pleura as well as increased density and evidence of abundant congestion of both lungs. Features of interstitial pneumonia were confirmed by a histological examination. A total of 6 samples were taken, 3 from each lung. Specimens showed diffuse involvement of lung parenchyma by severe generalized interstitial fibrosis (**FIGURE 1C**) with mild-to-moderate (predominantly lymphocytic) inflammatory infiltrate (**FIGURE 1D**).

The pattern described above is most consistent with a fibrotic variant of nonspecific interstitial

Correspondence to:

Prof. Jacek Musiał, MD, PhD,
II Katedra Chorób Wewnętrznych,
Uniwersytet Jagielloński, Collegium
Medicum, ul. Skawińska 8,
31-066 Kraków, Poland,
phone/fax: +48 12 430 52 66,
e-mail: mmmusia@cyf-kr.edu.pl

Received: July 4, 2015.

Revision accepted: July 15, 2015.

Published online: July 22, 2015.

Conflict of interest: none declared.

Pol Arch Med Wewn. 2015;

125 (9): 685-686

Copyright by Medycyna Praktyczna,
Kraków 2015

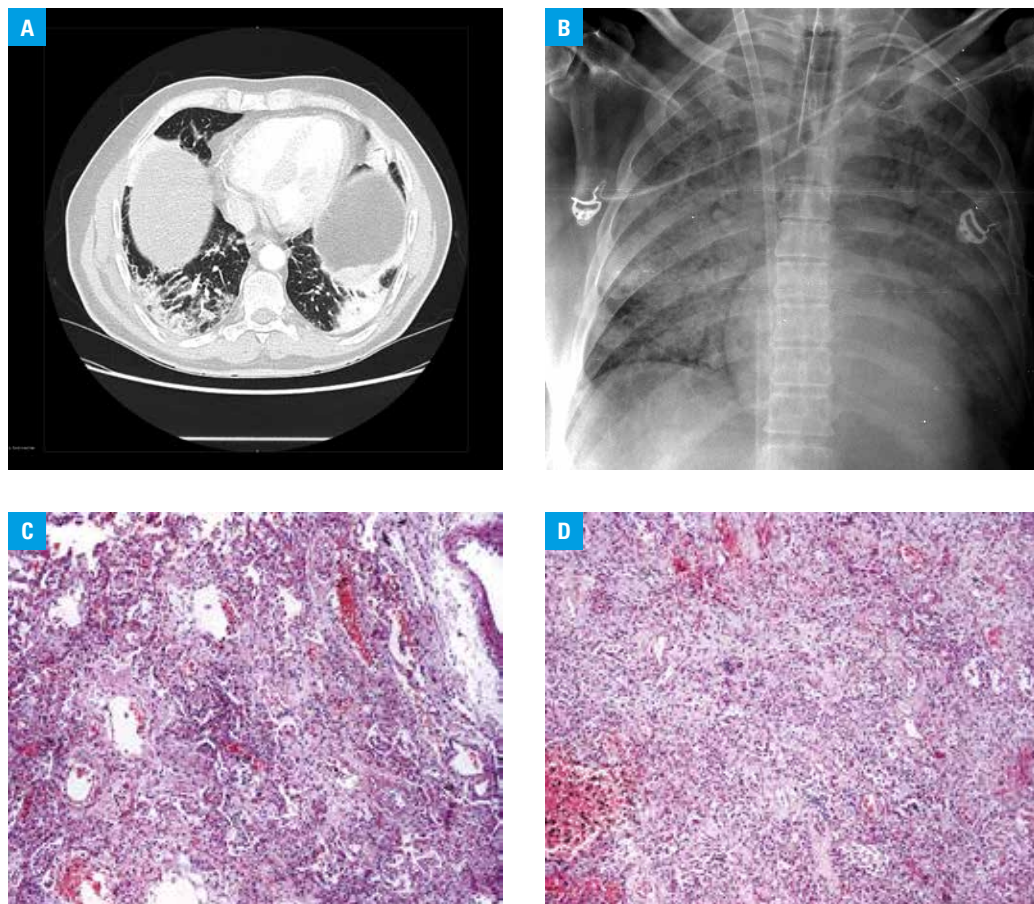


FIGURE 1 **A** – a lung computed tomography scan: bilateral patchy areas of consolidation and ground glass opacities limited to the lower lobes of the lungs; locally there are single accompanying nonseptal linear opacities; **B** – a chest X-ray: massive (apparent in all lung zones) bilateral areas of consolidation without obvious volume loss. An extracorporeal membrane oxygenation cannula is also visible; **C** – marked interstitial fibrosis: this pattern was seen in most of lung parenchyma; **D** – moderate lymphocytic lung infiltrate

pneumonia. Changes in other organs included focal, nonspecific areas of fibrosis in the myocardium and moderate steatosis of the liver.

REFERENCES

- 1 Sato S, Kuwana M. Clinically amyopathic dermatomyositis. *Curr Opin Rheumatol.* 2010; 22: 639-643.
- 2 Dalakas MC. Inflammatory muscle diseases. *N Engl J Med.* 2015; 372: 1734-1747.
- 3 Sato S, Hoshino K, Satoh T, et al. RNA helicase encoded by melanoma differentiation-associated gene 5 is a major autoantigen in patients with clinically amyopathic dermatomyositis: association with rapidly progressive interstitial lung disease. *Arthritis Rheum.* 2009; 60: 2193-2200.
- 4 Sato S, Hirakata M, Kuwana, et al. M. Autoantibodies to a 140-kd polypeptide, CADM-140, in Japanese patients with clinically amyopathic dermatomyositis. *Arthritis Rheum.* 2005; 52: 1571-1576.
- 5 Cao H, Pan M, Kang Y, et al. Clinical manifestations of dermatomyositis and clinically amyopathic dermatomyositis patients with positive expression of antimelanoma differentiation-associated gene 5 antibody. *Arthritis Care Res (Hoboken).* 2012; 64: 1602-1610.