

Unresectable heart neuroblastoma in an adult: a natural follow-up

Marta Kałużna-Oleksy¹, Hanna Wachowiak-Baszyńska¹, Jacek Migaj¹,
Sebastian Stefaniak², Magdalena Mróz¹, Ewa Straburzyńska-Migaj¹

¹ I Department of Cardiology, Poznan University of Medical Science, Poznań, Poland

² Department of Cardiac and Transplantology Surgery, Cardio-Thoracic Surgery, Poznan University of Medical Science, Poznań, Poland

A 39-year-old woman was admitted to our department for diagnostic work-up. At the age of 21 years, she underwent surgery and radiotherapy for neuroblastoma of the lumbar spine. Ten years later, she was treated twice with radiofrequency ablation due to ventricular arrhythmia. At the age of 38 years, she was hospitalized because

of heart failure decompensation (reduced exertion tolerance and paroxysmal palpitations) and sustained ventricular tachycardia. Transthoracic echocardiography showed a suspicion of a tumor in the right ventricular outflow tract (RVOT) (FIGURE 1A and 1B). There was no evidence of heart tumor in previous examinations. Cardiac

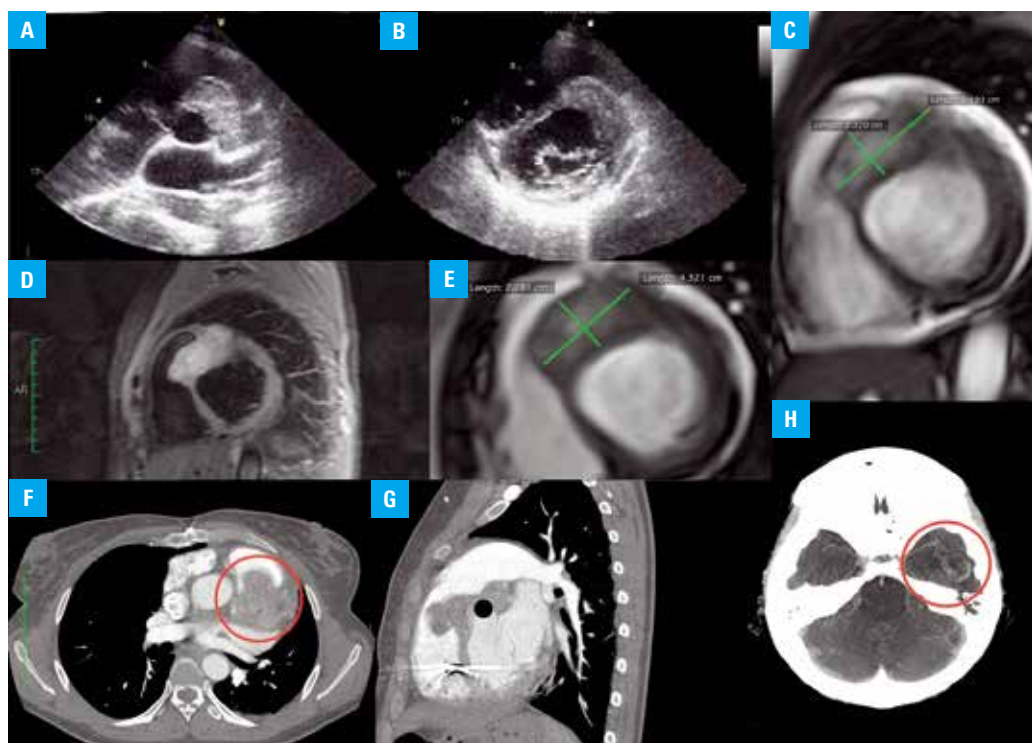


FIGURE 1A Transthoracic echocardiography, parasternal short-axis view (aortic valve level), a tumor results in the right ventricular outflow tract obstruction; **B** – transthoracic echocardiography, parasternal short-axis view (mitral valve level), tumor in the interventricular septum; **C** – cardiac magnetic resonance imaging, T_2 -weighted image of the primary cardiac tumor: the first examination (short-axis view); **D** – cardiac magnetic resonance imaging, T_2 -weighted triple inversion recovery TSE (Black-Blood turboSTIR); **E** – cardiac magnetic resonance imaging, T_2 -weighted image of the tumor 4 months later (short-axis view); **F** – chest computed tomography (CT) 5 minutes after contrast infusion (transversal axis); **G** – chest CT 5 minutes after contrast infusion (sagittal axis); **H** – brain CT revealing a large tumor (30 × 25 × 25 mm) in the temporal lobe (one of the brain metastases)

Correspondence to:
Marta Kałużna-Oleksy, MD, PhD,
I Klinika Kardiologii, Uniwersytet
Medyczny w Poznaniu, ul. Długa 1/2,
61-848 Poznań, Poland,
phone: +48 61 854 91 56,
e-mail: marta.kaluzna@wp.pl
Received: March 23, 2016.
Revision accepted: May 12, 2016.
Conflict of interest: none declared.
Pol Arch Med Wewn. 2016;
126 (5): 365-366
doi:10.20452/pamw.3425
Copyright by Medycyna Praktyczna,
Kraków 2016

magnetic resonance imaging in T1, T2, SE TSE GRE, and cine-MR sequences before and after the contrast phase (FIGURE 1C, 1D, and 1E) was performed to confirm the diagnosis. The study revealed the exact position of the tumor, with the hypokinetic left ventricle dilated to 57 mm, and with an ejection fraction of about 30%. The tumor (23 × 43 mm), located in the interventricular septum, extended to the papillary muscles and protruded to the RVOT, causing its obstruction (high fibrotic component). A histopathological diagnosis was neuroblastoma, based on a surgical biopsy after an unsuccessful attempt at a percutaneous biopsy. The diagnosis was confirmed using immunohistochemical stain analysis (NSE+/CD56+/NF-(single cells+)/Flil-(single nuclei+)/cytokeratin (AE1/AE3)-/CD57-/Ki67 <10%).

The patient could not be referred for surgery (because of the tumor localization), or for chemotherapy (because of low EF and low tumor proliferation index [Ki67 <10%]), or for radiotherapy (because of high risk of damaging implantable-cardioverter defibrillator electrodes; DDDCD was implanted as secondary prevention). A 64-slice computed tomography of the chest was performed to monitor the tumor size (FIGURE 1F and 1G). Three years after the first diagnosis, metastases developed in the central nervous system (FIGURE 1H), lungs, and abdominal cavity (a tumor in the umbilical region, compressing the right ureter with secondary hydronephrosis), which resulted in the patient's death.

The incidence of neuroblastoma in adults older than 20 years has been reported to be only 0.12/1 million cases.¹ To our knowledge, heart neuroblastoma in an adult, especially with a previous history of this tumor in another localization, has not yet been reported in the available international literature.

Note Echocardiography was performed at the Echocardiography Laboratory of the 1st Department of Cardiology, Poznan University of Medical Science, Poznań, Poland (Head of the Laboratory, Prof. Olga Trojnarowska, MD, PhD). Magnetic resonance imaging was performed at the MRI Laboratory at the University Hospital of Lord's Transfiguration (Head of the Laboratory, Prof. Małgorzata Pyda, MD, PhD).

REFERENCES

- 1 Esiashvili N, Goodman M, Ward K, et al. Neuroblastoma in adults: Incidence and survival analysis based on SEER data. *Pediatr Blood Cancer*. 2007; 49: 41-46.