

Gastroscope findings in a patient with signet ring cell carcinoma and late-onset hereditary hemochromatosis

Marta Walczak-Gałęzewska¹, Monika Szulińska², Danuta Pupek-Musialik¹, Paweł Bogdański²

¹ Department of Internal Medicine, Metabolic Disorders, and Hypertension, Poznan University of Medical Sciences, Poznań, Poland

² Department of Education and Treatment of Obesity and Metabolic Disorders, Poznan University of Medical Sciences, Poznań, Poland

Primary hemochromatosis is the most common inherited autosomal recessive disorder affecting northern Europeans, with a prevalence of 1:200 to 1:250. It is characterized by silent progression, and its main feature is increased intestinal iron absorption, leading to iron overload, which causes dysfunction of multiple organs, particularly the liver, pancreas, heart, joints, and skin.¹

A 70-year-old woman with a history of hypertension, hypercholesterolemia, episodes of heart palpitation, headaches, heavy depression, lack of appetite, with a loss of 8 kg of body weight over the previous 10 months, as well as arthralgia of the knee, was admitted to our hospital for a detailed diagnostic workup due to her deteriorating condition.

Clinical examination revealed the bronze skin tone and confirmed depression, without other abnormal findings. The levels of the following biochemical markers were out of range: γ -glutamyltransferase, 93 U/l (reference range <55 U/l); α -amylase, 121 U/l (25–115 U/l); iron, 34.8 μ mol/l (9.0–31.0 μ mol/l); and ferritin, 666.1 ng/ml (10.0–291.0 ng/ml). Hemoglobin and erythrocyte sedimentation rate (ESR) levels were within the reference ranges. An ambulatory laboratory test conducted 10 months before the admission revealed the γ -glutamyltransferase levels of 190 U/l; of iron, 26.1 μ mol/l; and of ferritin, 1262.4 ng/ml. No anemia or ESR abnormalities were found.

The patient underwent abdominal magnetic resonance imaging, which showed hepatic iron overload without other abnormalities. Hemochromatosis was confirmed by genetic testing for the C282Y mutation of the *HFE* gene. Gastroscope revealed submucosal pigment depositions and a small ulcer scar on the posterior wall of the stomach, with a negative test results for *Helicobacter pylori* (*H. pylori*) infection (FIGURE 1A).

The primary result of gastric biopsy sampling did not confirm any cancer or lymphoma. Due to the presence of a single ulcer scar without a known origin, negative *H. pylori* test results, no history of nonsteroidal anti-inflammatory drug (NSAID) administration, and the notable decrease of the ferritin level (no phlebotomy so far), an additional histopathological examination was performed. Finally, the biopsy sampling revealed signet ring cell carcinoma (SRCC), both in hematoxylin and eosinophil staining (FIGURE 1B) and immunohistochemistry cytokeratin A1/A3 staining (FIGURE 1C). The patient was referred to a gastrointestinal surgical oncology unit.

There is strong evidence that C282Y is associated with hepatocellular carcinoma,² but a causal relationship between *HFE* mutations and other tumors is still debated. *H. pylori* and NSAIDs are considered to be the cause of a large number of peptic ulcers (70%–90%).³ Despite a decrease in the overall incidence of gastric cancer in recent

Correspondence to:
Marta Walczak-Gałęzewska, MD, PhD,
Klinika Chorób Wewnętrznych,
Zaburzeń Metabolicznych
i Nadciśnienia Tętniczego,
Uniwersytet Medyczny
im. Karola Marcinkowskiego,
ul. Szamarzewskiego 84,
60-569 Poznań, Poland,
phone: +48 61 854 93 77,
email: walczak_marta@interia.pl
Received: January 17, 2017.
Revision accepted: February 5, 2018.
Published online:
Conflict of interests: none declared.
Pol Arch Intern Med.
doi:
Copyright by Medycyna Praktyczna,
Kraków 2018

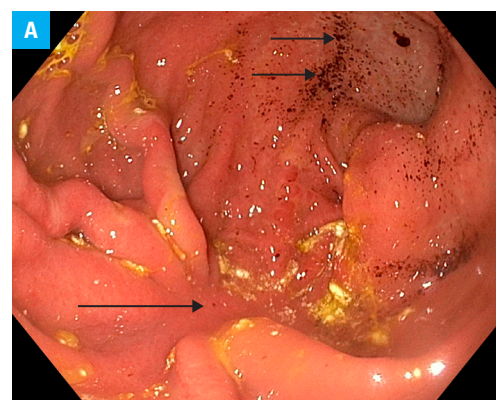
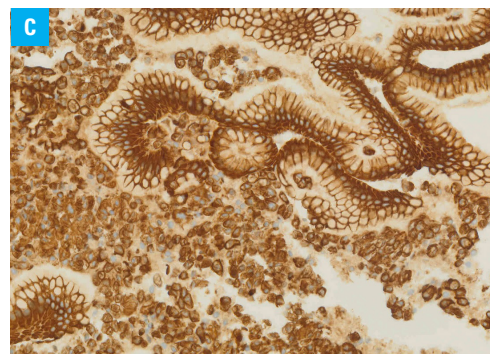
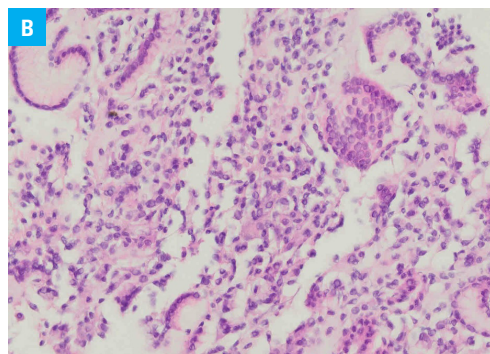


FIGURE 1 A – a gastroscope image showing the submucosal presence of pigment depositions in the stomach (short arrows) and an ulcer scar on the posterior wall (long arrow)

FIGURE 1

B – gastric biopsy sampling showing signet ring cell carcinoma; hematoxylin and eosinophil staining;
C – immunohistochemistry cytokeratin A1/A3 staining



decades, the incidence of SRCC has increased 10-fold between 1970 and 2000.⁴ SRCC is more likely to be found in women and in the distal stomach. Moreover, a higher incidence of depression was reported among patients suffering from the somatic disease compared with the general population.⁵

The aim of our paper was to present the clinical images of the late-diagnosis hereditary disease, which emphasizes the importance of testing for genetic abnormalities in elderly patients. A careful interpretation of the present and previous results of any supplementary examinations is also important. To our knowledge, this report is the first to present a rare case of 2 concomitant diseases in which iron overload induced by hemochromatosis might have masked anemia typical of gastric cancer.

ACKNOWLEDGMENTS We would like to thank Dr. Błażej Szufiak and Dr. Katarzyna Iwanik for their expertise and help in interpreting the gastroscopy imaging and biopsy sampling results.

OPEN ACCESS This is an Open Access article distributed under the terms of the Creative Commons Attribution-NonCommercial-ShareAlike 4.0 International (CC BY-NC-SA 4.0) License (<http://creativecommons.org/licenses/by-nc-sa/4.0/>), allowing third parties to copy and redistribute the material in any medium or format and to remix, transform, and build upon the material, provided the original work is properly cited, distributed under the same license, and used for noncommercial purposes only. For commercial use, please contact the journal office at pamw@mp.pl.

REFERENCES

- 1 Ogilvie C, Gaffney D, Murray H, et al. Improved detection of hereditary haemochromatosis. *J Clin Pathol*. 2015; 68: 218-221. [↗](#)
- 2 Jin F, Qu LS, Shen XZ. Association between C282Y and H63D mutations of the HFE gene with hepatocellular carcinoma in European populations: A meta-analysis. *J Exp Clin Cancer Res*. 2010; 29: 18. [↗](#)
- 3 Musumba C, Jorgensen A, Sutton L, et al. The relative contribution of NSAIDs and *Helicobacter pylori* to the aetiology of endoscopically-diagnosed peptic ulcer disease: observations from a tertiary referral hospital in the UK between 2005 and 2010. *Aliment Pharmacol Ther*. 2012; 36: 48-56. [↗](#)
- 4 Pernot S, Voron T, Perkins G, et al. Signet-ring cell carcinoma of the stomach: Impact on prognosis and specific therapeutic challenge. *World J Gastroenterol*. 2015; 21: 11428-11438.
- 5 Dudek D, Sobanski JA. Mental disorders in somatic diseases: psychopathology and treatment. *Pol Arch Med Wewn*. 2012; 122: 624-629. [↗](#)