

# Corneal complication of anticancer chemotherapeutic drug

Shinichi Kihara<sup>1</sup>, Hajime Osawa<sup>2</sup>, Shinichiro Okauchi<sup>2</sup>, Hiroaki Satoh<sup>2</sup>

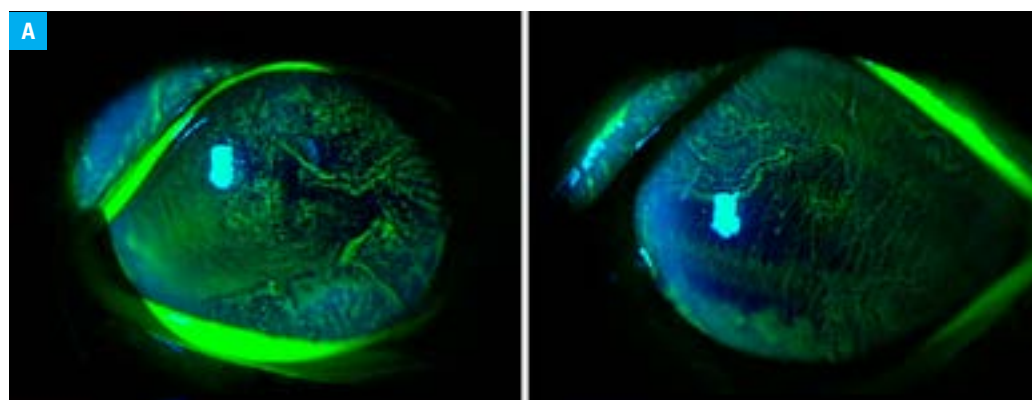
<sup>1</sup> Division of Ophthalmology, Kozawa Ganka Naika Hospital, Mito, Japan

<sup>2</sup> Division of Respiratory Medicine, Mito Medical Center, University of Tsukuba, Mito, Japan

An 84-year-old woman presented with a nodule in the left upper lobe of the lung, which was detected by mass screening. Examination of a trans-bronchial biopsy revealed the tumor to be lung adenocarcinoma; however, the epidermal growth factor receptor (EGFR) mutation could not be assessed because the specimen was too small. As the patient had a metastatic disease, she received outpatient chemotherapy using S-1, an oral fluoropyrimidine consisting of tegafur (a prodrug of fluorouracil), 5-chloro-2,4-dihydropyrimidine, and potassium oxonate.<sup>1</sup> She received 7 courses of the chemotherapy (100 mg/d for 14 consecutive days followed by a 2-week rest period), and the response was evaluated as stable disease. She was in a slowly progressive condition for 8 months since the initiation of chemotherapy and developed blurred vision. The best corrected visual acuity was 3/20 for the right eye and 6/20 for the left eye. A slit-lamp examination showed a hurricane-like irregularity of the corneal epithelium in both eyes (FIGURE 1A). Topical antibiotic, topical steroid, and artificial tears were administered, but the symptoms did not improve during the S-1 therapy. However, considering the patient's general condition, there was

no alternative treatment option at that time, so the S-1 therapy was continued. Once the evaluation of the EGFR mutation in circulating tumor DNA in plasma samples became feasible, the patient underwent the test and was found to have exon 19 deletion. As second-line therapy, she received 30 mg/d of afatinib, a second-generation EGFR-tyrosine kinase inhibitor (TKI). A follow-up chest computed tomography scan 1 month later showed reductions in the size of the primary lesion and pulmonary metastases. The patient had continued to consult the ophthalmologist, but at 4 months after the initiation of afatinib therapy, the corneal findings improved markedly (FIGURE 1B). The best corrected visual acuity improved to 6/20 for the right eye and to 10/20 for the left eye. The patient is currently in good condition, and 4 months after the initiation of afatinib, she is able to work.

Corneal injury associated with cancer chemotherapy is one of the complications that cannot be overlooked. Management by ophthalmologists is essential in this condition. Besides S-1,<sup>2</sup> corneal complications have also been reported in patients receiving first-generation EGFR-TKIs, gefitinib<sup>3</sup> or erlotinib,<sup>4</sup> although these publications were only



**FIGURE 1** Slit-lamp examination of the eyes: **A** – a hurricane-like irregularity of corneal epithelium in both eyes

## Correspondence to:

Hiroaki Satoh, MD, Division of Respiratory Medicine, Mito Medical Center, University of Tsukuba, Miyamachi 3-2-7, Mito, Ibaraki, 310-0015, Japan, phone: +81 29 231 23 71, email: hiroasato0809@yahoo.co.jp

Received: March 23, 2018.

Revision accepted: April 25, 2018.

Published online: May 16, 2018.

Conflict of interest: none declared.

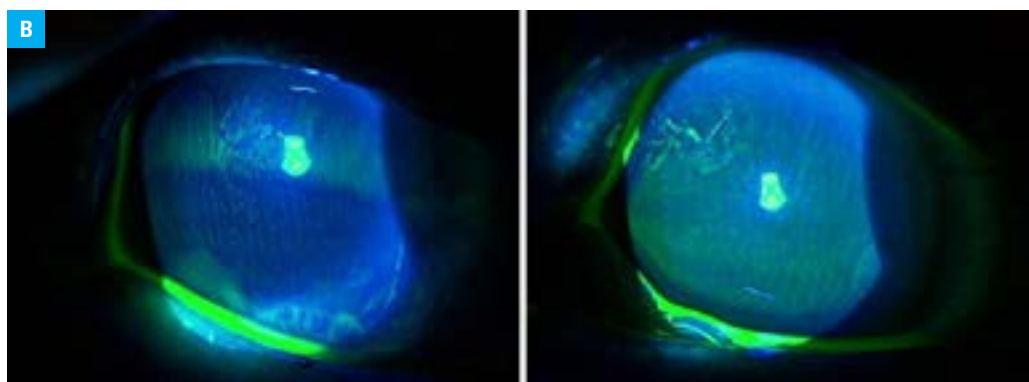
Pol Arch Intern Med. 2018;

128 (6): 392-393

doi:10.20452/pamw.4268

Copyright by Medycyna Praktyczna, Kraków 2018

**FIGURE 1** Slit-lamp examination of the eyes  
**B** – a marked improvement of corneal findings at 4 months after the initiation of afatinib therapy



case reports or case series. Afatinib, a second-generation EGFR-TKI, is widely used in patients with advanced non-small cell lung cancer and its clinical utility is now highly evaluated.<sup>5</sup> It is interesting that corneal complications due to S-1 improved after switching the drug to afatinib. However, the mechanism why the S-1-induced corneal complication improved remains unknown. This observation suggests that afatinib may be a therapeutic option for patients with the EGFR mutation who develop corneal complications during the use of S-1 therapy or first-generation EGFR-TKIs. We report a rare case with improvement of S-1-induced corneal complication by treatment change to afatinib. Corneal complication should be considered in patients complaining of blurred vision during anticancer treatment with some anticancer drugs such as S-1 or EGFR-TKIs.

**OPEN ACCESS** This is an Open Access article distributed under the terms of the Creative Commons Attribution-NonCommercial-ShareAlike 4.0 International License ([CC BY-NC-SA 4.0](https://creativecommons.org/licenses/by-nc-sa/4.0/)), allowing third parties to copy and redistribute the material in any medium or format and to remix, transform, and build upon the material, provided the original work is properly cited, distributed under the same license, and used for non-commercial purposes only. For commercial use, please contact the journal office at [pamw@mp.pl](mailto:pamw@mp.pl).

## REFERENCES

- 1 Okamoto I, Fukuoka M. S-1: a new oral fluoropyrimidine in the treatment of patients with advanced non-small-cell lung cancer. *Clin Lung Cancer*. 2009; 10: 290-294. [↗](#)
- 2 Yamada R, Sotozono C, Nakamura T, et al. Predictive factors for ocular complications caused by anticancer drug S-1. *Jpn J Ophthalmol*. 2016; 60: 63-71. [↗](#)
- 3 Höllhumer R, Moloney G, Jacob K. Corneal edema with a systemic epidermal growth factor receptor inhibitor. *Can J Ophthalmol*. 2017; 52: e96-e97.
- 4 Johnson KS, Levin F, Chu DS. Persistent corneal epithelial defect associated with erlotinib treatment. *Cornea*. 2009; 28: 706-707. [↗](#)
- 5 Hsu WH, Yang JC, Mok TS, Loong HH. Overview of current systemic management of EGFR-mutant NSCLC. *Ann Oncol*. 2018; 29 (Suppl 1): i3-i9.