

Ultrasound-assisted, catheter-directed, low-dose thrombolysis for the treatment of acute intermediate-high risk pulmonary embolism

Jakub Stepniowski¹, Grzegorz Kopeć¹, Wojciech Magoń¹, Dorota Sobczyk², Piotr Musiałek¹, Piotr Podolec¹

1 Department of Cardiac and Vascular Diseases, John Paul II Hospital, Institute of Cardiology, Jagiellonian University Medical College, Kraków, Poland

2 Emergency and Admission Department, John Paul II Hospital, Kraków, Poland

Patients at high and intermediate-high risk of early death from acute pulmonary embolism (PE) are candidates for reperfusion therapy with the use of full-dose, systemic thrombolysis.¹ However, such therapy carries a significant risk of life-threatening bleeding complications and is contraindicated in a vast number of patients.

Percutaneous therapies are increasingly common in the treatment of chronic and acute pulmonary circulation diseases.^{2,3} A novel ultrasound-assisted, catheter-directed, low-dose thrombolysis (USAT) has been indicated to facilitate pulmonary artery reperfusion, with a significantly reduced bleeding risk.^{4,5} Acoustic pulses, delivered into a thrombus by specialized intravascular catheters, unwind fibrin strands and drive the lytic drug deeper into the clot, allowing for lower-dose and high reperfusion efficacy.^{4,5}

We have recently implemented USAT to treat a patient with life-threatening acute PE, who carried an increased risk of bleeding complications. A 67-year-old man with multiple pelvic and femoral fractures developed an acute PE while awaiting reconstructive operation. Despite hemodynamic instability, systemic thrombolysis was contraindicated due to high bleeding risk. As no clinical improvement on intravenous anticoagulation was achieved, the patient was transferred to our hospital. On admission, he complained of dyspnea; his heart rate was 115 bpm; blood pressure, 95/55 mmHg; and oxygen saturation, 89%. The simplified pulmonary embolism severity index score was 3. Computed tomography pulmonary angiography (CTPA) showed centrally located bilateral thrombi, and enlargement of the right ventricle with the right ventricular-to-left ventricular (RV/LV) ratio of 1.2 (FIGURE 1A–1C). Blood levels of N-terminal-pro-B-type natriuretic peptide and troponin T were elevated.

The patient was promptly consulted by the Pulmonary Embolism Response Team (PERT) composed of a cardiac surgeon and invasive cardiologist, who recommended USAT, and the patient was transferred to a catheterization laboratory. Right heart catheterization revealed an elevated systolic pulmonary artery pressure (sPAP) of 63 mm Hg and impaired cardiac index (CI) of 1.63 l/min/m². Two USAT catheters were positioned into both pulmonary arteries via the femoral vein access under fluoroscopy guidance, and the infusion of ultrasound-assisted alteplase 1 mg/h/catheter was started (FIGURE 1D). USAT was continued at the intensive care unit for 5 hours with the total alteplase dose of 10 mg. Symptoms, clinical status, and biomarker levels gradually improved during therapy (see the legend to FIGURE 1). The sPAP decreased to 39 mm Hg and CI increased to 2 l/min/m² on USAT completion. CTPA revealed reduction of the thrombus burden and a decrease of the RV/LV ratio to 0.86 (FIGURE 1E and 1F). No adverse events occurred. On the second postprocedural day, the patient was transferred back to the orthopedic department in stable clinical condition.

This is the first report in Poland of the USAT use in a patient with acute intermediate-high risk PE, following the decision by the PERT. The report showed that this method may offer an effective therapeutic option for patients with life-threatening acute PE, minimizing the risk of bleeding complications. A prospective EKOS-PL study is underway.

OPEN ACCESS This is an Open Access article distributed under the terms of the Creative Commons Attribution-NonCommercial-ShareAlike 4.0 International License (CC BY-NC-SA 4.0), allowing third parties to copy and redistribute the material in any medium or format and to

Correspondence to:

Jakub Stepniowski, MD,
Oddział Kliniczny Chorób Serca
i Naczyń w Krakowskim Szpitalu
Specjalistycznym im. Jana Pawła II,
Uniwersytet Jagielloński, Collegium
Medicum, ul. Piłsudskiego 80,
31-202 Kraków, Poland,
phone: +48 12 614 22 87,
email: jakub.stepniowski@gmail.com

Received: April 16, 2018.

Revision accepted: May 17, 2018.

Published online: May 28, 2018.

Conflict of interests: none declared.

Pol Arch Intern Med. 2018;

128 (6): 394–395

doi:10.20452/pamw.4272

Copyright by Medycyna Praktyczna,
Kraków 2018

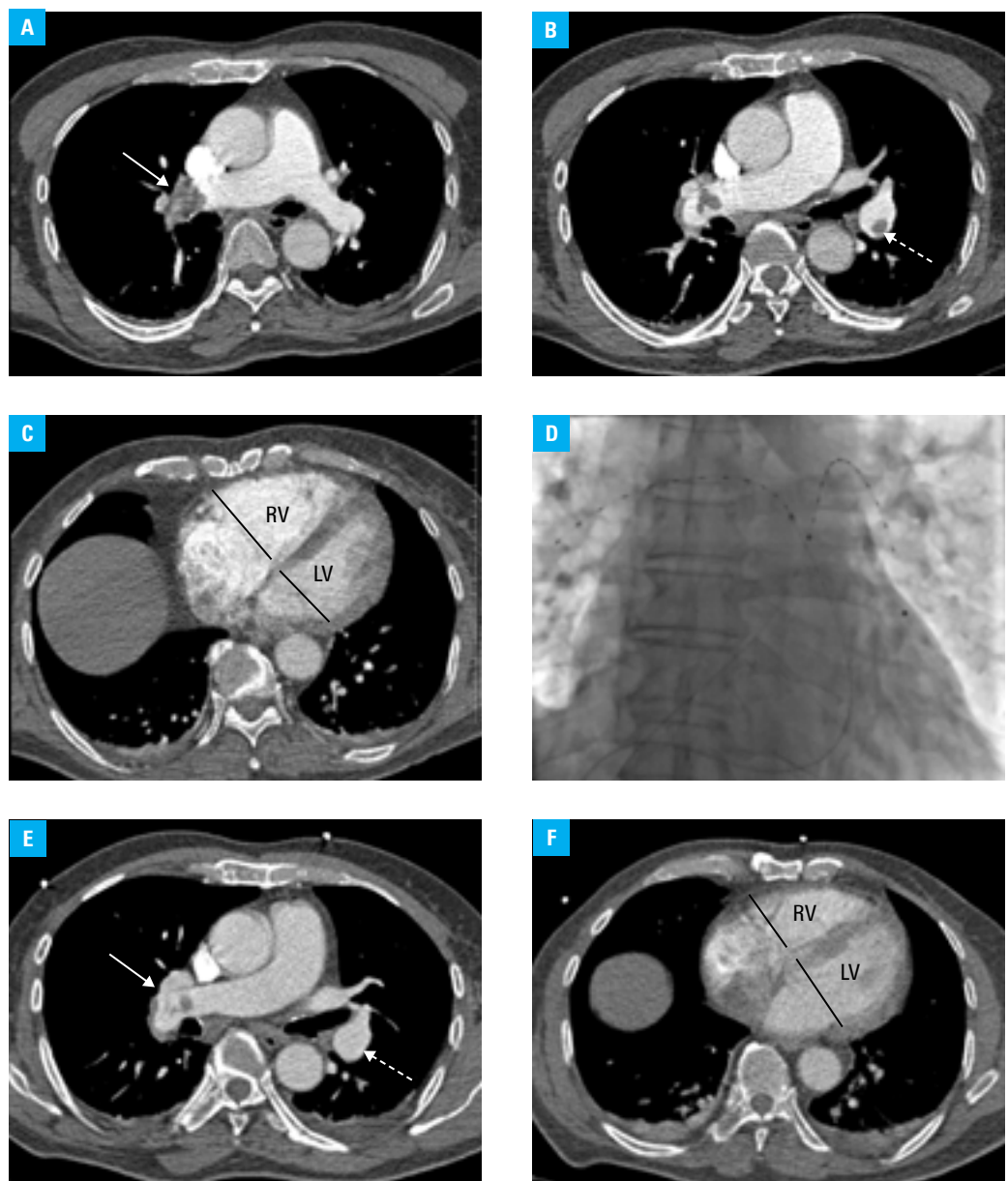


FIGURE 1 **A, B, C** – computed tomography pulmonary angiography (CTPA) showing thrombus (arrow) in the proximal right interlobar pulmonary artery (PA) (**A**) and in the middle part of the left interlobar PA (dashed arrow) (**B**), causing dilation of the right ventricle with the right ventricular-to-left ventricular (RV/LV) ratio of 1.2 (**C**); **D** – fluoroscopy showing two EkoSonic® MACH4 catheters of the EKOS™ system (Ekos Corp., Bothell, Washington, United States) for ultrasound-assisted, catheter-directed, low-dose thrombolysis (USAT), located in the right and left PAs beyond the thrombi; **E, F** – CTPA performed after 5-hour USAT with the total alteplase dose of 10 mg, showing thrombus resolution in the left PA (dashed arrow) and a reduction of thrombus burden in the right PA (arrow) (**E**), leading to a decrease in the RV/LV ratio to 0.86 (**F**). Moreover, the USAT led to a gradual relief of dyspnea, an increase of systolic blood pressure to 110 mm Hg and oxygen saturation to 95%, a decrease of heart rate to 90 bpm, and a decrease of the N-terminal-pro-B-type natriuretic peptide level from 4784 pg/ml to 3321 pg/ml and of the troponin T level from 0.115 ng/ml to 0.098 ng/ml.

remix, transform, and build upon the material, provided the original work is properly cited, distributed under the same license, and used for noncommercial purposes only. For commercial use, please contact the journal office at pamw@mp.pl.

REFERENCES

1 Konstantinides SV, Torbicki A, Agnelli G, et al. 2014 ESC guidelines on the diagnosis and management of acute pulmonary embolism. *Eur Heart J*. 2014; 35: 3033-3069, 3069a-3069k.

2 Kopeć G, Stepniowski J, Waligóra M, et al. Staged treatment of central and peripheral lesions in chronic thromboembolic pulmonary hypertension. *Pol Arch Med Wewn*. 2016; 126: 97-99. [↗](#)

3 Kopeć G, Waligóra M, Stepniowski J, et al. In vivo characterization of changes in composition of organized thrombus in patient with chronic thromboembolic pulmonary hypertension treated with balloon pulmonary angioplasty. *Int J Cardiol*. 2015; 186: 279-281. [↗](#)

4 Kucher N, Boekstegers P, Muller OJ, et al. Randomized, controlled trial of ultrasound-assisted catheter-directed thrombolysis for acute intermediate-risk pulmonary embolism. *Circulation*. 2014; 129: 479-486. [↗](#)

5 Piazza G, Hohlfelder B, Jaff MR, et al. A Prospective, Single-Arm, Multi-center Trial of Ultrasound Facilitated, Catheter-Directed, Low-Dose Fibrinolysis for Acute Massive and Submassive Pulmonary Embolism: The SEAT-TLE II Study. *JACC Cardiovasc Interv*. 2015; 8: 1382-1392. [↗](#)