

# Metalloproteinases MMP-9, MMP-2 and their tissue inhibitors TIMP-1, TIMP-2 in peripheral transbronchial lung biopsies of patients with sarcoidosis

Wojciech J. Piotrowski<sup>1</sup>, Agnieszka Nawrocka-Kunecka<sup>2</sup>, Adam Antczak<sup>1</sup>, Jerzy Marczak<sup>1</sup>, Romuald Biernacki<sup>3</sup>, Piotr Kordek<sup>4</sup>, Zofia Kurmanowska<sup>1</sup>, Paweł Górski<sup>1</sup>

<sup>1</sup> Department of Pneumology and Allergy, Medical University of Lodz, Łódź, Poland

<sup>2</sup> Department of Pathology, Medical University of Lodz, Łódź, Poland

<sup>3</sup> Department of Radiology, Medical University of Lodz, Łódź, Poland

<sup>4</sup> Department of Radiology, Hospital of Ministry of Interior and Administration, Łódź, Poland

## KEY WORDS

metalloproteinases (MMPs), sarcoidosis, tissue inhibitors of MMPs, trans-bronchial lung biopsy

## ABSTRACT

**INTRODUCTION** The imbalance between metalloproteinases (MMPs) and their tissue inhibitors (TIMPs) may be involved in the pathogenesis of lung sarcoidosis, a granulomatous inflammatory disease which may lead to lung fibrosis.

**OBJECTIVES** The aim of the study was to verify whether the expression of MMP-9, MMP-2, TIMP-1, and TIMP-2 in peripheral lung biopsies of patients with sarcoidosis correlate with lung function tests, radiological pattern, and bronchoalveolar lavage (BAL) cells. We compared the expression of MMPs and TIMPs between patients with sarcoid-positive vs. -negative biopsy and fibrosing vs. non-fibrosing high-resolution computed tomography (HRCT) pattern.

**PATIENTS AND METHODS** We examined patients with histologically proven stage II and III sarcoidosis (n = 17). Immunohistochemistry with antibodies against the studied molecules was performed in the lung and bronchial tissue specimens obtained from transbronchial lung biopsies. The radiological pattern was evaluated based on HRCT. The total cell number and percentage of cells were calculated in the BAL samples.

**RESULTS** MMPs and TIMPs were present in the cells of sarcoid granuloma, and were more prevalent in the parenchyma than in the bronchi. We found no correlation between MMP-9, MMP-2, TIMP-1, TIMP-2 and HRCT pattern or BAL cells. There were inverse associations between MMP-9 and FEV<sub>1</sub> (% predicted), and also between MMP-2 and maximal expiratory flow 25–75% (L and % predicted) in patients with sarcoidosis diagnosed by transbronchial lung biopsy. There were no differences in the measured parameters between patients with and without fibrotic changes and between those with negative vs. positive lung biopsy results.

**CONCLUSIONS** Our study provides an indirect evidence for a potential involvement of MMPs/TIMPs in the sarcoid inflammation of the distal airways.

**INTRODUCTION** Metalloproteinases (MMPs) and their tissue inhibitors play an important role in the homeostasis of the extracellular matrix (ECM). ECM components help to maintain tissue integrity, regulate cell migration, and

provide a reservoir of cytokines and growth factors. An increase in MMP activity could result in tissue destruction, possibly followed by impaired healing, but overexpression of tissue inhibitors of metalloproteinases (TIMPs) could lead

## Correspondence to:

Prof. Paweł Górski, MD, PhD,  
Klinika Pneumonologii i Alergologii,  
Uniwersytet Medyczny w Łodzi,  
ul. Kopcińskiego 22, 90-153 Łódź,  
Poland, phone: +48-42-678-75-05,  
fax: +48-42-678-21-29,  
e-mail: p\_gorski@toya.net.pl

Received: June 18, 2009.

Revision accepted: August 20, 2009.

Conflict of interest: none declared.

Pol Arch Med Wewn. 2009;

119 (10): 628-635

Copyright by Medycyna Praktyczna,  
Kraków 2009

to low physiological ECM turnover and accumulation of collagen.

Both MMP-9 (gelatinase B) and MMP-2 (gelatinase A) represent the most extensively investigated enzymes in the context of matrix remodeling. The major sources of MMP-9 in the airways are macrophages, eosinophils, neutrophils, and epithelial cells. Its main potential substrates are ECM components, especially the components of alveolar-capillary basement membrane, namely type IV collagen and entactin.<sup>1,2</sup> Disruption of the membrane may lead to an uncontrolled influx of inflammatory cells, and release of a number of degrading molecules into the alveolar space. MMP-2 is released from fibroblasts, endothelial and epithelial cells, and by the cells of macrophage lineage. It degrades type III collagen and other interstitial collagens, and thus may induce degradation of normal interstitium, followed by impaired healing.<sup>1,3-5</sup> The major source of TIMPs are also inflammatory cells, i.e., macrophages and neutrophils<sup>6,7</sup>, epithelial cells and myofibroblasts<sup>5</sup>. Inhibitors show partial substrate specificity, i.e., TIMP-1 binds to pro-MMP-9 and TIMP-2 binds to pro-MMP-2. TIMP-2 and MMP-2 are constitutively expressed, while TIMP-1 and MMP-9 can be induced by pro-inflammatory cytokines. Apart from ECM components, MMP substrates also include growth factor receptors<sup>8</sup>, integrins<sup>9</sup>, cytokines<sup>10</sup>, and cytokine receptors<sup>11</sup>. These molecules play an important regulatory role in inflammation.

It has been suggested that the imbalance between MMPs and TIMPs is one of the possible mechanisms leading to parenchymal lung fibrosis. Increased production of MMP-9 by alveolar macrophages both in idiopathic pulmonary fibrosis (IPF) and sarcoidosis patients has been reported.<sup>12,13</sup> Elevated concentrations of MMP-9 and its close correlation with a CD4/CD8 ratio was found in induced sputum of patients with sarcoidosis.<sup>14</sup> Some published data point to the imbalance between MMPs and TIMPs in the airways of asthma patients as a factor responsible for severity and unresponsiveness to drugs due to airway remodeling.<sup>15-17</sup> Serum concentrations of TIMP-1, TIMP-2, MMP-9, and other MMPs have been shown to correlate with various clinical and laboratory inflammatory markers in rheumatoid arthritis.<sup>18,19</sup>

Sarcoidosis is a granulomatous disease of unknown origin, most typically affecting hilar lymph nodes and lung parenchyma.<sup>20</sup> Although both adenopathy and parenchymal infiltrations tend to resolve spontaneously, in a small proportion of patients the progression towards irreversible lung fibrosis is observed.<sup>21,22</sup> Peripheral transbronchial lung biopsy (TBLB) is a method of choice for effective sampling of lung tissue in sarcoidosis. Its high effectiveness is related to peribronchial location of granulomas.<sup>23,24</sup> High percentage of lymphocytes, especially high CD4/CD8 ratio in bronchoalveolar lavage (BAL) fluid, increases

the likelihood of positive diagnosis and is a good predictor of disease activity.<sup>24</sup> The factors which affect the outcome and are responsible for the development of lung fibrosis are largely unknown, although the imbalance between MMPs and their inhibitors may be one of them. Therefore, we decided to investigate the expression of MMP-2, MMP-9, TIMP-1, and TIMP-2 in peripheral TBLB taken from patients suffering from lung sarcoidosis, and to search for correlations with lung function parameters, radiological findings, and BAL fluid cell counts.

**PATIENTS AND METHODS** **Patients** We selected 17 patients (6 women, 11 men, aged 41 ± 11 years) with histologically confirmed sarcoidosis from a group of patients who underwent TBLB due to disseminated lung lesions in the Department of Pneumology and Allergy. Stage II sarcoidosis was diagnosed based on chest X-rays in 15 patients and stage III in 2 patients. Only one patient had a slightly decreased diffusion capacity (grade III, carbon monoxide transfer factor/accessible lung volume 74% of normal value). All selected slides of peripheral TBLB revealed lung parenchyma, and in 14 cases (82%) also the peripheral bronchial wall. The TBLB has shown sarcoid granuloma in 8 patients (47%), lymphocytic infiltration without formation of sarcoid granuloma in 5 (29%), and the remaining biopsies revealed normal lung tissue (24%). In patients who were TBLB-negative, the diagnosis was based on bronchial mucosa and skin biopsies or surgical procedures (thoracoscopy, open lung biopsy, mediastinoscopy).

**Methods** **Bronchoscopy** Bronchoscopy was performed using standard procedures<sup>24</sup> by Pentax FB-18P bronchofiberscope, after premedication with midazolam (3–5 mg), atropine (0.5 mg) and fentanyl (1 mg). Lignocaine (2%) was used as a topical anaesthetic.

**Bronchoalveolar lavage** After the bronchoscope was inserted in one of the segmental bronchi of the medial lobe, four 50 ml portions of 0.9% NaCl were slowly instilled and subsequently withdrawn. The fluid from all portions was collected, filtered through the gauze, and centrifuged. The pellet was suspended in phosphate buffer saline, cells were calculated and diluted to 1 × 10<sup>6</sup> cells/1 ml. Cytospins were prepared and the slides were May-Grünwald-Giemsa stained. Total cell count and the percentage of macrophages, lymphocytes, neutrophils, and eosinophils were calculated.<sup>24</sup>

**Transbronchial lung biopsy** TBLB was performed as previously described.<sup>23</sup> Under fluoroscopic guidance, the scope was inserted in a segmental bronchus. The site of biopsy was chosen previously on the basis of high resolution computed tomography (HRCT). The forceps were fixed on the most distant available carina. Usually 4–5

biopsies from different sites were taken during a single bronchoscopic examination.

**Pathological examination** We examined the samples from peripheral bronchial mucosa and lung tissue obtained during the same transbronchial biopsy. Tissue material was prepared in a routine way and embedded in paraffin blocks, then cut into 4 µm thin slides. Immunohistochemistry was performed with anti-MMP-2, anti-MMP-9, anti-TIMP-1, and anti-TIMP-2 antibodies obtained from Novocastra laboratories (Newcastle, United Kingdom), following the procedures recommended by the manufacturer. The number of positive cells for each 100 cells was calculated. The cells were counted using computer analysis system (computer-camera-microscope). For statistical purposes the results were presented in 4 groups:

- 1 0–4 positive cells per 100 cells
- 2 5–9 positive cells per 100 cells
- 3 10–19 positive cells per 100 cells
- 4 ≥20 positive cells per 100 cells.

The results of the analysis of parenchymal and bronchial specimens were presented separately.

**Computed tomography scans** High-resolution, thin-section CT of the lungs was performed in each subject. Sections of 1 mm collimation

were acquired at 10 mm intervals from the apex to the dome of a diaphragm, at 120 kV, 200 mA, and a scan time of 0.6 s. All scans were obtained at full inspiration and the images were obtained at a window level of –700 Hounsfield units (HU) and a window width of 900 HU. The changes were classified as: A – nodular pattern, B – focal consolidation, C – ground-glass pattern, D – reticular pattern, E – honeycombing, F – linear shadows. The intensity of the changes in each lobe was estimated according to a five-point scale: 0 – none, 1 – <¼ of the lobar area, 2 – equal ¼ or ¼–½ of the lobar area, 3 – equal ½ or ½–¾ of the lobar area, 4 – equal or >¾ of the lobar area.

The final evaluation was shown as the letter identifying the radiological pattern and the number identifying intensity (number of the involved lobes multiplied by intensity within the lobe). Detailed characteristics are presented in the [TABLE](#). Each CT was examined by two independent experienced radiologists (PK and RB), in a double-blind fashion. The mean score for each value was calculated. The total score of C + D + E >7 indicated patients with radiological signs of fibrosis. This cut-off value was arbitrarily set up, based on the median value of this parameter (median 6.75).

**TABLE** Results of age, lung function tests, BAL cells, MMP-2, MMP-9, TIMP-1, TIMP-2, and HRCT score in groups of patients (divided according to HRCT score and TBLB result – sarcoid positive or negative)

	All patients	HRCT score >7	HRCT score <7	p	S+	S–	p
age	41 ±11	42 ±9	41 ±13	NS	40 ±11	43 ±11	NS
FEV <sub>1</sub> (% pred.)	93 ±15	85 ±16	100 ±11	NS	97 ±11	89 ±14	NS
FVC (% pred)	100 ±11	97 ±10	103 ±11	NS	100 ±5	102 ±4	NS
FEV <sub>1</sub> /FVC (%)	79 ±11	76 ±13	81 ±9	NS	85 ±4 <sup>a</sup>	73 ±4 <sup>a</sup>	0.04
MEF 25–75 (% pred.)	85 ±24	81 ±26	89 ±24	NS	99 ±25	71 ±20	NS
BAL total cells (x 10 <sup>6</sup> /ml)	21 ±4	25 ±7	17 ±4	NS	33 ±7	143 ±49	NS
BAL lymphocytes (%)	35 ±5	38 ±9	32 ±7	NS	42 ±11	29 ±5	NS
MMP-2 (lung)	1.9 ±0.3	1.5 ±0.3	2.3 ±0.4	NS	2.3 ±0.5	1.7 ±0.3	NS
MMP-9 (lung)	2.6 ±0.3	2.8 ±0.5	2.7 ±0.5	NS	3 ±0.5	2.3 ±0.4	NS
TIMP-1 (lung)	3.5 ±0.2	3.1 ±0.4	3.4 ±0.3	NS	3.5 ±0.4	3.4 ±0.2	NS
TIMP-2 (lung)	3.5 ±0.2	3.6 ±0.3	3.3 ±0.3	NS	3.5 ±0.4	3.4 ±0.2	NS
MMP-2 (bronchus)	0.5 ±0.2	0.4 ±0.2	0.6 ±0.3	NS	0.3 ±0.2	0.7 ±0.3	NS
MMP-9 (bronchus)	0.7 ±0.3	0.8 ±0.4	0.7 ±0.3	NS	0.6 ±0.4	0.8 ±0.4	NS
TIMP-1 (bronchus)	0.9 ±0.3	0.9 ±0.4	1 ±0.5	NS	0.8 ±1.2	1.1 ±0.5	NS
TIMP-2 (bronchus)	0.8 ±0.3	0.9 ±0.5	0.8 ±0.4	NS	0.8 ±0.4	1.1 ±0.5	NS
HRCT score A	5.5 ±1	6.5 ±1.3	4 ±1.6	NS	6.3 ±1.8	3.8 ±1	NS
HRCT score B	2.4 ±0.7	3.4 ±1	0.9 ±0.6	NS	2.6 ±1.3	2.2 ±0.9	NS
HRCT score C	1.8 ±0.7	2.9 ±1 <sup>a</sup>	0.3 ±0.2 <sup>a</sup>	0.02	1.9 ±1.1	1.8 ±1	NS
HRCT score D	2.5 ±0.7	3.5 ±0.9 <sup>a</sup>	1.1 ±0.6 <sup>a</sup>	0.05	2.3 ±0.9	2.6 ±1	NS
HRCT score E	0.8 ±0.5	1.4 ±0.8 <sup>a</sup>	0 ±0 <sup>a</sup>	0.03	0.2 ±0.1	1.2 ±0.8	NS
HRCT score F	0.8 ±0.5	1.4 ±0.8 <sup>a</sup>	0 ±0 <sup>a</sup>	0.03	2.3 ±1	2.5 ±1	NS

<sup>a</sup> statistically significant

Abbreviations: % pred. – % of predicted value, BAL – bronchoalveolar lavage, FVC – forced vital capacity, FEV<sub>1</sub> – forced expiratory volume in one second, HRCT – high-resolution computed tomography, MEF 25–75% – maximal expiratory flow at 25–75% of FVC, MMP – metalloproteinase, S(±) – sarcoid-positive/negative biopsy, NS – nonsignificant, TIMP – tissue inhibitor of metalloproteinase, TBLB – transbronchial lung biopsy

**Statistical analysis** Age and spirometry values were expressed as mean  $\pm$  standard deviation. The remaining data were shown as mean  $\pm$  standard error of means. The differences between subgroups were calculated with the student's t-test, if the data were normally distributed. The non-parametric Mann-Whitney test was used to evaluate differences in all other variables (TIMP-1, TIMP-2, HRCT pattern). The Spearman test was used to assess correlations between the measured parameters. A  $p \leq 0.05$  was considered statistically significant.

Similar analysis of the patients with positive and negative TBLB results (sarcoid granulomas vs. other findings) did not reveal any statistically significant differences in MMP-2, MMP-9, TIMP-1, and TIMP-2, either in the lung parenchyma or the bronchial wall, although a trend towards higher scores of parenchymal MMPs in biopsy positive samples was observed. The results are presented in the [TABLE](#) and [FIGURE 2](#) (A–D).

**A** MMP-2

Condition	Score
S-	1.0, 1.0, 1.0, 2.0, 2.0, 3.0, 3.0
S+	1.0, 1.0, 1.0, 2.0, 2.0, 3.0, 4.0, 4.0

**B** MMP-9

Condition	Score
S-	1.0, 1.0, 1.0, 1.0, 3.0, 3.0, 3.0, 3.0
S+	1.0, 1.0, 2.0, 3.0, 3.0, 3.0, 3.0, 3.0

**C** TIMP-1

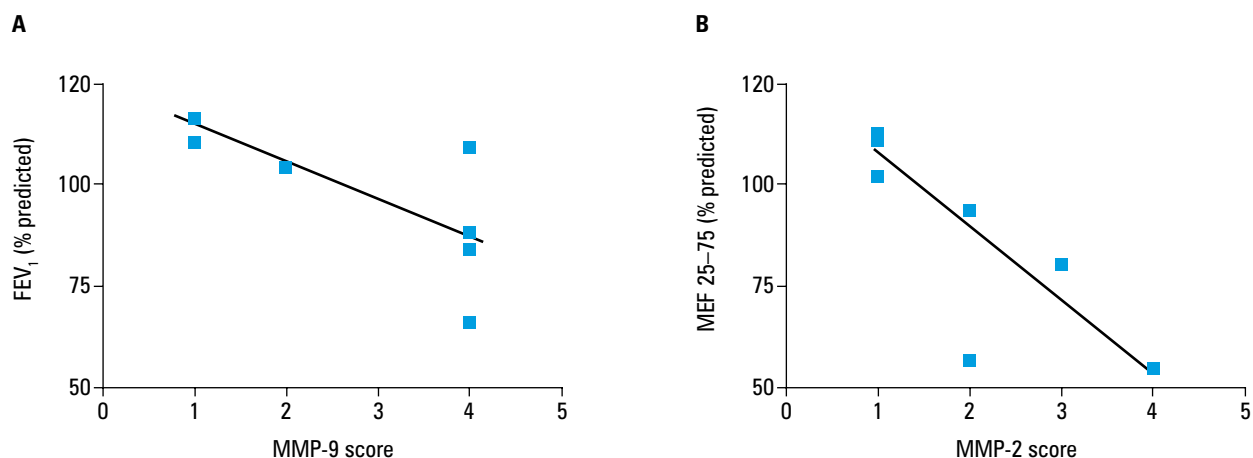
Condition	Score
S-	2.0, 3.0, 3.0, 3.0, 3.0, 3.0, 3.0
S+	1.0, 3.0, 3.0, 3.0, 3.0, 3.0, 3.0, 3.0

**D** TIMP-2

Condition	Score
S-	2.0, 3.0, 3.0, 3.0, 3.0, 3.0, 3.0
S+	1.0, 3.0, 3.0, 3.0, 3.0, 3.0, 3.0, 3.0

ORIGINAL ARTICLE Metalloproteinases MMP-9, MMP-2...





**FIGURE 3** Correlation between MMP-9 in lung tissue and FEV<sub>1</sub> (% predicted value) (panel A) and that between MMP-2 in lung tissue and MEF 25–75 (% predicted value) (panel B) in a subgroup of patients with transbronchial biopsy positive for sarcoid tissue

Abbreviations: see TABLE

bronchial wall) and lung function test parameters, DLCO, or BAL cells. HRCT pattern did not correlate with any of these molecules, both when total score and lobar score (relevant for the lobe from which the biopsy was taken) were analyzed. There was an inverse correlation between FVC (% of predicted value) and HRCT D score, typical of the reticular pattern. In patients with positive biopsy results (TBLB-proven sarcoidosis), lung MMP-9 correlated negatively with FEV<sub>1</sub> (%) ( $r = -0.80$ ,  $p = 0.03$ ; FIGURE 3A), while MMP-2 showed an inverse correlation with MEF 25–75% (L) ( $r = -0.80$ ,  $p = 0.03$ ) and MEF 25–75% ( $r = -0.90$ ,  $p = 0.01$ ; FIGURE 3B).

A positive correlation was found between parenchymal MMP-2 and MMP-9 ( $r = 0.62$ ,  $p = 0.008$ ), bronchial MMP-2 and MMP-9 ( $r = 0.89$ ,  $p < 0.0001$ ), parenchymal TIMP-1 and TIMP-2 ( $r = 0.62$ ,  $p = 0.0085$ ), bronchial TIMP-1 and TIMP-2 ( $r = 0.97$ ,  $p < 0.0001$ ). Only in the bronchial wall MMP-2 correlated with TIMP-1 ( $r = 0.95$ ,  $p < 0.0001$ ) and TIMP-2 ( $r = 0.9$ ,  $p < 0.0001$ ). Significant associations were observed between MMP-9 and both TIMP-1 ( $r = 0.98$ ,  $p < 0.0001$ ) and TIMP-2 ( $r = 0.99$ ,  $p < 0.0001$ ).

**DISCUSSION** There were no differences in the expression of MMPs and TIMPs between patients with significant parenchymal involvement and between biopsy-positive and -negative samples. We only found a positive trend towards higher MMPs scores in sarcoid-positive vs negative lung samples. Our results do not show any links between the expression of MMP-2, MMP-9, TIMP-1 and TIMP-2 at the level of distal airways and radiological pattern or BAL cells. However, in a subgroup of patients with TBLB-proven sarcoidosis MMP-9 and MMP-2 correlated negatively with FEV<sub>1</sub> and MEF 25–75%. This observation may indirectly reflect the location of granulomas with high expression of MMPs in a tissue surrounding the bronchial wall.

There is a substantial body of evidence for the role of MMP-9 and other MMPs in fibrotic lung diseases. Lemjabbar et al. have shown overexpression of MMP-9 in alveolar macrophages obtained from untreated patients suffering

from IPF, a chronic, progressive and usually fatal disease characterized by interstitial and intraalveolar massive fibrosis.<sup>12</sup> The immunohistochemical analysis of lung specimens from IPF patients has shown that MMP-9 is predominantly localized in macrophages, and that a reaction for MMP-9 was stronger in the regions with predominant inflammatory cell infiltrate than those with end-stage honeycomb areas.<sup>12</sup> Choi et al. have found higher concentrations of MMP-9 and TIMP-1 with elevated MMP-9/TIMP-1 ratio in BAL fluid of patients with cryptogenic organizing pneumonia (COP) compared with IPF patients.<sup>26</sup> Because COP is a curable disease, characterized by intraalveolar and bronchiolar intraluminal buds of granulation tissue composed of loose collagen-embedding fibroblasts and myofibroblasts but not by extensive and severe architectural remodeling like in IPF, it seems probable that changes in MMP/TIMP expression may result from the underlying active inflammation. It could also apply to the present study group, which comprised patients with active untreated stage II and III sarcoidosis, with normal lung function tests and diffusion capacity. Although there was no correlation between BAL total cell count and the percentage of BAL cells, significant associations were found between MMP-2 and MMP-9, and TIMP-1 and TIMP-2. It might be explained by the common source of all these molecules. In most patients granulations are formed peribronchially and involvement of the bronchial wall is less common, which is consistent with our finding about the lower expression of MMPs and TIMPs in the bronchial wall. On the other hand, mucosal changes, obstructive pattern in lung function tests, decreased flows at low volumes, and bronchiectases are sometimes observed in sarcoid patients. This agrees with our findings regarding correlations between FEV<sub>1</sub> and MEF 25–75% with MMPs expression in the subgroup of patients with positive biopsy results.

So far most data on protease-antiprotease imbalance were based on the BAL fluid examination.<sup>27–29</sup> Peripheral biopsy and BAL fluid represent different compartments, and the expression of MMPs and TIMPs may not be similar.

Although macrophages and other cells of macrophage lineage are the most common sources of MMPs/TIMPs, it should be emphasized that BAL and tissue macrophages are in fact different cells, with different potential regarding the production of inflammatory mediators. In addition, other cells, such as lymphocytes, eosinophils, neutrophils, and epithelial cells, should also be considered as a source. In the current study, no differences were found in MMPs/TIMPs expression, irrespective of the biopsy result (TBLB-proven sarcoidosis or TBLB sarcoid-negative). This differentiation was made in order to show a potential relation to either a presence or absence of sarcoid granuloma composed of highly differentiated mononuclear phagocytes, such as epithelioid and giant cells as well as lymphocytes.

MMP-9 is one of the most interesting molecules because it can degrade type IV collagen, the major component of the vessel wall basement membrane, promoting migration of peripheral blood monocytes from the blood to peripheral tissue. Such a possibility was shown in cardiac and pulmonary sarcoid samples.<sup>30</sup> Henry et al.<sup>28</sup> presented convincing data on the role of MMP-8 (collagenase-2) as a major contributor to the BAL collagenase activity in the airways of patients with IPF and sarcoidosis. This enzyme preferentially degrades type I collagen and can initiate degradation of collagen meshwork, leading to pulmonary fibrosis. On the other hand, Shimada et al. recently suggested that an increased TIMP-1 concentration in the lower airways plays a key role in the impaired pulmonary function in sarcoidosis patients with lung parenchymal fibrosis.<sup>29</sup> These and other data show that the balance between MMPs and their inhibitors is complex.

For ethical reasons we could not present any results of a control group comprising healthy subjects. We should bear in mind that the biopsy, although taken after HRCT examination and under fluoroscopic guidance, is in fact a random biopsy. Considering the patchy character of granulomas in sarcoidosis, there is a high risk of overlooking these areas that are affected by sarcoid lesions. Finally, we cannot present follow-up results which could allow to assess the expression of these molecules in terms of prognosis and outcome.

Despite these limitations, our results indicate possible MMP involvement in sarcoid inflammation of the distal airways, as shown by negative correlations between MMP-2/MMP-9 and FEV<sub>1</sub>/MEF 25–75% in patients with positive biopsy results.

Our final conclusions are as follows:

- 1 MMPs and TIMPs are expressed in the cells of sarcoid granuloma and in non-sarcoid tissue. These molecules are more extensively expressed in the lung parenchyma than in the bronchial wall.
- 2 MMPs may be involved in bronchial obstruction accompanying sarcoidosis. Rather than the involvement of MMPs in the bronchial wall, an increased expression of MMPs in the lung

parenchyma surrounding the bronchi should be considered as a possible mechanism.

3 Our data do not provide direct evidence for the involvement of MMPs and TIMPs in lung fibrosis, which may result from some study limitations, especially limitations of TBLB, and the lack of a control group and follow-up data on possible progression.

**Acknowledgments** The study was supported by the Medical University of Lodz, grant No. 502-11-048 (awarded to Wojciech J. Piotrowski, MD, PhD).

## REFERENCES

- 1 Stemankovic I. Extracellular matrix remodelling: the role of matrix metalloproteinases. *J Pathol.* 2003; 200: 448-464.
- 2 Garbisa S, Ballin M, Daga-Gordini D, et al. Transient expression of type IV collagenolytic metalloproteinase by human mononuclear phagocytes. *J Biol Chem.* 1986; 261: 2369-2375.
- 3 Emonard H, Takiya C, Dreze S, et al. Interstitial collagenase (MMP-1), gelatinase (MMP-2) and stromelysin (MMP-3) released by human fibroblasts cultured on acellular sarcoid granulomas (sarcoid matrix complex, SMC). *Matrix.* 1989; 9: 382-388.
- 4 Desmard M, Amara N, Lanone S, et al. Carbon monoxide reduces the expression and activity of matrix metalloproteinases 1 and 2 in alveolar epithelial cells. *Cell Mol Biol.* 2005; 30: 403-408.
- 5 Fukada Y, Ishizaki M, Kudoh S, et al. Localization of matrix metalloproteinases-1, -2 and -9 and tissue inhibitor of metalloproteinase-2 in interstitial lung disease. *Lab Invest.* 1998; 78: 687-689.
- 6 Peters CA, Freeman MR, Fernandez CH, et al. Dysregulated proteolytic balance as the basis of excess extracellular matrix in fibrotic disease. *Am J Physiol.* 1997; 732: 11-21.
- 7 Chapman HA. Disorders of lung matrix remodeling. *J Clin Invest.* 2004; 113: 148-157.
- 8 Levi E, Fridman R, Miao HQ, et al. Matrix metalloproteinase-2 releases active soluble ectodomain of fibroblast growth factor receptor 1. *Proc Natl Acad Sci USA.* 1996; 93: 7069-7074.
- 9 Fiore E, Fusco C, Romero P, et al. Matrix metalloproteinase 9 (MMP-9/gelatinase B) proteolytically cleaves ICAM-1 and participates in tumor cell resistance to natural killer cell-mediated cytotoxicity. *Oncogene.* 2002; 21: 5213-5223.
- 10 Opdenakker G, Van des Steen PE, Van Damme J. Gelatinase B: a tuner and amplifier of immune functions. *Trends Immunol.* 2001; 22: 571-579.
- 11 Sheu BC, Hsu SM, Ho HN, et al. A novel role of metalloproteinase in cancer-mediated immunosuppression. *Cancer Res.* 2001; 61: 237-242.
- 12 Lemjabbar H, Gosset P, Lechapt-Zalcman E, et al. Overexpression of alveolar macrophage gelatinase B (MMP-9) in patients with idiopathic pulmonary fibrosis. Effects of steroid and immunosuppressive treatment. *Am J Respir Cell Mol Biol.* 1999; 20: 903-913.
- 13 Agostini C, Garbisa R, Trentin L, et al. Pulmonary alveolar macrophages from patients with active sarcoidosis express type IV collagenolytic proteinase. An enzymatic mechanism for influx of mononuclear phagocytes at sites of disease activity. *J Clin Invest.* 1989; 84: 605-612.
- 14 Fireman E, Kraiem Z, Sade O, et al. Induced sputum-retrieved matrix metalloproteinase 9 and tissue metalloproteinase inhibitor 1 in granulomatous disease. *Clin Exp Immunol.* 2002; 130: 331-337.
- 15 Vignola AM, Riccobono L, Mirabella A, et al. Sputum metalloproteinase-9/tissue inhibitor of metalloproteinase-1 ratio correlates with airflow obstruction in asthma and chronic bronchitis. *Am J Respir Crit Care Med.* 1998; 158: 1945-1950.
- 16 Mattos W, Lim S, Russell R, et al. Matrix metalloproteinase-9 expression in asthma: effect of asthma severity, allergen challenge, and inhaled corticosteroid. *Chest.* 2002; 122: 1543-1552.
- 17 Bosse M, Chakir J, Rouabhi M, et al. Serum matrix metalloproteinase-9: tissue inhibitor of metalloproteinase-1 ratio correlates with steroid responsiveness in moderate to severe asthma. *Am J Respir Crit Care Med.* 1999; 159: 596-602.
- 18 Fiedorczyk M, Klimczuk PA, Sierakowski S, et al. [Serum concentration of tissue inhibitor of matrix metalloproteinases-1 (TIMP-1) correlates with markers of the disease activity in early rheumatoid arthritis]. *Pol Arch Med Wewn.* 2006; 115: 13-17. Polish.
- 19 Klimiuk PA, Sierakowski S, Chwiecko J. [Serum interleukin 6 (IL-6A) concentration correlates with matrix metalloproteinases and their tissue inhibitors in rheumatoid arthritis]. *Pol Arch Med Wewn.* 2003; 109: 119-123. Polish.
- 20 Statement on sarcoidosis. The joint statement of ATS, ERS and WASOG. *Am J Respir Crit Care Med.* 1999; 160: 736-755.

- 21 Hunninghake GW, Gilbert S, Pueringer R, et al. Outcome of the treatment of sarcoidosis. *Am J Respir Crit Care Med*. 1994; 149: 893-898.
- 22 Sones M, Israel H. Course and prognosis of sarcoidosis. *Am J Med*. 1960; 29: 84-93.
- 23 Gilman MJ, Wang KP. Transbronchial lung biopsy in sarcoidosis: an approach to determine the optimal number of biopsies. *Am Rev Respir Dis*. 1980; 122: 721-724.
- 24 British Thoracic Society guidelines on diagnostic flexible bronchoscopy. British Thoracic Society Bronchoscopy Guidelines Committee, a Subcommittee of the Standards of Care Committee of the British Thoracic Society. *Thorax*. 2001; 56 (Suppl 1): i1-i21.
- 25 Tomalak W, Antczak A, Boros P, et al. [Polish Respiratory Society Standards for Spirometry Testing]. *Pneumonol Alergol Pol*. 2006; 72 (Suppl 2): 1-32. Polish.
- 26 Choi KH, Lee HB, Jeong MY, et al. The role of matrix metalloproteinase-9 and tissue inhibitor of metalloproteinase-1 in cryptogenic organizing pneumonia. *Chest*. 2002; 121: 1478-1485.
- 27 O'Connor C, Odum C, van Breda A, et al. Collagenase and fibronectin in bronchoalveolar lavage fluid in patients with sarcoidosis. *Thorax*. 1988; 43: 393-400.
- 28 Henry MT, McMahon K, Mackarel AJ, et al. Matrix metalloproteinase and tissue inhibitor of metalloproteinase-1 in sarcoidosis and IPF. *Eur Respir J*. 2002; 20: 1220-1227.
- 29 Shimada A, Koga T, Oskita Y, et al. Reduced pulmonary function is associated with enhanced inflammation and tissue inhibitor of metalloproteinase 1 concentration in the bronchoalveolar lavage fluid of patients with lung parenchymal sarcoidosis. *Kurume Med J*. 2008; 55: 13-17.
- 30 Gonzalez AA, Segura AM, Horiba K, et al. Matrix metalloproteinases and their tissue inhibitors in the lesions of cardiac and pulmonary sarcoidosis: an immunohistochemical study. *Hum Pathol*. 2002; 33: 1158-1164.

# Metaloproteinazy MMP-9, MMP-2 i ich tkankowe inhibitory TIMP-1, TIMP-2 w obwodowych przezoskrzelowych biopsjach płuc chorych na sarkoidozę

Wojciech J. Piotrowski<sup>1</sup>, Agnieszka Nawrocka-Kunecka<sup>2</sup>, Adam Antczak<sup>1</sup>, Jerzy Marczak<sup>1</sup>, Romuald Biernacki<sup>3</sup>, Piotr Kordek<sup>4</sup>, Zofia Kurmanowska<sup>1</sup>, Paweł Górski<sup>1</sup>

<sup>1</sup> Klinika Pneumonologii i Alergologii, Uniwersytet Medyczny w Łodzi, Łódź

<sup>2</sup> Zakład Patomorfologii, Uniwersytet Medyczny w Łodzi, Łódź

<sup>3</sup> Zakład Radiologii, Uniwersytet Medyczny w Łodzi, Łódź

<sup>4</sup> Zakład Radiologii, Szpital MSWiA w Łodzi, Łódź

## SŁOWA KLUCZOWE

metaloproteinazy (MMP),  
przezoskrzelowa biopsja płuca,  
sarkoidoza, tkankowe inhibitory MMP

## STRESZCZENIE

**WPROWADZENIE** Zaburzona równowaga pomiędzy metaloproteinazami (MMP) i tkankowymi inhibitorami metaloproteinaz (TIMP) może być istotnym elementem patogenezy sarkoidozy, choroby ziarniniakowej prowadzącej u części chorych do zwłóknienia płuc.

**CELE** Celem badania była ocena, czy ekspresja MMP-9, MMP-2, TIMP-1, TIMP-2 w wycinkach płuc pobranych drogą przezoskrzelowej obwodowej biopsji koreluje z parametrami czynności płuc, obrazem radiologicznym i zmianami w składzie popłuczyn oskrzelowo-pęcherzykowych (*bronchoalveolar lavage* – BAL). Porównano ekspresję u chorych z dodatnim i ujemnym dla sarkoidozy wynikiem biopsji oraz u chorych z i bez cech włóknienia w badaniu tomografii komputerowej wysokiej rozdzielczości (TKWR).

**PACJENCI I METODY** Obwodową przezoskrzelową biopsję płuca wykonano u chorych na sarkoidozę w histologicznie udowodnionym stopniu II i III ( $n = 17$ ). Ekspresję enzymów i inhibitorów w płucu i obwodowych oskrzelach badano immunohistochemicznie z użyciem odpowiednich przeciwciał. Typ zmian radiologicznych oceniano na podstawie badania TKWR. Obliczono całkowitą liczbę komórek oraz odsetek poszczególnych ich typów w BAL.

**WYNIKI** Metaloproteinazy i ich inhibitory są obecne w komórkach ziarniny, a ekspresja jest intensywniejsza w płucu niż w oskrzelach. Nie stwierdzono korelacji pomiędzy MMP-9, MMP-2, TIMP-1, TIMP-2 a obrazem radiologicznym i zmianami w składzie komórkowym BAL. U chorych z dodatnim wynikiem biopsji stwierdzono ujemną korelację pomiędzy MMP-9 i  $FEV_1$  (% należytnej) i MMP-2 a MEF 25–75% (L i % należytnej). Nie stwierdzono różnic pomiędzy chorymi z i bez zmian włóknistych w płucach i pomiędzy chorymi z dodatnim i ujemnym wynikiem biopsji.

**WNIOSKI** Wyniki badania dostarczają pośrednich dowodów na potencjalną rolę metaloproteinaz/inhibitorów w zapaleniu obwodowych dróg oddechowych w przebiegu sarkoidozy.

Adres do korespondencji:  
prof. dr hab. med. Paweł Górski,  
Klinika Pneumonologii i Alergologii,  
Uniwersytet Medyczny w Łodzi,  
ul. Kopcińskiego 22, 90-153 Łódź,  
tel.: 042-678-75-05,  
fax: 042-678-21-29,  
e-mail: p\_gorski@toya.net.pl  
Praca wpłynęła: 18.06.2009.  
Przyjęta do druku: 20.08.2009.  
Nie zgłoszono sprzeczności  
interesów.  
Pol Arch Med Wewn. 2009;  
119 (10): 628-635  
Copyright by Medycyna Praktyczna,  
Kraków 2009