

Bilateral adrenal incidentaloma with subclinical hypercortisolemia: indications for surgery

Lucyna Papierska^{1,2}, Jarosław Ćwikła³, Michał Rabijewski⁴,
Piotr Glinicki^{1,2}, Maciej Otto⁵, Anna Kasperlik-Załuska^{1,2}

1 Department of Endocrinology, The Medical Centre of Postgraduate Education, Warsaw, Poland

2 Department of Internal Diseases, Metabolism and Endocrinology, The Bielański Hospital, Warsaw, Poland

3 Department of Radiology, University of Warmia and Mazury, Olsztyn, Poland

4 Department of Internal Diseases, Diabetology and Endocrinology, The Bródnowski Hospital, Medical University of Warsaw, Warsaw, Poland

5 Department of General, Vascular and Transplant Surgery, Medical University of Warsaw, Warsaw, Poland

KEY WORDS

adrenalectomy,
adrenal
incidentalomas,
adrenal scintigraphy,
bilateral adrenal
incidentalomas,
subclinical
hypercortisolemia

ABSTRACT

INTRODUCTION According to some authors, a higher incidence of subclinical hypercortisolemia is found among patients with bilateral benign adrenal tumors than in those with unilateral tumors. It is still unknown whether all patients with bilateral adrenal tumors and subclinical hypercortisolemia should undergo surgery, and, if so, which tumor should be removed first.

OBJECTIVES The aim of the study was to investigate whether unilateral adrenalectomy can lead to resolution of hypercortisolemia in patients with bilateral adrenal tumors and to improvement of their clinical status.

PATIENTS AND METHODS The study group consisted of 25 patients with bilateral benign adrenal tumors and subclinical hypercortisolemia. In 24 patients, unilateral adrenalectomy was performed. The adrenal gland was selected for removal on the basis of scintigraphy and/or tumor diameter. Cortisol concentrations were measured before the surgery and at 1 and 6 months after the surgery at 8:00 AM, 10:00 PM, and after dexamethasone suppression. The morning blood levels of adrenocorticotropic hormone, dehydroepiandrosterone, 17-hydroxyprogesterone, glycated hemoglobin, and lipid profile were determined.

RESULTS In all surgical patients, hypercortisolemia resolved after the surgery. However, only in 14 patients (58%), the clinical improvement was evident (improved control of diabetes and hypertension, body mass loss).

CONCLUSIONS Although subclinical hypercortisolemia resolved after surgery in all patients with bilateral adrenal tumors, only patients with poorly controlled diabetes and hypertension and a rapid increase in body mass benefited from the surgery.

INTRODUCTION Bilateral masses constitute about 15% of incidentally discovered adrenal tumors.¹⁻⁴ Several studies have emphasized the need for active surveillance in patients in whom those lesions have been detected.^{5,6} However, an overrepresentation of malignant lesions in bilateral adrenal tumors was not found in a large series of patients with bilateral lesions.^{3,4} More frequently, these tumors are adenomas or tumors that developed in the course of adrenocorticotropic hormone (ACTH)-independent macronodular adrenal hyperplasia, and, therefore, they may be a source of excessive cortisol secretion. Some authors have reported a higher incidence

of subclinical hypercortisolemia among patients with bilateral benign adrenal tumors than in those with unilateral lesions.^{1,3,7}

Subclinical hypercortisolemia without clinically evident classic symptoms of Cushing syndrome may cause arterial hypertension, glucose intolerance or diabetes, hyperlipidemia, obesity, and osteoporosis.^{8,9} Several studies have demonstrated that the removal of an adrenal tumor being the source of even slight cortisol excess decreases clinical symptoms. After a successful surgical treatment, arterial blood pressure and the morning and postprandial glycemia decrease, while insulin sensitivity increases.¹⁰⁻¹² In patients

Correspondence to:

Lucyna Papierska, MD, PhD, Klinika Endokrynologii, Centrum Medyczne Kształcenia Podyplomowego, Szpital Bielański, ul. Ceglowska 80, 01-809 Warszawa, Poland, phone: +48-22-56-90-529, fax: +48-22-834-31-31, e-mail: klinendo@cmkp.edu.pl

Received: March 30, 2014.

Revision accepted: June 16, 2014.

Published online: June 18, 2014.

Conflict of interest: none declared.

Pol Arch Med Wewn. 2014;

124 (7-8): 387-394

Copyright by Medycyna Praktyczna,

Kraków 2014

with subclinical Cushing syndrome and poorly controlled diabetes, an improvement in glycemic control was achieved following a surgical treatment.¹³ Thus, some patients benefited from adrenalectomy, even if hypercortisolemia was subclinical. However, a number of reports have questioned the benefits from surgical treatment in patients who have tumors with subclinical cortisol secretion.^{14,15}

Patients with bilateral tumors and subclinical hypercortisolemia pose a significant problem as far as the indication for surgical procedure is concerned. So far, it has not been unequivocally determined whether imaging enables to detect a tumor with excess cortisol secretion. Catheterization of the adrenal veins with the determination of adrenal veins/peripheral veins cortisol gradient is an invasive procedure with limited availability in Poland. The available reports emphasize the need to perform this examination as part of the diagnostic workup in patients with primary hyperaldosteronism; however, it has been used less frequently in patients with hypercortisolemia in bilateral adrenal tumors.¹⁶⁻¹⁹ The iodomethyl-19-norcholesterol scintigraphy is considered by some authors to be the gold standard for the assessment of incidentalomas^{1,20,21}; however, they mostly described unilateral lesions (85%–95%). In the case of bilateral lesions, a larger tumor was most often hormonally active on scintigraphy. As a general rule, it is the adrenal gland containing a larger tumor^{22,23} that is removed during unilateral adrenalectomy. In some centers, patients with bilateral adrenal tumors undergo a selective procedure—excision of the tumors only.^{24,25} However, if the lesions appeared in the course of ACTH-independent macronodular adrenal hyperplasia, regrowth and recurrence of the disease are likely. In such cases, only a bilateral adrenalectomy ensures complete cure.²⁶ However, it is a mutilating procedure, which leads to iatrogenic adrenal insufficiency. Despite the use of the lowest possible doses of hydrocortisone, substitutive therapy results in suprphysiological concentrations of cortisol²⁷ and, sometimes, also elevated concentrations of cortisol at night.²⁸ Consequently, a successful surgical treatment of endogenous subclinical hypercortisolemia may result in iatrogenic subclinical hypercortisolemia.

The above concerns regarding the treatment of subclinical hypercortisolemia in patients with bilateral adrenal tumors prompt the following question: should all patients with bilateral adrenal tumors and subclinical hypercortisolemia undergo a surgery? The present paper is a voice in the debate on this issue.

PATIENTS AND METHODS This was a prospective cohort study, which was part of a larger study of bilateral adrenal tumors. The inclusion criteria were as follows: the presence of bilateral adrenal tumors with benign phenotype and subclinical hypercortisolemia (the adopted criteria: cortisol of >3 µg/dl after administration of dexamethasone

and ACTH of <10 pg/ml). The following exclusion criteria were applied: somatic features of Cushing syndrome; suspicious tumor imaging phenotype; primary hyperaldosteronism; classic or nonclassic 21-hydroxylase deficiency; increased 24-hour urinary excretion of methoxycatecholamines; renal failure; current or previous corticosteroid therapy; and other conditions that disturb the function of the hypothalamic–pituitary–adrenal axis (depression, alcoholism, or past pituitary surgery). The study group consisted of 25 patients referred to our hospital between the years 2007 and 2010.

All patients underwent abdominal computed tomography without contrast medium. For tumors with a density exceeding 10 Hounsfield units (HU), the diagnostic workup included also the assessment of the absolute contrast wash-out coefficient on the basis of density measurements at 1 and 10 min after administration of the contrast medium. In all patients, we determined the cortisol concentration at 8:00 AM and 10:00 PM and the following morning after administration of 1 mg of dexamethasone at 11:00, the blood levels of ACTH, dehydroepiandrosterone (DHEA), glycated hemoglobin (HbA_{1c}), and lipid fractions. To exclude tumor hormonal activity other than cortisol production, we collected 24-hour urine samples for the measurement of methoxycatecholamines, assessed plasma renin activity (PRA) and plasma aldosterone concentration (PAC), calculated the PAC-to-PAR ratio, and measured 17-OH-progesterone (17-OHP) levels.

Cortisol and DHEA concentrations were measured using a chemiluminescence assay. The levels of 17-OHP and aldosterone as well as PRA were determined by the radioimmunological method, whereas the ACTH concentration by a radioimmunoassay. The HbA_{1c} concentration was measured using high-performance liquid chromatography.

During the radiolabelled norcholesterol (NP-59) scintigraphy, the radiotracer activity was determined at 72 and 144 h after administration. The examination was assessed by semi-quantitative analysis.

Unilateral laparoscopic adrenalectomy was selected as the method of surgical treatment. Hydrocortisone at a dose of 150 to 200 mg/d was administered parenterally on the day of the surgery and on days 1 and 2 after the surgery. Then, the treatment with 30 mg of oral hydrocortisone daily was administered. The dose was reduced individually according to the patient's clinical status (usually by 5 mg every 1 to 2 weeks) at ambulatory visits.

During the second month after the surgery, the concentrations of cortisol and ACTH at 8:00 AM (24 h after the last dose of hydrocortisone) and of cortisol at 10:00 PM were determined, and the same tests were repeated 6 months after the surgery. The dexamethasone suppression test with the measurement of the cortisol concentration was performed 6 months after the surgery and then after 1 year.

At each visit, the patient's clinical status, including doses of the drugs used on a long-term basis, was assessed.

The results were presented as mean values \pm standard deviation. The differences in the results before and after the surgery were assessed using the *t* test for dependent samples. A *P* value of less than 0.05 was considered statistically significant. All calculations were performed using Microsoft Excel and STATISTICA™ (StatSoft Inc.).

RESULTS The group consisted of 21 women and 4 men (mean age, 59 \pm 4 years). The mean body mass index (BMI) was 28.2 \pm 3.7 kg/m². Twenty patients (80%) were treated for arterial hypertension, 10 (40%) for diabetes, and 16 (64%) for hyperlipidemia. During the last year before the study, poor control of arterial hypertension (blood pressure of >140/90 mmHg despite using 3 to 5 antihypertensive drugs) was observed in 4 patients and diabetes in 5 (diabetes treatment was modified at least twice owing to HbA_{1c} levels exceeding 7%).

The mean morning cortisol concentration was normal (17.85 \pm 4.18 μ g/dl), while the evening concentration was 8.84 \pm 4.24 μ g/dl (elevated concentrations, i.e., >12.5 μ g/dl, were observed only in 5 patients). By definition, after dexamethasone (1 mg) suppression, cortisol concentrations were elevated by 6.0 \pm 0.56 μ g/dl. The DHEA concentration was 378.9 \pm 246.6 ng/ml and was below the normal ranges in 9 patients (36%).

Single tumors in both glands were present in 22 patients, and 2 or 3 tumors in one of the glands in 3 patients (>1 cm in diameter each). The diameters of the tumors were 3.7 cm \pm 2.8 cm on the right side and 5.8 cm \pm 2.7 cm on the left side. At least 1 tumor of more than 4 cm in diameter was detected in 17 patients (68%); such a size is an indication for surgery in Poland, independently of the patient's hormonal status. The mean density of tumors was -5.0 ± 7.5 ; all but 1 lesions (96%) were lipid-rich (<+10 HU).

Scintigraphy was performed only in 15 patients because a radiotracer was temporarily unavailable in Poland at the time of the study. A unilateral uptake with no radioisotope accumulation in the contralateral adrenal gland was observed already 72 h after the administration of the radiotracer in 4 patients in this group (27%). A predominant accumulation (>66% of the total activity) in one of the adrenal glands was detected in 9 patients (60%). Two patients (13%) had a symmetrical uptake. The larger tumor was the predominant tumor in 11 cases on scintigraphy, whereas a predominant uptake was present in the smaller tumor in 2 subjects: a tumor smaller by 1 cm became visible in 1 case and that smaller by 2.3 cm in 1 other case.

Twenty-four patients underwent surgery. Apart from subclinical hormonal activity, the tumor diameter greater than 4 cm in 16 patients, drug-resistant arterial hypertension in 4 patients, poorly controlled diabetes in 5 patients,

and quick increment of the body mass (>10 kg over 6 months) in 5 patients were additional indications for surgery. One female patient did not consent to the surgical treatment.

Unilateral laparoscopic adrenalectomy was performed in 22 patients. The choice of the operation side was based primarily on the result of scintigraphy (predominant radiotracer uptake). In cases with symmetric accumulation and in patients in whom scintigraphy was not performed, the adrenal gland with a larger tumor was removed. One woman with bilateral uptake on scintigraphy underwent a 2-stage surgery: during the first stage, the adrenal gland with the tumor larger by 1 cm was removed, but the smaller tumor was also excised after 6 months due to persistent hypercortisolemia, increase in body mass, and poor control of arterial hypertension. One man with 2 very large tumors (6 and 7 cm) underwent a 1-stage bilateral adrenalectomy.

The histopathological examination of the excised adrenal glands showed lesions typical of adrenocortical hyperplasia in 20 patients (83%) and of adenoma in 5 tumors from 4 patients (17%) (bilateral adrenocortical adenomas were diagnosed in the patient who underwent a bilateral adrenalectomy).

The patient who underwent a 1-stage bilateral adrenalectomy did not undergo a hormonal analysis after the surgery.

In the second month after the surgery, compared with the preoperative period, we observed a significant decrease in morning cortisol concentrations in all patients (8.6 \pm 2.9 vs. 17.9 \pm 4.2 μ g/dl; *P* < 0.001). Moreover, low concentrations of ACTH were maintained (5.6 \pm 2.4 pg/ml vs. 5.4 \pm 2.8 pg/ml; *P* = 0.4). Considering the above results, the hydrocortisone treatment was continued. During the second month after the surgery, hydrocortisone was withdrawn in 3 patients with cortisol concentrations above 10 μ g/dl, and over the period of 6 months after the surgery, in 17 patients. Morning cortisol concentrations after 6 months were still significantly lower than those before the surgery (11.9 \pm 2.5 μ g/dl vs. 16.5 \pm 4.2 μ g/dl; *P* = 0.001). The evening cortisol concentrations were also low (4.9 \pm 1.5 μ g/dl vs. 7.7 \pm 3.8 μ g/dl; *P* = 0.04), and the concentrations of ACTH increased and then returned to normal values (18.2 \pm 7.2 pg/ml vs. 5.1 \pm 2.3 pg/ml; *P* = 0.001). Cortisol concentrations after dexamethasone suppression were normal, i.e., <3 μ g/dl (1.97 \pm 0.9 μ g/dl).

At 6 months after the surgery, secondary hypofunction of the adrenal cortex in the remaining adrenal gland was diagnosed in 6 patients on the basis of persisting suppression of ACTH (<10 pg/ml), low concentrations of cortisol in the morning (<10 mcg/dl), low 24-hour urinary excretion of cortisol and its metabolites (<25 mcg/d and <2.5 mg/d), and clinical symptoms (muscular pains, nausea, hypotension) after hydrocortisone withdrawal. Two years after the surgery, ACTH and cortisol concentrations

TABLE Clinical status of the patients and benefits from surgery

No.	Sex/age, Y	Tumor diameter, cm	Postoperative morning cortisol levels, µg/dl ^b	Type 2 diabetes	Hypertension	Hyperlipidemia	BMI, kg/m ²	HbA _{1c} , %	Clinical changes after the surgery		
		R	L				preoperative	postoperative			
1	F, 58	3.0	7.5	5.7	+	+	23.4	22.8	5.6	5.8	no changes
2	F, 63	4.3	1.5	8.1	+		35.1	31.2	5.7	5.6	↓ BMI
3	F, 67	2.2	2.8	9	+	++	26.4	26.4	6.3	5.9	↓ doses of antidiabetic drugs
4	F, 56	3.3	1.4	8.2	+	+	22.7	21.6	5.6	5.9	no changes
5	F, 52	3.0	4.0	1.1a	++		↑ 30.8	25.2	5.9	5.8	↓ BP; ↓↓ BMI – after the second surgery
6	F, 58	4.5	1.8	4.8	++	+	27.6	24.4	5.8	5.6	↓ BP; ↓ BMI
7	F, 59	4.1	1.8	9.6	+		23.8	25.2	6.1	5.9	no changes
8	F, 59	2.4	4.4	9.1	+	+	24.1	24.1	5.5	5.5	no changes
9	F, 59	3.0	5.4	7.8	+	++	↑ 29.1	26.8	7.2	6.2	↓ BP, ↓ BMI, ↓ doses of antidiabetic drugs
10	F, 58	2.9	3.2	12	+	++	↑ 33.1	30.6	6.3	6	↓ BP, ↓ BMI, ↓ doses of antidiabetic drugs
11	F, 59	1.4	2.4	7.3	+	+	22.7	25.6	5.2	5.6	no changes
12	F, 60	4.1	3.6	4	+	+	33.8	31.2	6.4	5.8	↓ BMI, ↓ doses of antidiabetic drugs
13	F, 54	4.2	3.1								no surgery
14	F, 66	2.1	3.2	6.1	++	+	29.1	23.2	5.6	5.8	↓ BP, ↓↓ BMI, ↓ LDL-C, ↓ TG
15	M, 53	1.8	5.8	7.2	+	+	25.1	26.2	5.9	5.7	↓ BP; discontinuation of antihypertensive drugs
16	M, 62	6.0	7.0	<1 ^b	+	+	30.9	26.2	5.6	5.8	↓↓ BMI, ↓ LDL-C, ↓ TG
17	F, 65	5.0	2.5	8.8	++		26.2	24.6	5.8	5.4	↓ RR
18	F, 62	2.5	3.7	7.7	+	++	↑ 32.6	26.7	6.7	6.2	discontinuation of insulin, ↓↓ BMI, ↓ TG
19	F, 55	3.7	1.3	8.8	+	+	↑ 31.2	24.6	5.7	5.5	↓↓ BMI, ↓ LDL-C, ↓ TG
20	M, 54	6.1	1.5	5.2	+	+	29.4	31.1	5.6	5.8	no changes
21	F, 50	4.5	4.1	14.2	+	+	33.2	32.2	5.8	6	no changes
22	M, 58	6.0	4.5	10	+	+	27.6	25.6	6.1	5.9	no changes
23	F, 61	2.9	4.8	9.8	+	+	30.0	24.2	6.2	6.1	↓↓ BMI, ↓ doses of antidiabetic drugs, ↓ TG
24	F, 58	2.0	3.9	10			27.2	26.2	5.3	5.5	no changes
25	F, 68	7.0	4.0	5.6	+		26.0	28.2	6.1	5.9	no changes

a after the second surgery, b bilateral adrenalectomy+ + + – worsening of control, + + – present, well-controlled, ↓ – decrease, ↓↓ – decrease of BMI > 5 kg/m², ↑ – increase in body mass, > 10 kg/6 monthsAbbreviations: BMI – body mass index, BP – blood pressure, F – female, HbA_{1c} – hemoglobin A_{1c}, L – left, LDL-C – low-density lipoprotein cholesterol, M – male, R – right, TG – triglycerides

returned to normal values in 2 patients and the other 4 continued hydrocortisone treatment.

Despite the effectiveness of surgical treatment confirmed by the lack of hypercortisolemia, a significant improvement in the clinical status was not observed in all patients. Normalization of blood pressure that allowed to reduce the doses of antihypertensive drugs was achieved in 3 of 4 patients with poorly controlled arterial hypertension (from 3–5 to 1–2 antihypertensive drugs, achieving blood pressure of <140/90 mmHg). It was possible to withdraw the drugs completely in 1 patient with newly diagnosed arterial hypertension and to reduce the doses of oral drugs and insulin in 5 patients with diabetes (of whom 4 had poorly controlled diabetes) and of insulin in 1 person. In 5 patients, we observed an improvement in the lipid profile, namely, a permanent decrease in low-density lipoprotein cholesterol or triglyceride levels (or both) that allowed to reduce the doses of hypolipemic drugs. The concentrations of lipid fractions were not included in the quantitative analysis because patients received statins or fibrates before and after surgery from primary health care physicians. The improvement expressed as a reduction in the dose or number of used drugs was observed in 14 patients (58%). Surprisingly, postoperative improvement was not so notable in patients with cortisol levels exceeding 5 µg/dl after dexamethasone suppression, i.e., above the oldest cut-off value for the diagnosis of hypercortisolemia (46% vs. 73%), or in patients with a tumor size exceeding 4 cm in diameter, which is an independent indication for surgery (50% vs. 63%). The results for individual patients are presented in the [TABLE](#).

We did not observe a significant decrease in the concentration of HbA_{1c} in the whole study group. However, the concentration decreased significantly in 10 patients with type 2 diabetes compared with those without diabetes ([FIGURE 1](#)).

Six months after the surgery, the patient's body mass decreased by a mean of 3.9 ± 5.8 kg, which resulted in a decrease of the mean BMI in the whole group from 28.2 ± 3.7 kg/m² to 26.4 ± 2.9 kg/m² ($P = 0.003$). The body mass decreased by 7 to 15 kg (mean, 11.6 ± 3.6 kg) in 5 women who reported an increase in body mass exceeding 10 kg over 6 months before the surgery. The BMI decreased in the subgroup of 9 patients with obesity, whereas it did not decrease significantly in patients with normal body mass or in overweight patients ([FIGURE 2](#)). The BMI also decreased significantly in the subgroup of 10 diabetic patients, whereas no significant changes in the BMI were observed in the subgroup without diabetes after the surgery ([FIGURE 3](#)).

DISCUSSION The concentrations of ACTH and cortisol after the dexamethasone suppression test returned to normal in 22 of 23 patients who underwent unilateral adrenalectomy. However, the normalization of hormone levels was not always associated with a good clinical outcome of

the surgery. The improvement in the health status was pronounced only in patients who had the following additional indications for surgery: poor control of blood pressure, poor control of glycemia, or quick uncontrolled increase in body mass. A clinical improvement was achieved in 14 patients (58%), which is in line with the results of other authors who reported an improvement in the lipid profile and decrease in body mass, glycemia, and arterial pressure following a successful surgery in 20% to 67% of the patients.^{10–12} Iacobone et al.²² described better effects of the surgical removal of bilateral tumors: it allowed to reduce the doses or withdraw antihypertensive and hypoglycemic drugs in all operated patients.²² However, the study group consisted only of 7 individuals, of whom 6 had high arterial pressure despite the treatment, and 5 had poorly controlled diabetes; thus, as in our study, patients with pronounced clinical symptoms of hypercortisolemia benefited from the surgery. Giordano et al.,¹⁵ in a study of 128 patients with incidentalomas (including 14% with bilateral ones), did not report any differences in the incidence of diabetes, obesity, and hypertension between patients with and without subclinical hypercortisolemia. None of the patients showed clinical improvement after the surgery. Gordiano et al.¹⁵ showed that concomitant diseases in patients with hypercortisolemia are not related to excess cortisol levels. Moreover, a recent experiment in rats demonstrated that the adrenal gland volume and cortisol levels are increased in fructose-induced type 2 diabetes.²⁹ In 1996, Reincke et al.³⁰ postulated that insulin resistance and diabetes may be the cause and not the result of bilateral adrenal lesions.³⁰ A poor control of diabetes or hypertension and a rapid increase in body mass can result from subclinical hormonal activity. The presence of such symptoms may be considered as the onset of a transition from subclinical hypercortisolemia to overt hypercortisolemia, but, on the other hand, some of our patients underwent surgery more than 6 months after the initial diagnosis and had no symptoms characteristic of Cushing syndrome. Moreover, deterioration in the clinical status and transition from subclinical hypercortisolemia to symptomatic Cushing syndrome was not observed in studies with long-term follow-up.^{15,31,32} Two other studies demonstrated clinical deterioration in patients with subclinical hypercortisolemia,^{10,11} although the negative changes involved mainly poor control of arterial pressure and diabetes, without transition to overt Cushing syndrome.

Considering the above, the decision to refer a patient with bilateral adrenal tumors for surgery has to be based first of all on the patient's clinical status rather than solely on the results of hormonal testing confirming subclinical hypercortisolemia. If no diabetes is present or if it is well controlled, if arterial pressure is well controlled with drugs, and no rapid increase in body mass occurs, a possible alternative to surgery might be

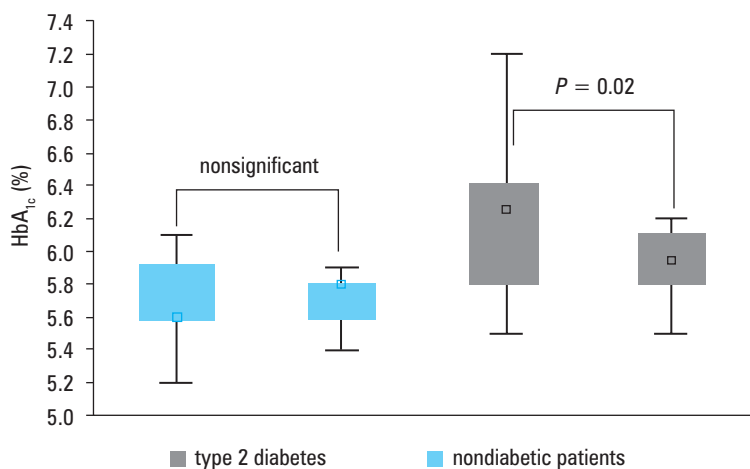


FIGURE 1 Changes in glycated hemoglobin (HbA_{1c}) levels in patients with type 2 diabetes compared with nondiabetic subjects

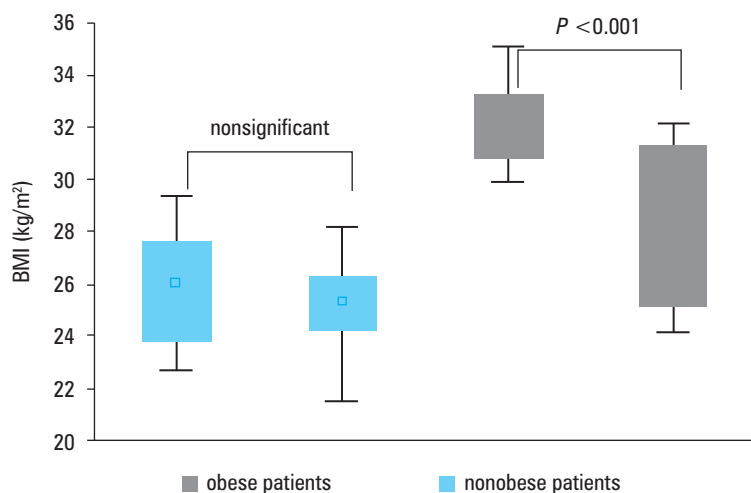


FIGURE 2 Changes in body mass index (BMI) in obese and nonobese patients

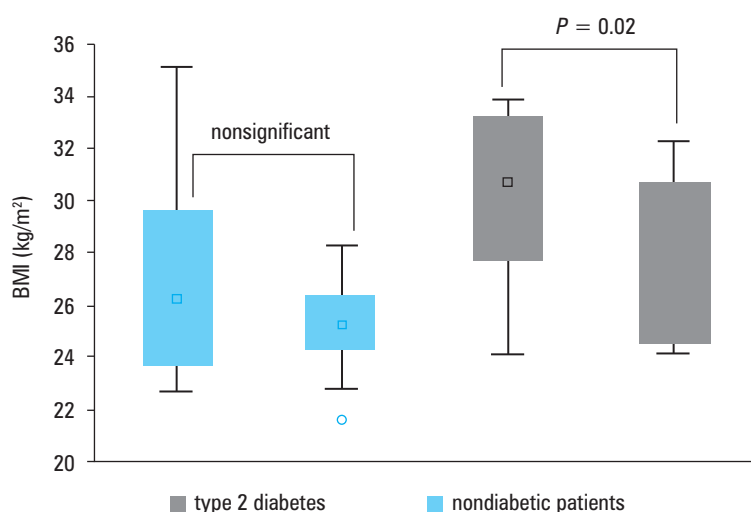


FIGURE 3 Changes in body mass index (BMI) in patients with type 2 diabetes and nondiabetic patients

pharmacological treatment and close monitoring of the patients. This is in line with a review by Terzolo et al.³³ in which they suggested that patients between 50 and 70 years of age should undergo a surgery only if concomitant diseases are poorly controlled and recommended monitoring only of patients over 70 years of age. This may be compared to primary hyperaldosteronism, which is not an indication for surgery itself because, in many cases, the treatment with mineralocorticoid receptors blockers is sufficient for blood pressure control, while operated patients do not achieve improvement.³⁴

In conclusion, although unilateral adrenalectomy allows to cure subclinical hypercortisolemia in patients with bilateral adrenal tumors, the improvement in the hormonal status does not lead to clinical improvement in all patients. Only patients with poor control of diabetes or hypertension and a rapid increase in body mass before surgery may benefit from surgical treatment.

REFERENCES

- Barzon L, Scaroni C, Sonino N, et al. Incidentally discovered adrenal tumors: endocrine and scintigraphic correlates. *J Clin Endocrinol Metab.* 1998; 83: 55-62.
- Morelli V, Palmieri S, Salcuni AS, et al. Bilateral and unilateral adrenal incidentalomas: biochemical and clinical characteristics. *Eur J Endocrinol.* 2013; 168: 235-241.
- Olsen H, Nordenström E, Bergenfelz A, et al. Subclinical hypercortisolism and CT appearance in adrenal incidentalomas: a multicenter study from Southern Sweden. *Endocrine.* 2012; 42: 164-173.
- Kasperlik-Zaluska AA, Słowińska-Szednicka J, Rosłonowska E, et al. Bilateral, incidentally found adrenal tumors—results of observation of 1790 patients registered at a single endocrinological centre. *Endokrynol Pol.* 2010; 61: 69-73.
- Young WF Jr. The incidentally discovered adrenal mass. *N Engl J Med.* 2007; 356: 601-610.
- Angeli G, Osella, Ali A, Terzolo M. Adrenal incidentaloma: an overview of clinical and epidemiological data from the National Italian Study Group. *Horm Res.* 1997; 47: 279-283.
- Vassiliadi DA, Ntali G, Vicha E, Tsagarakis S. High prevalence of subclinical hypercortisolism in patients with bilateral adrenal incidentalomas: a challenge to management. *Clin Endocrinol.* 2011; 74: 438-444.
- Terzolo M, Pia A, Ali A, et al. Adrenal incidentaloma: a new cause of the metabolic syndrome? *J Clin Endocrinol Metab.* 2002; 87: 998-1003.
- Rossi R, Tauchmanova L, Luciano A, et al. Subclinical Cushing's syndrome in patients with adrenal incidentaloma: clinical and biochemical features. *J Clin Endocrinol Metab.* 2000; 85: 1440-1448.
- Eller-Vainicher C, Morelli V, Salcuni AS, et al. Accuracy of several parameters of hypothalamic-pituitary-adrenal axis activity in predicting before surgery the metabolic effects of the removal of an adrenal incidentaloma. *Eur J Endocrinol.* 2010; 163: 925-935.
- Toniato A, Merante-Boschin I, Opocher G, et al. Surgical versus conservative management for subclinical Cushing syndrome in adrenal incidentalomas: a prospective randomized study. *Ann Surg.* 2009; 249: 388-391.
- Chiodini I, Morelli V, Salcuni AS, et al. Beneficial metabolic effects of prompt surgical treatment in patients with an adrenal incidentaloma causing biochemical hypercortisolism. *J Clin Endocrinol Metab.* 2010; 95: 2736-2745.
- Catargi B, Rigalleau V, Poussin A, et al. Occult Cushing's syndrome in type-2 diabetes. *J Clin Endocrinol Metab.* 2003; 88: 5808-5813.
- Erbil Y, Ademoglu E, Ozbey N, et al. Evaluation of the cardiovascular risk in patients with subclinical Cushing syndrome before and after surgery. *World J Surg.* 2006; 30: 1665-1671.
- Giordano R, Marinazzo E, Berardelli R, et al. Long-term morphological, hormonal, and clinical follow-up in a single unit on 118 patients with adrenal incidentalomas. *Eur J Endocrinol.* 2010; 162: 779-785.
- Young WF Jr, du Plessis H, Thompson GB, et al. The clinical conundrum of corticotropin-independent autonomous cortisol secretion in patients with bilateral adrenal masses. *World J Surg.* 2008; 32: 856-862.
- Bookstein JJ. The roles of angiography in adrenal disease. In: *Abram's angiography.* 3rd ed. Boston, Massachusetts: Little, Brown; 1983: 1395-1424.

- 18 Iacobone M, Favia G. Role of selective venous adrenal sampling in ACTH independent macronodular adrenal hyperplasia (AIMAH). *World J Surg.* 2009; 33: 159.
- 19 Maghrabi A, Yaqub A, Denning KL, et al. Challenges in the diagnostic work-up and management of patients with SCS and bilateral adrenal masses. *Endocr Pract.* 2013; 20: 1-22.
- 20 Barzon L, Fallo F, Sonino N, Boscaro M. Overnight dexametasone suppression of cortisol is associated with radiocholesterol uptake patterns in adrenal incidentalomas. *Eur J Endocrinol.* 2001; 145: 223-224.
- 21 Yoh T, Hosono M, Komeya Y, et al. Quantitative evaluation of norcholesterol scintigraphy, CT attenuation value, and chemical-shift MR imaging for characterizing adrenal adenomas. *Ann Nucl Med.* 2008; 22: 513-519.
- 22 Iacobone M, Albiger N, Scaroni C, et al. The Role of Unilateral Adrenalectomy in ACTH Independent Macronodular Adrenal Hyperplasia (AIMAH). *World J Surg.* 2008; 32: 882-889.
- 23 Lamas C, Alfaro JJ, Lucas T, et al. Is unilateral adrenalectomy an alternative treatment for ACTH-independent macronodular adrenal hyperplasia? Long-term follow-up of four cases. *Eur J Endocrinol.* 2002; 146: 237-240.
- 24 Iihara M, Suzuki R, Kawamata A, et al. Adrenal-preserving laparoscopic surgery in selected patients with bilateral adrenal tumors. *Surgery.* 2003; 134: 1066-1072.
- 25 Kawasaki Y, Ishidoya S, Kaiho Y, et al. Laparoscopic simultaneous bilateral adrenalectomy: assessment of feasibility and potential indications. *Int J Urol.* 2011; 18: 762-767.
- 26 Stratakis CA, Kirschner LS. Clinical and genetic analysis of primary bilateral adrenal diseases (micro- and macronodular disease) leading to Cushing's syndrome. *Horm Metab Res.* 1998; 30: 456-463.
- 27 Thomson AH, Devers MC, Wallace AM, et al. Variability in hydrocortisone plasma and saliva pharmacokinetics following intravenous and oral administration to patients with adrenal insufficiency. *Clin Endocrinol.* 2007; 66: 789-796.
- 28 Betterle C, Morlin L. Autoimmune Addison's disease. *Endocr Rev.* 2011; 20: 161-172.
- 29 Elahi-Moghaddam Z, Behnam-Rassouli M, Mahdavi-Shahri N, et al. Comparative study on the effects of type 1 and type 2 diabetes on structural changes and hormonal output of the adrenal cortex in male Wistar rats. *J Diabetes Metab Disord.* 2013; 12: 1-6.
- 30 Reincke M, Fassnacht M, Väh S, et al. Adrenal incidentalomas: a manifestation of the metabolic syndrome? *Endocr Res.* 1996; 22: 757-761.
- 31 Vassilatou E, Vryonidou A, Michalopoulou S, et al. Hormonal activity of adrenal incidentalomas: results from a long-term follow-up study. *Clin Endocrinol.* 2009; 70: 674-679.
- 32 Bernini GP, Moretti A, Oriandini C, et al. Long-term morphological and hormonal follow-up in a single unit on 115 patients with adrenal incidentalomas *Br J Cancer.* 2005; 92: 1104-1109.
- 33 Terzolo M, Pia A, Reimondo G. Subclinical Cushing's syndrome: definition and management. *Clin Endocrinol (Oxf).* 2012; 76: 12-18.
- 34 Hyla-Klekot L, Kokot F. Primary aldosteronism: a new insight into pathogenesis, diagnosis, and treatment in hypertensive patients. *Pol Arch Med Wewn.* 2013; 123: 547-551.

Obustronne guzy nadnerczy z subkliniczną hiperkortyzolemią – wskazania do leczenia operacyjnego

Lucyna Papierska^{1,2}, Jarosław Ćwikła³, Michał Rabijewski⁴,
Piotr Glinicki^{1,2}, Maciej Otto⁵, Anna Kasperlik-Załuska^{1,2}

1 Klinika Endokrynologii, Centrum Medyczne Kształcenia Podyplomowego, Warszawa

2 I Oddział Chorób Wewnętrznych, Diabetologii i Endokrynologii, Szpital Bielański, Warszawa

3 Katedra Radiologii, Uniwersytet Warmińsko-Mazurski, Olsztyn

4 Klinika Chorób Wewnętrznych, Diabetologii i Endokrynologii, Mazowiecki Szpital Bródnowski, Warszawski Uniwersytet Medyczny, Warszawa

5 Klinika Chirurgii Ogólnej, Transplantacyjnej i Naczyniowej, Warszawski Uniwersytet Medyczny, Warszawa

SŁOWA KLUCZOWE

adrenalectomia,
obustronne guzy
nadnerczy,
przypadkowo wykryte
guzy nadnerczy,
scyntygrafia
nadnerczy,
subkliniczna
hiperkortyzolemia

STRESZCZENIE

WPROWADZENIE Subkliniczną hiperkortyzolemię, według niektórych autorów, częściej stwierdza się u chorych z obustronnymi niż jednostronnymi łagodnymi guzami nadnerczy. Wciąż nie wiadomo czy każdy pacjent z obustronnymi guzami nadnerczy i subkliniczną hiperkortyzolemią powinien być leczony operacyjnie, a, jeżeli tak, który z guzów powinien być usuwany w pierwszej kolejności.

CELE Celem badania była odpowiedź na pytanie czy jednostronna adrenalectomia może doprowadzić do ustąpienia subklinicznej hiperkortyzolemii u chorych z obustronnymi guzami nadnerczy, i czy spowoduje to poprawę stanu klinicznego chorych.

PACJENCI I METODY Grupa badana składała się z 25 pacjentów z łagodnymi obustronnymi guzami nadnerczy i subkliniczną hiperkortyzolemią. U 24 chorych wykonano jednostronną adrenalectomię. Nadnercze do usunięcia wybierano w oparciu o wynik badania scyntygraficznego i/lub średnicę guza. Przed zabiegiem oraz miesiąc i 6 miesięcy po operacji oceniano stężenie kortyzolu o 8.00 i 22.00 oraz po hamowaniu deksametazonem. Oceniano także poranne stężenie kortykotropiny, dehydroepiandrosteronu, 17-hydroksyprogesteronu, hemoglobiny glikowanej i lipidogram.

WYNIKI U wszystkich operowanych chorych hiperkortyzolemia ustąpiła po zabiegu. Jednak jedynie u 14 (58%) z nich nastąpiła ewidentna poprawa stanu klinicznego (poprawa kontroli cukrzycy i nadciśnienia tętniczego, utrata masy ciała).

WNIOSKI Chociaż leczenie chirurgiczne spowodowało ustąpienie hiperkortyzolemii u wszystkich operowanych pacjentów, jedynie chorzy ze złą kontrolą cukrzycy, nadciśnienia oraz szybkim przyrostem masy ciała odnieśli z niego korzyść.

Adres do korespondencji:

dr med. Lucyna Papierska, Klinika
Endokrynologii, Centrum Medyczne
Kształcenia Podyplomowego, Szpital
Bielański, ul. Ceglowska 80, 01-809
Warszawa, tel.: 22-56-90-529,
fax: 22-834-31-31, e-mail:
klinendo@cmkp.edu.pl

Praca wpłynęła: 30.03.2014.

Przyjęta do druku: 16.06.2014.

Publikacja online: 18.06.2014.

Nie zgłoszono sprzeczności
interesów.

Pol Arch Med Wewn. 2014;

124 (7-8): 387-394

Copyright by Medycyna Praktyczna.

Kraków 2014