

# Sarcoidosis with bone marrow involvement

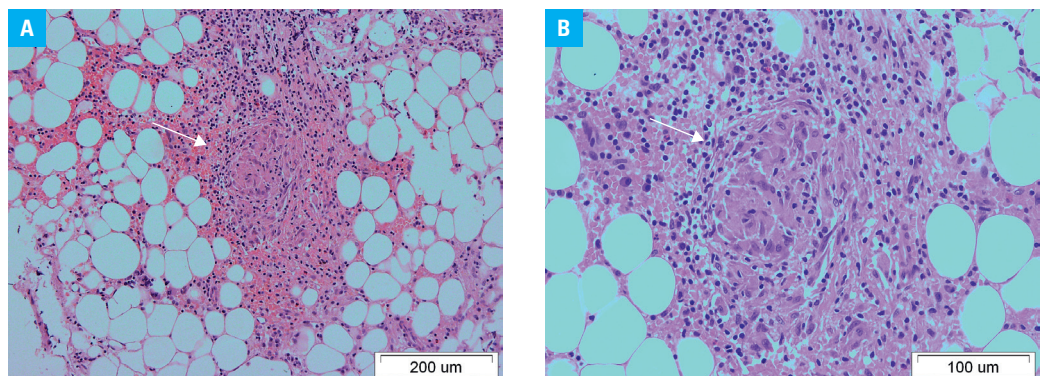
Grzegorz Helbig<sup>1</sup>, Karolina Torba<sup>1</sup>, Jacek Pająk<sup>2</sup>, Sławomira Kyrz-Krzemień<sup>1</sup>

<sup>1</sup> Department of Hematology and Bone Marrow Transplantation, Medical University of Silesia, Katowice, Poland

<sup>2</sup> Department of Pathology, Medical University of Silesia, Katowice, Poland

A 46-year-old man was diagnosed with stage I sarcoidosis in 2010, but he did not agree to further follow-up visits and investigations. He remained free of any disease symptoms until 2014 when progressive weakness and dyspnea occurred. Chest X-ray and high-resolution computed tomography scans showed bilateral hilar adenopathy and numerous subpleural reticular opacities—the manifestations consistent with stage II sarcoidosis. Surprisingly, the complete blood count (CBC) test revealed pancytopenia with a neutrophil count of  $1.1 \times 10^9/l$ , hemoglobin concentration of 10.5 g/dl, and platelet count of  $3 \times 10^9/l$ . The patient was transfused with platelet concentrates and then referred to the Hematology Unit. On admission, his overall condition was good and an abdominal ultrasound showed hepatomegaly (anteroposterior [AP], 16 cm) and massive splenomegaly (AP, 20 cm). No other abnormalities were detected. He remained pancytopenic on the CBC test, but differential leucocyte counts were normal. Biochemical test results were within normal ranges except for the serum  $\beta_2$  microglobulin concentration, which was markedly elevated to 8.27 mg/l (normal range, 1.5–3.0 mg/l). Protein levels, including immunoglobulin (Ig) G, IgA, and IgM concentrations, as well as electrophoresis were normal. Hemolysis and viral infections (human immunodeficiency

virus, hepatitis B virus, hepatitis C virus, cytomegalovirus, and Epstein–Barr virus) were excluded. Blood and urine cultures were negative. Tuberculosis was excluded. Serum iron and folic acid levels were normal, while a moderate vitamin B<sub>12</sub> deficiency was detected (101 pg/ml; normal range, 157–1057 pg/ml). A small proportion of erythroblasts had dysplastic features on bone marrow (BM) aspiration, which might be consistent with vitamin B<sub>12</sub> deficiency; however, an early phase of myelodysplastic syndrome was also considered. Thus, a trephine biopsy was performed. Considering the results of the BM biopsy, the patient received vitamin B<sub>12</sub> injections at a dose of 0.1 mg daily intramuscularly, then once a week for a total of 2 months, but pancytopenia persisted. The biopsy did not reveal any potential causes of pancytopenia, and no dysplastic features were demonstrated. Nevertheless, an oval sarcoidal granuloma consisting of epithelioid histiocytes and multinucleate giant cells was observed in the hematoxylin and eosin stain of the biopsy. The granuloma was sparsely surrounded by a rim of lymphocytes. Necrosis was not observed (FIGURE 1). Finally, the patient was diagnosed with disseminated sarcoidosis and hypersplenism, which seemed to be the most likely cause of pancytopenia.



**FIGURE 1** Noncaseating granuloma (arrow) in the bone marrow biopsy; **A** – hematoxylin and eosin stain,  $\times 100$ ; **B** – hematoxylin and eosin stain,  $\times 200$

Correspondence to:  
Grzegorz Helbig, MD, PhD, Katedra  
i Klinika Hematologii i Transplantacji  
Szpiku, Śląski Uniwersytet  
Medyczny, ul. Dąbrowskiego 25,  
40-032 Katowice, Poland,  
phone: +48-32-259-13-10,  
fax: +48-32-255-49-85,  
e-mail: ghelbig@o2.pl  
Received: May 26, 2014.  
Revision accepted: June 3, 2014.  
Published online: June 13, 2014.  
Conflict of interest: none declared.  
Pol Arch Med Wewn. 2014;  
124 (7-8): 427-428  
Copyright by Medycyna Praktyczna,  
Kraków 2014

BM granulomas are a rare finding and they may be associated with various disorders including infections, malignancies, and sarcoidosis. There is also a small proportion of therapy-related granulomas. Granulomatous lesions in the BM had an incidence of 0.6% in a recently published series based on 9641 bone marrow biopsies, and 21% of those granulomas were related to sarcoidosis.<sup>1</sup> Of note, BM noncaseating granulomas related to sarcoidosis are potentially underdiagnosed and are often an incidental finding, especially in patients without hematological abnormalities.<sup>2,3</sup> Recently, a role of positron emission tomography imaging in the assessment of BM involvement in patients with sarcoidosis has been suggested.<sup>4</sup>

## REFERENCES

- 1 Brackers de Hugo L, French M, Broussolle C, Sève P. Granulomatous lesions in bone marrow: clinicopathologic findings and significance in a study of 48 cases. *Eur J Intern Med.* 2013; 24: 468-473.
- 2 Del Mar Osma M, Ortuno FJ. Marrow noncaseating granulomas: sarcoidosis. *Blood.* 2012; 119: 1622.
- 3 Hameed OA, Skibinska M. Scar sarcoidosis with bone marrow involvement and associated musculoskeletal symptoms. *BMJ Case Rep.* 2011. doi: 10.1136/bcr.02.2011.3863.
- 4 Mostard RL, Prompers L, Weijers RL, et al. F-18 FDG PET/CT for detecting bone and bone marrow involvement in sarcoidosis patients. *Clin Nucl Med.* 2012; 37: 21-25.