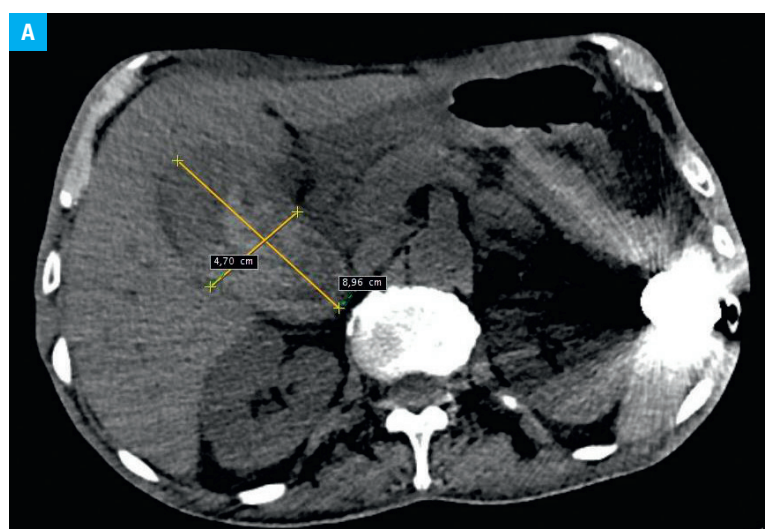


# Severe complication of acquired hemophilia: active bleeding into the gallbladder resulting in cholecystitis requiring surgery

Andrzej R. Hellmann<sup>1</sup>, Stanisław Hać<sup>1</sup>, Justyna Kostro<sup>1</sup>, Zbigniew Śledziński<sup>1</sup>, Andrzej Mital<sup>2</sup>

<sup>1</sup> Department of General, Endocrine and Transplant Surgery, Medical University of Gdańsk, Gdańsk, Poland

<sup>2</sup> Department of Haematology and Transplantology, Medical University of Gdańsk, Gdańsk, Poland



Acquired hemophilia (AH), a hemorrhagic diathesis of an autoimmune origin, is a severe clinical condition with a high overall mortality rate.<sup>1</sup> Clinical manifestations of AH include spontaneous hemorrhages into the skin, muscles, and soft tissues and excessive bleeding during interventional procedures. In approximately 50% of the cases, AH is idiopathic, but in the remaining 50%, it may be associated with pregnancy, autoimmune diseases, malignancies, allergies, or older age.<sup>2,3</sup> However, the exact pathogenesis of AH remains unclear.

Treatment of AH is symptomatic and involves bleeding control, inhibitor eradication, and the treatment of the causative disease. The recommended first-line treatment for bleeding control is bypassing therapy with recombinant activated factor VII (rFVIIa) or plasma-derived activated prothrombin complex concentrates (pd-aPCC). Inhibitor eradication requires immunosuppression, or immunoabsorption and plasmapheresis in the treatment of resistant cases. Approximately 80%

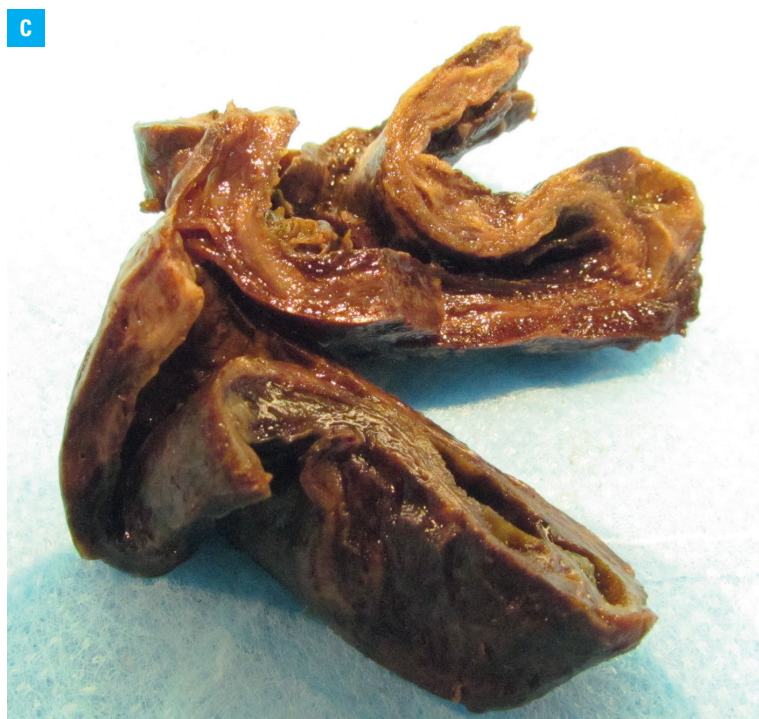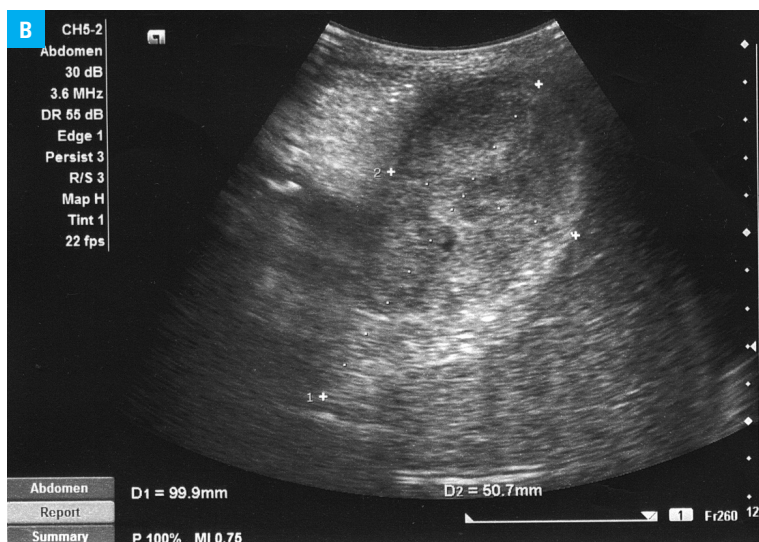
of patients with AH initially present with soft tissue bleeding, mucocutaneous bleeds, epistaxis, cutaneous bleeds, gastrointestinal bleeding, or mucosal bleeding of the genitourinary tract.<sup>4</sup>

We present a case of a 63-year-old man with a serious complication of acquired hemophilia type A (AHA). The patient was admitted to the Department of Hematology with suspected AH, which was then confirmed to be AHA (isolated prolongation of activated partial thromboplastin time, factor VIII inhibitor level of 33 Bethesda units). We used an interdisciplinary approach with its careful hemostatic control before and during surgery, which enabled the patient to safely undergo the required surgical intervention. The patient was given rFVIIa at a dose of 90 µg/kg every 8 hours and immunosuppressive drugs.

On day 10 after admission, the patient developed acute lower abdominal pain and emesis. A physical examination revealed signs of peritoneal irritation in his right upper quadrant. Abdominal computed tomography revealed signs of bleeding into the gallbladder (FIGURE 1A), which was confirmed by an ultrasound examination (FIGURE 1B). Despite the presence of a coagulation disorder, the patient was immediately referred for surgery with a diagnosis of acute cholecystitis with bleeding into the gallbladder.

As hemostatic cover for surgery, the patient received rFVIIa at a dose of 90 µg/kg 1 to 3 minutes before skin incision, followed by consecutive doses of 90 µg/kg every 2 hours. A standard method of retrograde cholecystectomy was used. Four days after surgery, the patient showed no signs of bleeding or peritoneal irritation and was transferred back to the Department of Hematology for further treatment. A histopathological examination revealed that the patient had experienced active cholecystitis with an intramural hematoma (FIGURE 1C).

Correspondence to:  
Andrzej R. Hellmann, MD,  
Klinika Chirurgii Ogólnej,  
Endokrynologicznej i Transplantacyjnej,  
Gdański Uniwersytet Medyczny,  
Smoluchowskiego 17,  
80-214 Gdańsk, Poland,  
phone: +48-58-349-30-10,  
fax: +48-58-349-30-22, e-mail:  
hellmannandrzej@gmail.com  
Received: March 12, 2015.  
Revision accepted: March 17, 2015.  
Published online: March 20, 2015.  
Conflict of interest: none declared.  
Pol Arch Med Wewn. 2015;  
125 (4): 299-300  
Copyright by Medycyna Praktyczna,  
Kraków 2015



**FIGURE 1** **A** – a computed tomography scan of the patient’s enlarged gallbladder (8.96 cm x 4.7 cm); **B** – an ultrasound image of the enlarged gallbladder with blood clots inside (9.9 cm x 5.7 cm); **C** – histopathological findings showing active cholecystitis with intramural hematoma

Our patient with severe AHA who presented with hemobilia as a complication posed a serious clinical challenge. We suggest that when an invasive procedure is needed, a patient with AH should be transferred to a clinical center with an experienced, multidisciplinary medical team that may facilitate hemostatic control and perform the surgical procedure. The availability of bypassing agents is also indispensable because they have been recommended as the first-line therapy for all patients with AH and any active bleeding.

#### REFERENCES

- 1 Makita S, Aoki T, Watarai A, et al. Acquired hemophilia associated with autoimmune bullous diseases: a report of two cases and a review of the literature. *Intern Med.* 2013; 52: 807-810.
- 2 Baudo F, Collins P, Huth-Kühne A, et al. Management of bleeding in acquired hemophilia A: results from the European Acquired Haemophilia (EACH2) Registry. *Blood.* 2012; 120: 39-46.
- 3 Sborov DW, Rodgers GM. How I manage patients with acquired haemophilia A. *Br J Haematol.* 2013; 161: 157-165.
- 4 Stefanacci RG. Acquired inhibitors: a special case of bleeding in older adults. *Curr Gerontol Geriatr Res.* 2012; 2012: 308109.