

CLINICAL IMAGE

Manual aspiration thrombectomy complemented with local thrombolysis for acute renal artery embolism

Dariusz Ciećwierz¹, Paweł Skarżyński¹, Maksymilian Mielczarek¹,
Zbigniew Heleniak², Bolesław Rutkowski², Marcin Gruchała¹

¹ 1st Department of Cardiology, Medical University of Gdansk, Gdańsk, Poland

² Department of Nephrology and Transplantology, Medical University of Gdansk, Gdańsk, Poland

Acute renal artery embolism (RAE) is rare; however, it is often associated with major renal tissue loss. Quick diagnostic workup followed by effective therapy is crucial to save ischemic renal tissue.

A 63-year-old man, who discontinued oral anticoagulation several months after catheter ablation for paroxysmal atrial fibrillation (AF), presented with acute left-sided abdominal and lumbar pain. The symptoms appeared 20 hours before hospital

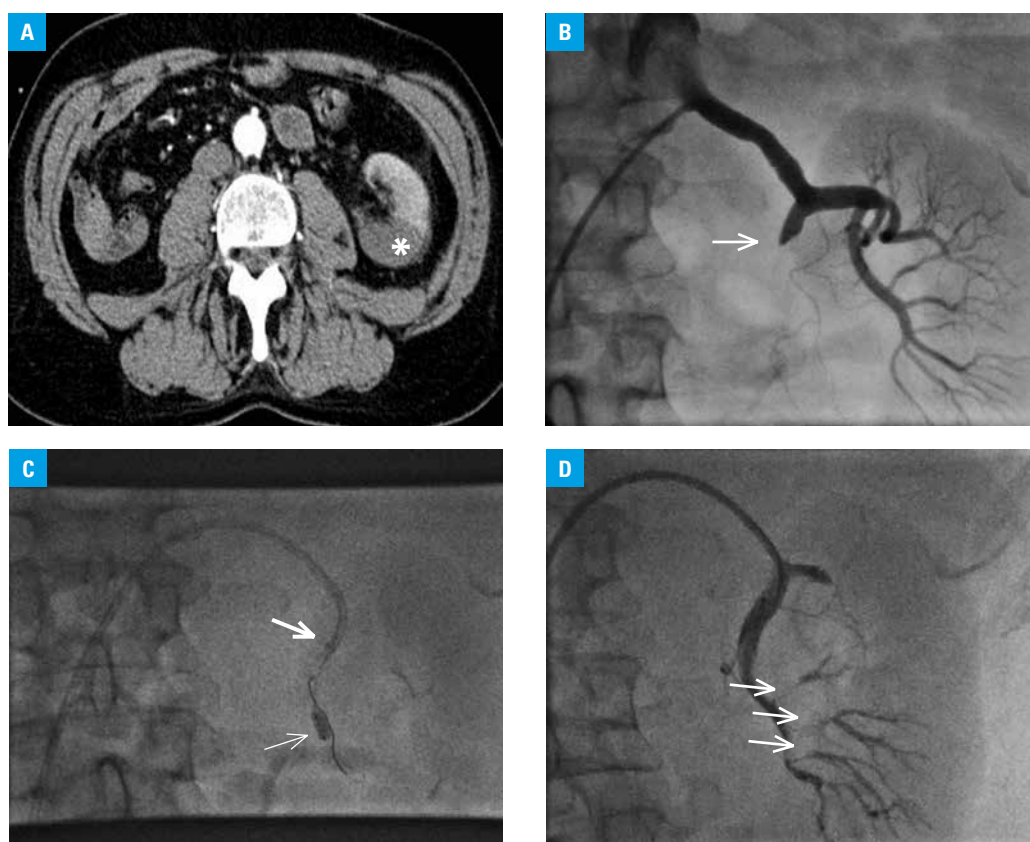


FIGURE 1 **A** – computed tomography scan: a hypodense area involving the dorsal part of the left kidney (asterisk); **B** – angiography: occlusion of the posterior branch of the left renal artery (arrow); **C** – thrombus aspiration with a guiding catheter (arrow) with simultaneous balloon inflation beyond the site of the occlusion (thin arrow); **D** – angiography: a reopened branch with thrombus remnants located distally (arrows)

Correspondence to:
Maksymilian Mielczarek, MD,
I Klinika Kardiologii,
Gdański Uniwersytet Medyczny,
ul. Dębinki 7, 80-210 Gdańsk, Poland,
phone: +48 58 349 25 00,
fax: +48 58 346 12 01,
e-mail: max.mielczarek@gmail.com

Received: April 22, 2015.

Revision accepted: May 19, 2015.

Published online: May 22, 2015.

Conflict of interest: none declared.

Pol Arch Med Wewn. 2015;

125 (6): 473-474

Copyright by Medycyna Praktyczna,

Kraków 2015

admission. A computed tomography scan (CT) showed a hypodense area of 81 × 38 mm, involving the entire inferior pole and dorsal part of the left kidney, suggesting infarction (FIGURE 1A). A CT angiography revealed an occlusion of the posterior branch of the left renal artery. Owing to persistent pain, the patient was referred to a nephrologist and vascular surgeon, who suggested endovascular treatment. The patient was transferred to a institutional cardiac catheterization facility. A 7Fr arterial sheath was inserted in the right femoral artery, and the Judkins Right 4 7Fr guiding catheter—into the left renal artery. Contrast injection confirmed the occlusion of its posterior branch (FIGURE 1B). Aspiration with the 7Fr system for manual thrombectomy was attempted but without success. Therefore, thrombectomy with the use of a guiding catheter was attempted (FIGURE 1C). First, a balloon catheter (4.0 × 8.0 mm) was inflated beyond the site of the occlusion to ensure protection from distal embolism (FIGURE 1C). Suction pressure was generated with a 20-cc syringe attached to the distal tip of the guiding catheter. A large amount of thrombotic material was extracted, which restored the flow in the occluded branch (FIGURE 1D). Finally, a bolus of 20-mg tissue plasminogen activator, alteplase, was administered directly into the reopened artery to clear it up. The patient reported immediate pain relief. Laboratory tests showed an increase in creatinine levels to 1.21 mg/dl and C-reactive protein levels to 106 mg/l, which gradually normalized within a couple of days. Heparin infusion with a dose adjusted to the activated partial thromboplastin time level was continued for 2 days after the procedure, and on day 3, the patient was switched to a new oral anticoagulant. He was discharged with a recommendation of lifelong anticoagulation therapy. A follow-up Doppler ultrasound showed normal perfusion of the rescued renal tissue.

The present case emphasizes the need to consider RAE when left-sided abdominal pain occurs in a patient with risk factors for systemic embolism,^{1,2} mainly AF, left ventricle aneurysm, or atherosclerosis of the aorta.³ The treatment of RAE may involve anticoagulation, surgical embolectomy, or endovascular procedure, which is sometimes complemented with local thrombolysis.⁴ This is the first reported case of RAE treated with thrombectomy, with the use of a guiding catheter as an aspiration device. This technique should be considered when the renal artery or its main branches are occluded by large embolic material or locally formed thrombus. It should be emphasized that the decision to discontinue oral anticoagulation after catheter ablation for AF should be made with caution after individual thromboembolic risk assessment.⁵

REFERENCES

- 1 Lessman RK, Johnson SF, Coburn JW, Kaufman JJ. Renal artery embolism: clinical features and long-term follow-up of 17 cases. *Ann Inter Med.* 1978; 89: 477-482.
- 2 Fort J, Segarra A, Matas M, et al. Renal artery embolism: prospective study of 41 patients based on a diagnostic and therapeutic algorithm. *The Open Urol Nephrol J.* 2008; 1: 9-15.
- 3 Rutkowski B, Danowska A. [Acute renal failure in a case of thrombosis of abdominal aorta and both renal arteries]. *Pol Tyg Lek.* 1972; 27: 1857-1858. Polish.
- 4 Uta H, Michael K, Hermann P, et al. A rare case of acute renal failure—acute bilateral renal artery embolism. *Nephrol Dial Transplant.* 2008; 23: 2095-2097.
- 5 Kornej J, Potpara T, Lip GY. Anticoagulation management in nonvalvular atrial fibrillation: current and future directions. *Pol Arch Med Wewn.* 2013; 123: 623-634.