

# Endosonography-guided fine-needle aspiration in the diagnosis of sarcoidosis: a randomized study

Piotr Kocoń<sup>1</sup>, Artur Szlubowski<sup>2</sup>, Jarosław Kuźdżał<sup>1</sup>, Lucyna Rudnicka-Sosin<sup>3</sup>, Adam Ćmiel<sup>4</sup>, Jerzy Soja<sup>5</sup>, Janusz R. Włodarczyk<sup>1</sup>, Piotr Talar<sup>1</sup>, Tomasz Smęder<sup>1</sup>, Tomasz Gil<sup>1</sup>, Janusz Warmus<sup>1</sup>, Romana Tomaszewska<sup>6</sup>

1 Department of Thoracic Surgery, Jagiellonian University Medical College, John Paul II Hospital, Kraków, Poland

2 Endoscopy Unit, John Paul II Hospital, Kraków, Poland

3 Department of Pathology, John Paul II Hospital, Kraków, Poland

4 Department of Applied Mathematics, AGH University of Science and Technology, Kraków, Poland

5 Department of Pulmonology, Jagiellonian University Medical College, Kraków, Poland

6 Department of Pathology, Jagiellonian University Medical College, Kraków, Poland

## KEY WORDS

bronchoscopy,  
endosonography,  
mediastinoscopy,  
sarcoidosis

## ABSTRACT

**INTRODUCTION** There are no widely accepted standards for the diagnosis of sarcoidosis.

**OBJECTIVES** The aim of this study was to assess the relative diagnostic yield of endobronchial ultrasound fine-needle aspiration (EBUS-FNA) and endoscopic ultrasound fine-needle aspiration (EUS-FNA), and to compare them with standard diagnostic techniques such as endobronchial biopsy (EBB), transbronchial lung biopsy (TBLB), transbronchial needle aspiration (TBNA), and mediastinoscopy.

**PATIENTS AND METHODS** This was a prospective randomized study including consecutive patients with clinical diagnosis of stage I or II sarcoidosis. EBB, TBLB, and TBNA were performed at baseline in all patients. Subsequently, patients were randomized to group A (EBUS-FNA) or group B (EUS-FNA). Next, a crossover control test was performed: all patients with negative results in group A underwent EUS-FNA and all patients with negative results in group B underwent EBUS-FNA. If sarcoidosis was not confirmed, mediastinoscopy was performed.

**RESULTS** We enrolled 106 patients, of whom 100 were available for the final analysis. The overall sensitivity and accuracy of standard endoscopic methods were 64% each. When analyzing each of the standard endoscopic methods separately, the diagnosis was confirmed with EBB in 12 patients (12%), with TBLB in 42 patients (42%), and with TBNA in 44 patients (44%). The sensitivity and accuracy of each endosonographic technique were significantly higher than those of EBB + TBLB + TBNA ( $P = 0.0112$  vs  $P = 0.0134$ ).

**CONCLUSIONS** The sensitivity and accuracy of EBUS-FNA and EUS-FNA are significantly higher than those of standard endoscopic methods. Moreover, the sensitivity and accuracy of EUS-FNA tend to be higher than those of EBUS-FNA.

**INTRODUCTION** Sarcoidosis is a disease of unknown etiology, characterized by the formation of noncaseating granulomas in multiple organs.<sup>1,2</sup> In approximately 90% of patients, the mediastinal lymph nodes and lung parenchyma are involved.<sup>3</sup> The diagnosis is made on the basis of a clinical picture and imaging, and its confirmation requires finding of noncaseating granulation in a biopsy

specimen.<sup>1</sup> As there is no specific cytological or histological pattern of sarcoidosis, the disease cannot be confirmed only by cytology or histology. The diagnosis of sarcoidosis also requires the exclusion of other diseases that may present the same cytological or histological pattern.

There are no uniformly accepted diagnostic algorithms in sarcoidosis. Several bioptic

## Correspondence to:

Piotr Kocoń, MD, PhD,  
Klinika Chirurgii Klatki Piersiowej,  
Uniwersytet Jagielloński, Collegium  
Medicum, Szpital im. Jana Pawła II,  
ul. Prądnicka 80, 31-202 Kraków,  
Poland, phone: +48 12 614 20 28  
e-mail: pkocon@poczta.onet.pl

Received: September 28, 2016.

Revision accepted: February 9, 2017.

Published online: February 9, 2017.

Conflict of interest: none declared.

Pol Arch Intern Med. 2017;

127 (3): 154-162

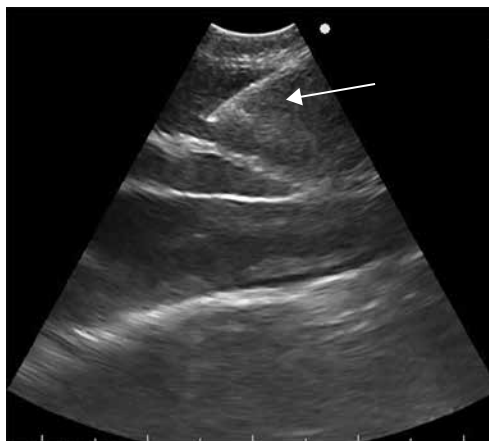
doi:10.20452/pamw.3934

Copyright by Medycyna Praktyczna,

Kraków 2017

**FIGURE 1**

Endobronchial ultrasound needle aspiration of lymph node station 4R, showing the biopsy needle within the node (arrow)



techniques have been used, including endobronchial biopsy (EBB), transbronchial lung biopsy (TBLB), transbronchial needle aspiration (TBNA), and mediastinoscopy. Recently, endobronchial ultrasound fine-needle aspiration (EBUS-FNA) and endoscopic ultrasound fine-needle aspiration (EUS-FNA) have been introduced.

**PATIENTS AND METHODS** The study was performed in the Department of Thoracic Surgery, Jagiellonian University Medical College, John Paul II Hospital, Kraków, Poland. The study design was approved by the Local Bioethics Committee (79/KBL/OIL/2009). All patients received detailed information regarding the study. The procedures, including the expected results and potential risks, were discussed with patients, and their informed consent was obtained.

It was a prospective randomized study including a consecutive group of patients with suspected stage I or II sarcoidosis, who were referred to the Department of Thoracic Surgery between October 2009 and May 2012.

The clinical questions of the study were: 1) what is the diagnostic yield of the standard bioptic techniques (ie, EBB, TBLB, and TBNA) versus the endosonography-guided techniques (ie, EBUS-FNA and EUS-FNA) in diagnosing sarcoidosis, and 2) which of these 2 endosonography-guided techniques is more accurate in diagnosing sarcoidosis.

The inclusion criteria were as follows: age over 18 years, clinical diagnosis of stage I or stage II sarcoidosis, and signed written informed consent. The exclusion criteria were lack of patient's consent to undergo endoscopic bioptic techniques or mediastinoscopy, contraindications to bronchoscopy (eg, respiratory insufficiency or tracheal stenosis), coagulation disorders, and pregnancy.

Patients were randomized in a ratio of 1:1, using a computerized random digit generator in 2 groups. In group A, EBUS-FNA was performed, and in group B, EUS-FNA. In both groups, the standard diagnostic tests were performed during the same procedure, including EBB, TBLB, TBNA, and BACTEC Mycobacteria Growth Indicator Tube System analysis of the bronchial lavage. Patients were enrolled and randomized by 2 team

members (PK or AS). All the above tests were performed during the same procedure.

In patients in whom these studies failed to confirm the diagnosis, a second endosonography-guided bioptic technique was utilized in a crossover fashion (ie, EUS-FNA in those in whom EBUS-FNA was performed initially and EBUS-FNA in those in whom EUS-FNA was performed initially).

If the second endosonography-guided bioptic technique failed to confirm the diagnosis, patients were scheduled for mediastinoscopy.

The recruitment of participants was stopped after inclusion of the planned number of 100 patients. All patients were followed for at least 6 months.

Endoscopic examination was performed using conscious sedation with midazolam and fentanyl, and local administration of lidocaine. For standard bronchoscopy, the BF 1T180 videobronchoscope (Olympus Medical Systems Corporation, Tokyo, Japan) was used.

The TBNA biopsy was performed using the MW-122 (22-gauge/13 mm) or SW-121 (21-gauge/15 mm) cytological needles (ConMed Endoscopic Technologies, Utica, New York, United States) or the NA-411D-1521 (21-gauge/15 mm) needle (Olympus Medical Systems Corporation, Tokyo, Japan).

For EBB and TBLB, biopsy forceps (M00515180; working channel diameter, 2.0 mm; jaw outer diameter, 1.8 mm; Boston Scientific, Marlborough, Massachusetts, United States) were utilized. The standard technique of EBB was implemented, with 3 to 8 samples taken from abnormal areas of bronchial mucosa or from the carina of the right upper lobe or the middle lobe. In order to obtain tissue from the deeper part of the mucosa and the submucosal layer of the bronchial wall, several biopsies were taken from the same place.

The site of TBLB was chosen on the basis of the high-resolution chest computed tomography; 2 to 5 samples were taken.

Mediastinal lymph node biopsy was preceded by thorough ultrasound assessment of the entire mediastinum.

For the EBUS-FNA group, a BF-UC160F-OL8 videobronchoscope (Olympus Medical Systems Corporation) with the EU-C60 7.5 MHz ultrasound processor was used. For the biopsy, the cytological 22G/40-mm needle (NA-201SX-4022, Olympus Medical Systems Corporation) was used. Biopsy of lymph node stations 11R, 10R, 11L, 10L, 7, 4R, and 4L was performed (FIGURE 1).

For the EUS-FNA, the GF-UCT160-OL5 videogastroscope (Olympus Medical Systems Corporation) with the EU-C60 7.5 MHz ultrasound processor was used. For biopsy, the cytological 22G/80-mm needle (NA-200H-8022, Olympus Medical Systems Corporation) was utilized. Biopsy of lymph node stations 7 and 4L was performed (FIGURE 2).

During TBNA, EBUS-FNA, and EUS-FNA, 3 to 6 samples were obtained from each lymph node.

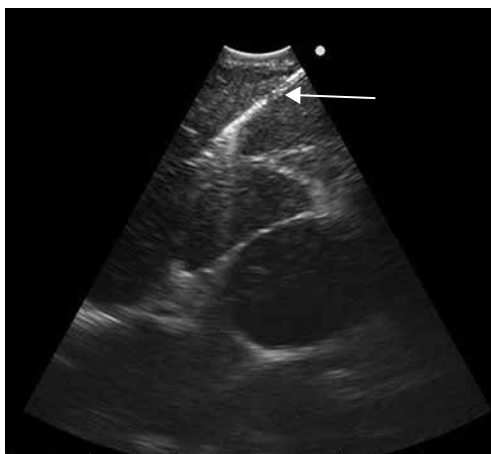
**TABLE 1** Characteristics of patients in the study groups<sup>a</sup>

Characteristics	Group A (EBUS-NA)	Group B (EUS-NA)	<i>P</i> value
Age, y, mean (range)	38 (20–57)	39 (25–70)	0.104
Men, n (%)	32 (59.3)	25 (54.3)	0.687
Women, n (%)	22 (40.7)	21 (45.7)	0.687
Stage I sarcoidosis, n (%)	30 (55.6)	24 (52.2)	0.841
Stage II sarcoidosis, n (%)	24 (44.4)	22 (47.8)	0.841
Steroid therapy, n (%)	4 (7.4)	6 (13)	1.000

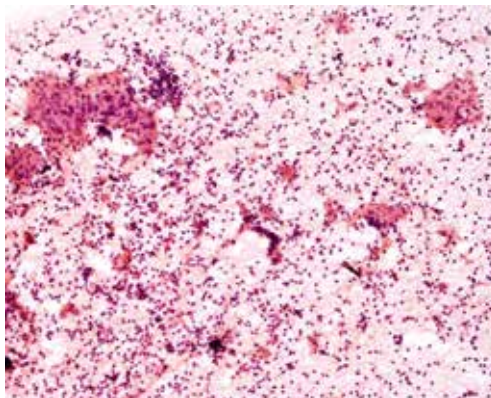
**a** Data of excluded patients are not included in the table.

Abbreviations: EBUS-FNA, endobronchial ultrasound fine-needle aspiration; EUS-FNA, endoscopic ultrasound fine-needle aspiration

**FIGURE 2** Endoscopic ultrasound needle aspiration of lymph node station 7, showing the typical pattern of lymph nodes with marked capsules (arrow)



**FIGURE 3** Cytological smear of a lymph node sample in a patient with sarcoidosis, showing the groups of epithelioid cells typical for sarcoidosis



The cytological smear of the biopsy specimen was performed and fixed using 96% ethanol. Additionally, a nonfixed sample was prepared for the BACTEC examination. Samples from each lymph node station were prepared separately. The standard hematoxylin and eosin staining was used (FIGURE 3). Samples were independently reviewed by 2 pathologists, who were blinded to the sampling method.

Mediastinoscopy was performed in the standard fashion, under general anesthesia, using the Linder–Dahan mediastinoscope (Richard Wolf GmbH, Knittlingen, Germany). Lymph node stations 4R, 4L, 7, and 10R were sampled.

The sample size was determined to detect the difference equal to 10% between 2 proportions in partially dependent samples with a significance level of 0.05 and a power of 0.7.

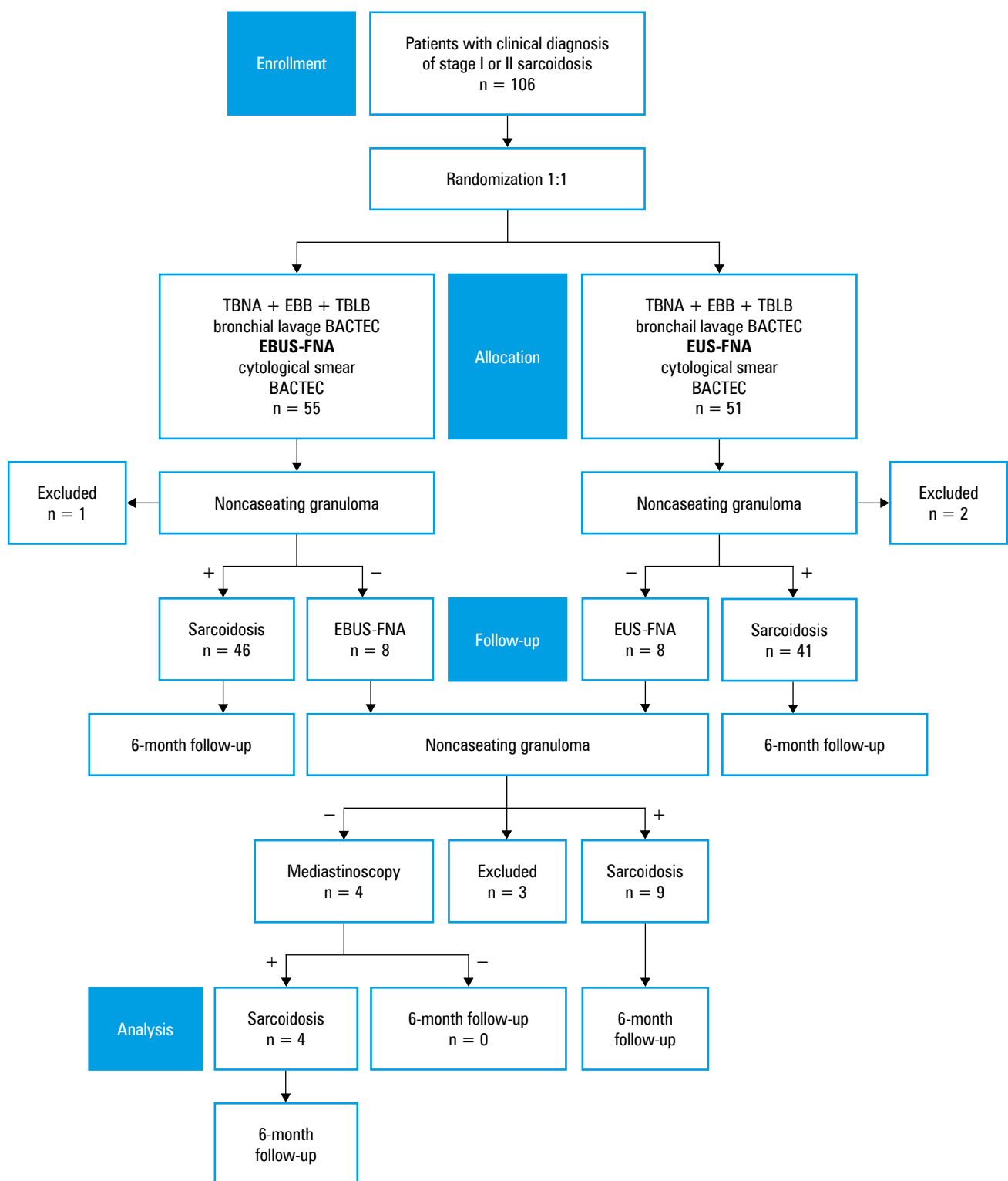
The descriptive statistics, mean and median values, as well as standard deviation and quartiles were used. The sensitivity of tests with a 95% confidence interval was determined using the GraphPad InStat 3.05 software (GraphPad Software, San Diego, California, United States). The bootstrap method was used in Statistica™ (Statsoft Inc., Tulsa, Oklahoma, United States) to compare the sensitivity of different tests. The level of significance was set at a *P* value of 0.05 or lower.

**RESULTS** Between October 2009 and May 2012, 106 patients were enrolled to the study. There were 61 men and 45 women (mean age, 38.7 years; range, 20–70 years). Stage I sarcoidosis was diagnosed in 55 patients, and stage II, in 51 patients. Coughing and fatigue, which are the most common clinical signs of sarcoidosis,<sup>1</sup> were present in all patients. Ankle swelling was present in 70 patients, and erythema nodosum—in 40.

Having performed the standard diagnostic tests (EBB, TBNA, and TBLB), 55 patients were randomly allotted to group A and 51—to group B. The characteristics of the patients in both groups are presented in TABLE 1.

In group A, one patient was excluded due to initiation of treatment by his physician before the diagnosis had been confirmed (this was because of signs of neurosarcoidosis and typical clinical picture). In group A, EBUS-FNA failed to establish the diagnosis in 8 patients (FIGURE 4). In group B, 2 patients were excluded. In one of them, complete remission of mediastinal lymphadenopathy was found on endosonography and in another patient malignant cells were found in the lymph node sample (a diagnosis of lung cancer was subsequently confirmed). In group B, EUS-FNA failed to establish the diagnosis in 8 patients. Therefore, the crossover endosonographic examination was performed in 16 patients. Out of the 8 patients who had undergone the crossover EUS-FNA, the diagnosis was confirmed in 7, while out of the 8 patients who had undergone the crossover EBUS-FNA, the diagnosis was made in 2.

There were no complications related to the procedure or anesthesia in any of the patients.



**FIGURE 4** Flowchart of patients. Abbreviations: EBB, endobronchial biopsy, TBLB, transbronchial lung biopsy, TBNA, transbronchial needle aspiration; others, see [TABLE 1](#)

Three patients were excluded at this stage. Two of them withdrew their consent to undergo mediastinoscopy, and in 1 patient complete remission of mediastinal lymphadenopathy was found on endosonography.

Because of the lack of diagnosis, mediastinoscopy was performed in 4 patients and confirmed sarcoidosis in all of them ([FIGURE 4](#)).

For the final analysis, data from 100 patients were available. Cytological or histological confirmation of the diagnosis was obtained in all patients. Minimally invasive techniques, that is, EBB, TBNA, TBLB, EBUS-FNA, and EUS-FNA, were successful in 96% of patients, and mediastinoscopy was only necessary in the remaining 4%.

**TABLE 2** Diagnostic yield of bioptic techniques

Test	Sensitivity		Accuracy	
	Value	95% CI	Value	95% CI
EBB	0.12	0.06–0.19	0.12	0.064–0.20
TBLB	0.42	0.32–0.52	0.42	0.32–0.52
TBNA	0.42	0.16–0.69	0.44	0.14–0.69
EBB + TBLB	0.44	0.34–0.54	0.44	0.34–0.54
EBB + TBLB + TBNA	0.64	0.54–0.73	0.64	0.54–0.73
EBUS-FNA	0.62	0.49–0.74	0.62	0.49–0.74
EUS-FNA	0.75	0.61–0.85	0.75	0.61–0.85
EBUS-FNA + EUS-FNA	0.80	0.71–0.87	0.80	0.71–0.87

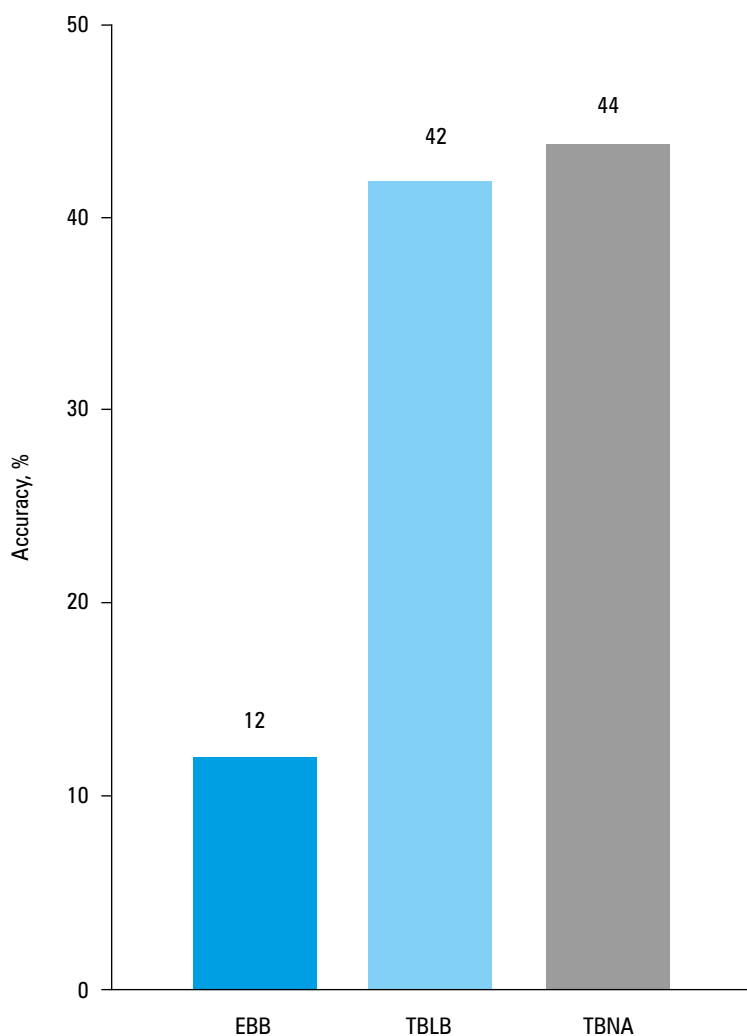
Abbreviations: EBB, endobronchial biopsy, TBLB, transbronchial lung biopsy, TBNA, transbronchial needle aspiration; others, see [TABLE 1](#) and [FIGURE 4](#)

The sensitivity and accuracy of the standard diagnostic techniques were as follows: 0.12 and 0.12, respectively, for EBB; 0.42 and 0.42, respectively, for TBLB; and 0.42 and 0.44, respectively, for TBNA ([TABLE 2](#) and [FIGURE 5](#)). A combination of all standard endoscopic techniques (ie, EBB, TBLB, and TBNA) allowed for the confirmation of the diagnosis in 64% of the patients, with sensitivity and accuracy of 0.64.

The diagnostic yield of the endosonographic techniques was higher than that of the standard

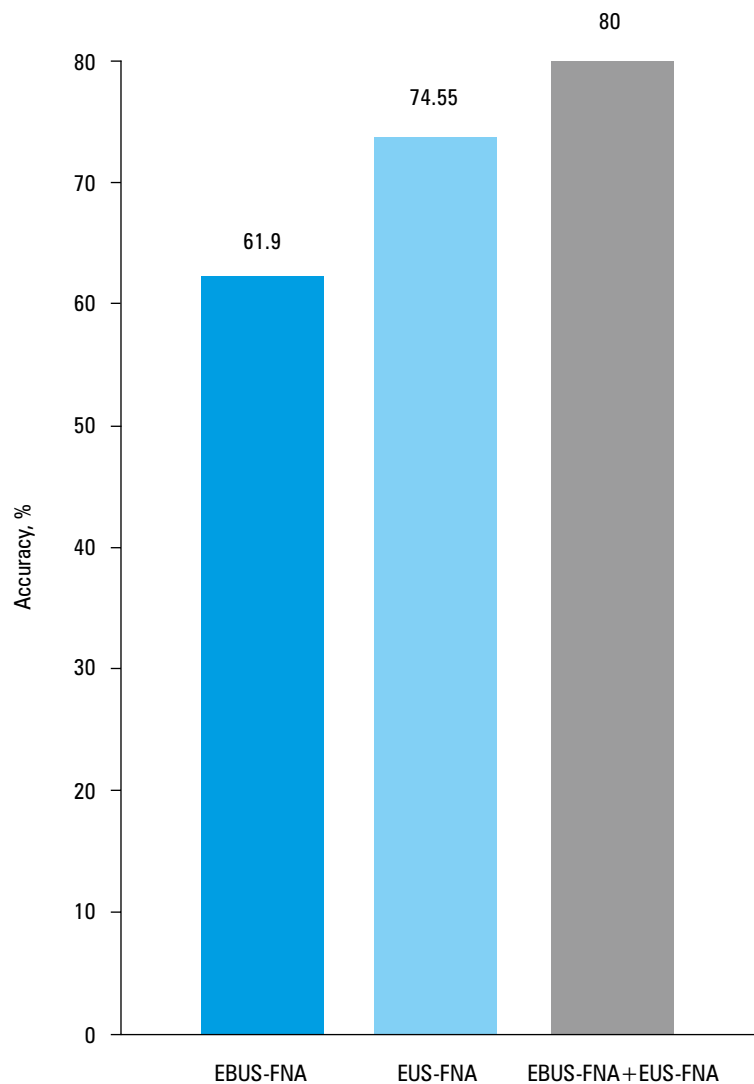
techniques. For EBUS-FNA, sensitivity and accuracy were 0.62, and for EUS-FNA—0.75. Combination of EBUS-FNA and EUS-FNA had the sensitivity and accuracy of 0.8 ([TABLE 2](#) and [FIGURE 6](#)).

The bootstrap method was used to compare the sensitivity and accuracy of different tests. Sensitivity and accuracy of each of the endosonographic techniques were significantly better than those of EBB + TBLB ( $P = 0.0072$  and  $P = 0.0084$ , respectively) and than those of EBB + TBLB + TBNA ( $P = 0.0112$  and  $P = 0.0134$ , respectively).



**FIGURE 5** Diagnostic accuracy of standard bioptic techniques  
Abbreviations: see [FIGURE 4](#)

**FIGURE 6** Diagnostic accuracy of endosonographic techniques  
Abbreviations: see **TABLE 1**



The comparison of EBUS-FNA and EUS-FNA showed higher sensitivity and accuracy of the latter, but the difference did not reach the level of significance ( $P = 0.0724$  and  $P = 0.0810$ , respectively).

The BACTEC examination of bronchial lavage or lymph node samples did not reveal tuberculosis in any of the patients.

**DISCUSSION** Cytological or histological confirmation of sarcoidosis is an important element of diagnosis. For this purpose, EBB and TBLB, and also in many centers TBNA, have been used. The widespread use of the endosonographic techniques—EBUS and EUS—for lung cancer staging<sup>4-8</sup> has given rise to an interest in applying them also to cover the diagnosis of sarcoidosis.<sup>9</sup> Our study is novel in that it was based on the assessment of modern, minimally invasive endosonographic techniques and pathological examination of cytological smears rather than histological specimens. The main advantage of the endoscopic techniques is that they save patients from invasive surgical biopsy via mediastinoscopy. Literature data show a trend towards replacement of mediastinoscopy by the minimally invasive

techniques.<sup>2,4-8</sup> In the present study, the diagnosis of sarcoidosis was confirmed using minimally invasive methods in 96% of the patients, and mediastinoscopy was only necessary in 4%.

An important development in the diagnosis of sarcoidosis is the feasibility of a reliable confirmation on the basis of cytological smear, because it eliminates the need for invasive procedures aimed at taking large samples for a histological examination. An adequately experienced pathologist is crucial, and differentiation with other clinical entities presenting with similar granulomas is necessary. In the present study, all samples were assessed independently by 2 pathologists, and testing for tuberculosis was routinely performed.

It should be noted that, at the time of biopsy, the intensity of symptoms varied among patients. In most of them, biopsy was performed at a point where symptoms had subsided or even almost completely resolved. This was due to the long time of initial diagnostic workup from the first onset of symptoms, before the patients were referred for biopsy. This delay was underlined by Judson et al.<sup>10</sup> It is mainly dependent on clinical symptoms, on the basis of which general practitioners may suspect sarcoidosis. Judson et al<sup>10</sup> analyzed

data of 189 patients. Sarcoidosis was diagnosed or suspected during the first visit in only 15%, and a median of 4 visits was needed to make the final diagnosis in 79% of them. The time since the onset of symptoms was less than 3 months in 50% of the patients and less than 6 months in 68%. This time was longer when only pulmonary symptoms were present and shorter if skin signs occurred.

Fifty patients analyzed in the present study had initially been diagnosed in pulmonology departments of other hospitals. In 11 patients, corticosteroid therapy had been initiated before the diagnostic workup was completed, with a subsequent remission of symptoms. This symptomatic improvement was associated with remission of pulmonary lesions and, more importantly, of mediastinal lymphadenopathy.

In our study, endosonography confirmed that the paratracheal lymphadenopathy subsided first, with subcarinal and hilar nodes being still enlarged. As the latter are easily accessible by endosonography-guided biopsy, this pattern of remission favors the minimally invasive techniques over mediastinoscopy.

In our opinion, the possibility of monitoring the size of lymph nodes is an important advantage of endosonography, reducing the need for computed tomography and, therefore, patients' exposure to radiation. It should be taken into consideration and confirmed in further studies.

The diagnostic modality that has traditionally been favored by pulmonologists is EBB, with TBLB and TBNA used by some endoscopists.<sup>9,11</sup> In the present study, EBB, TBLB, and TBNA were considered the standard techniques, which is consistent with other studies.<sup>1,9</sup> With these techniques, the diagnosis of sarcoidosis was confirmed in 64% of the patients. Adding TBNA to the combination of EBB + TBLB increased the sensitivity by 20%. This observation supports using TBNA at the initial stage of the diagnostic workup. It is also important that TBNA is technically simple and does not require expensive equipment.

According to Morales et al,<sup>12</sup> who analyzed 51 patients, adding TBNA to TBLB increased the rate of diagnosis from 60% to 83% in stage I sarcoidosis and from 76% to 86% in stage II sarcoidosis.

In the present study, the sensitivity and accuracy of EBUS-FNA were 0.62 and 0.62, respectively, and of EUS-FNA—0.75 and 0.75, respectively, while the combination of EBUS-FNA and EUS-FNA allowed for confirmation of the diagnosis in 80% of the patients. In a meta-analysis published in 2012, including data from 553 patients taken from 15 studies, the accuracy of endosonographic techniques was 54% to 93%.<sup>13</sup> The high sensitivity of endosonographic techniques (71%–100%) has been confirmed by other authors, and these numbers are consistent with the results of the present study.<sup>2,6,8,14-21</sup> In a randomized study by Tremblay et al,<sup>22</sup> the difference in sensitivity between EBUS-FNA and TBNA was 29.5% in favor of the former. In one study, the sensitivity of TBNA was the same as

for EBUS-FNA (93%), but the number of patients in this study was very small ( $n = 15$ ).<sup>19</sup>

Experience is particularly important in each procedure. In the case of endosonographic techniques, experience of the endoscopic team as well as of pathologists in cytology smear assessment is necessary. In the study of Szlubowski et al<sup>21</sup> in a group of 41 patients with suspected sarcoidosis, the diagnosis was confirmed in 85.7% of the cases. In the study of Gnass et al<sup>23</sup> (performed with participation of our team), the sensitivity and accuracy of EBUS-FNA were 0.79 and 0.8, respectively, and of EUS-FNA—0.88 and 0.89, respectively. In the study of Szlubowski et al<sup>21</sup> the same technique was used, but a different pathology team assessed cytological smears. In the study of Gnass et al,<sup>23</sup> as in the present study, patients were diagnosed in the same endoscopy unit. The study of Gnass et al<sup>23</sup> was designed and started at the end of enrolling patients to this study. The inclusion and exclusion criteria were similar. Patients in the study of Gnass et al<sup>23</sup> were referred from the Departments of Pulmonology at John Paul II Hospital (a different group of patients). Cytological smears were assessed in the same Department of Pathology. The study of Gnass et al<sup>23</sup> had a different design but assessed mainly endosonographic techniques. The EBUS/EUS has been used in this endoscopy unit since 2008. During the years from 2009 to 2013 (first study, October 2009 – May 2012, described in this publication; then, January 2012 – February 2013, described in the study of Gnass et al<sup>23</sup>), the endoscopic and pathology teams gained more experience in the technique, which resulted in much higher sensitivity of the procedures.

In a prospective study by Tournoy et al,<sup>20</sup> endosonographic techniques confirmed the diagnosis of sarcoidosis in an additional 59% of patients in whom the results of the standard endoscopic techniques had been negative.

The standard endoscopic techniques (ie, EBB, TBLB, and TBNA) were compared with EBUS-FNA by Navani et al.<sup>24</sup> The sensitivity of these methods were 35% and 85%, respectively. Von Bartheld et al<sup>18</sup> conducted a prospective study including 101 patients with suspected sarcoidosis in whom standard endoscopic techniques had failed to confirm the diagnosis in 55%. The sensitivity of EUS-FNA was 92% in stage I and 77% in stage II sarcoidosis. The authors suggested that 4 needle passes are optimal for a reliable diagnosis.<sup>18</sup>

In the present study, EBB enabled the confirmation of diagnosis only in 12% of the patients. It has been reported that its diagnostic yield is higher if there are bronchoscopically detectable lesions of the bronchial mucosa. Armstrong et al,<sup>25</sup> in a group of 101 patients with suspected sarcoidosis, found sensitivity of EBB to be 58% in stage I and 62% in stage II sarcoidosis. The authors also noted that the rate of diagnosis was 91% if there were mucosal lesions, but only 37% in case of normal mucosa. Sensitivity similar to the present study (0.14) was reported by Ziara et al<sup>26</sup> in a study which included 112 patients.

The results of the present study confirm the superiority of EBUS-FNA and EUS-FNA in the diagnosis of stage I and II sarcoidosis. However, the availability of adequately equipped endoscopy suits and staff trained in both EBUS and EUS is a factor limiting the widespread use of these techniques. In particular, pulmonologists generally do not have experience in esophageal endoscopy, and gastroenterologists do not perform bronchoscopy. At present, endoscopists experienced in EBUS and EUS are only available in a few institutions.

Therefore, in institutions with limited access to EBUS and EUS, the routine use of TBNA seems a reasonable option. In the present study, the sensitivity of TBNA was 0.44, which is comparable to literature data reporting a sensitivity of TBNA between 0.38 and 0.90.<sup>4,5,7,12,27</sup> In a meta-analysis of 21 studies encompassing 915 patients, the mean sensitivity of TBNA was 0.62 (CI, 0.52–0.71).<sup>15</sup>

The diagnostic yield of TBNA depends on several factors, such as the gauge on the needle, the size and location of the nodes, and the endoscopist's experience. In a study including 100 patients, Herth et al<sup>28</sup> compared EBUS-FNA and TBNA in the assessment of different nodal stations in patients with adenopathy of different origin. The authors found that for stations other than subcarinal, EBUS-FNA was superior to TBNA, with a diagnostic yield of 0.84 and 0.58, respectively ( $P < 0.001$ ). The respective values for the subcarinal nodes were 0.86 and 0.74, and the difference was not significant ( $P = 0.3$ ).<sup>28</sup>

It is likely that remission of lymphadenopathy contributed to the lower sensitivity of TBNA in the present study. If the TBNA had been performed at an early stage of disease, with marked lymph node enlargement, the sensitivity would have probably been higher. It should be stressed that during TBNA, 3 to 6 samples were obtained from each lymph node, which is in accordance with the published standard.<sup>26</sup>

The sensitivity of TBLB in the present study was 0.42, which is consistent with literature data, reporting a sensitivity of 0.35 to 0.90.<sup>24,29-31</sup>

Descombes et al<sup>32</sup> analyzed 530 TBLB in 516 patients and reported a sensitivity of 0.56 in stage I and of 0.75 in stage II sarcoidosis. If 6 to 10 samples were obtained, the diagnosis was established in 69% of patients, while it was 38% if the number of samples was between 1 and 3. This difference was significant ( $P < 0.01$ ).<sup>32</sup> In the present study TBLB confirmed sarcoidosis in 19 patients with normal plain chest radiographs. These figures are also consistent with literature data.<sup>31</sup>

The results of the present study showed higher sensitivity and accuracy of EUS-FNA than of EBUS-FNA, but the difference was not significant. There were no complications in any of the groups.

In conclusion, the diagnostic sensitivity and accuracy of endosonographic technique (EBUS-FNA and EUS-FNA) are significantly higher in comparison with the standard endoscopic methods ( $P < 0.01$ ). Endosonographic techniques seem to

be the methods of choice in patients suspected of sarcoidosis stages I and II. A combination of standard endoscopic methods, especially TBNA and TBLB, increases the yield of confirmation of sarcoidosis.

**Contribution statement** PK, JK, and AS conceived the idea for the study and contributed to the design of the research. PK, AS, JW, JRW, PT, TS, TG, JW, and LR-S were involved in data collection. PK and AĆ analyzed the data. LR-S and RT performed pathological assessment of all samples. PK, JK, AS, and JS edited the manuscript. All authors approved the final version of the manuscript.

## REFERENCES

- 1 Statement on sarcoidosis. Joint Statement of the American Thoracic Society (ATS), the European Respiratory Society (ERS) and the World Association of Sarcoidosis and Other Granulomatous Disorders (WASOG) adopted by the ATS Board of Directors and by the ER. *Am J Respir Crit Care Med.* 1999; 160: 736-755.
- 2 Costabel U, Ohshimo S, Guzman J. Diagnosis of sarcoidosis. *Curr Opin Pulm Med.* 2008; 14: 455-461
- 3 Baughman RP, Teirstein AS, Judson MA, et al. Clinical characteristics of patients in a case control study of sarcoidosis. *Am J Respir Crit Care Med.* 2001; 164: 1885-1889.
- 4 Szlubowski A, Kuzdzal J, Soja J, et al. [Transbronchial needle aspiration as a diagnostic method in lung cancer and non-malignant mediastinal adenopathy]. *Pneumonol Alergol Pol.* 2007; 75: 5-12. Polish.
- 5 Cetinkaya E, Yildiz P, Altin S, Yilmaz V. Diagnostic value of transbronchial needle aspiration by Wang 22-gauge cytology needle in intrathoracic lymphadenopathy. *Chest.* 2004; 125: 527-531.
- 6 Annema JT, Veselić M, Rabe KF. Endoscopic ultrasound-guided fine-needle aspiration for the diagnosis of sarcoidosis. *Eur Respir J.* 2005; 25: 405-409.
- 7 Trisolini R, Tinelli C, Cancellieri A, et al. Transbronchial needle aspiration in sarcoidosis: yield and predictors of a positive aspirate. *J Thorac Cardiovasc Surg.* 2008; 135: 837-842.
- 8 Wong M, Yasufuku K, Nakajima T, et al. Endobronchial ultrasound: new insight for the diagnosis of sarcoidosis. *Eur Respir J.* 2007; 29: 1182-1186.
- 9 Kaminski J KJ. Practice of Bronchoscopy in Poland in 2002. *J Bronchol Interv Pulmonol.* 2006; 13: 12-15.
- 10 Judson MA, Thompson BW, Rabin DL, et al. The diagnostic pathway to sarcoidosis. *Chest.* 2003; 123: 406-412.
- 11 Smyth CM, Stead RJ. Survey of flexible fiberoptic bronchoscopy in the United Kingdom. *Eur Respir J.* 2002; 19: 458-463.
- 12 Morales CF, Patefield AJ, Strollo PJ, Schenk DA. Flexible transbronchial needle aspiration in the diagnosis of sarcoidosis. *Chest.* 1994; 106: 709-711.
- 13 Agarwal R, Srinivasan A, Aggarwal AN, Gupta D. Efficacy and safety of convex probe EBUS-TBNA in sarcoidosis: a systematic review and meta-analysis. *Respir Med.* 2012; 106: 883-892.
- 14 Costabel U, Bonella F, Ohshimo S, Guzman J. Diagnostic modalities in sarcoidosis: BAL, EBUS, and PET. *Semin Respir Crit Care Med.* 2010; 31: 404-408.
- 15 Agarwal R, Aggarwal AN, Gupta D. Efficacy and safety of conventional transbronchial needle aspiration in sarcoidosis: a systematic review and meta-analysis. *Respir Care.* 2013; 58: 683-693.
- 16 Fritscher-Ravens A, Ghanbari A, Topalidis T, et al. Granulomatous mediastinal adenopathy: can endoscopic ultrasound-guided fine-needle aspiration differentiate between tuberculosis and sarcoidosis? *Endoscopy.* 2011; 43: 955-961.
- 17 Iwashita T, Yasuda I, Doi S, et al. The yield of endoscopic ultrasound-guided fine needle aspiration for histological diagnosis in patients suspected of stage I sarcoidosis. *Endoscopy.* 2008; 40: 400-405.
- 18 von Bartheld MB, Veselić-Charvat M, Rabe KF, Annema JT. Endoscopic ultrasound-guided fine-needle aspiration for the diagnosis of sarcoidosis. *Endoscopy.* 2010; 42: 213-217.
- 19 Oki M, Saka H, Kitagawa C, et al. Real-time endobronchial ultrasound-guided transbronchial needle aspiration is useful for diagnosing sarcoidosis. *Respirology.* 2007; 12: 863-868.
- 20 Tournoy KG, Bolly A, Aerts JG, et al. The value of endoscopic ultrasound after bronchoscopy to diagnose thoracic sarcoidosis. *Eur Respir J.* 2010; 35: 1329-1335.
- 21 Szlubowski A, Kuzdzal J, Pankowski J, et al. [Ultrasound guided transbronchial needle aspiration as a diagnostic tool for lung cancer and sarcoidosis]. *Pneumonol Alergol Pol.* 2008; 76: 229-236. Polish.

- 22 Tremblay A, Stather DR, Maceachern P, et al. A randomized controlled trial of standard vs endobronchial ultrasonography-guided transbronchial needle aspiration in patients with suspected sarcoidosis. *Chest*. 2009; 136: 340-346.
- 23 Gnass M, Szlubowski A, Soja J, et al. Comparison of conventional and ultrasound-guided needle biopsy techniques in the diagnosis of sarcoidosis: a randomized trial. *Pol Arch Med Wewn*. 2015; 125: 321-328.
- 24 Navani N, Booth HL, Kocjan G, et al. Combination of endobronchial ultrasound-guided transbronchial needle aspiration with standard bronchoscopic techniques for the diagnosis of stage I and stage II pulmonary sarcoidosis. *Respirology*. 2011; 16: 467-472.
- 25 Armstrong JR, Radke JR, Kvale PA, et al. Endoscopic findings in sarcoidosis. Characteristics and correlations with radiographic staging and bronchial mucosal biopsy yield. *Ann Otol Rhinol Laryngol*. 1981; 90: 339-343.
- 26 Ziara D, Jastrzębski D, Labus Ł. [Advances in diagnosis of pulmonary sarcoidosis]. *Pneumonol Alergol Pol*. 2012; 80: 355-364. Polish.
- 27 Soja J, Szlubowski A, Wasowski D, et al. [Transbronchial needle aspiration as a diagnostic method of mediastinal adenopathy]. *Przegl Lek*. 2005; 62: 102-104. Polish.
- 28 Herth F, Becker HD, Ernst A. Conventional vs endobronchial ultrasound-guided transbronchial needle aspiration: a randomized trial. *Chest*. 2004; 125: 322-325.
- 29 Trisolini R, Lazzari Agli L, Cancellieri A, et al. Transbronchial needle aspiration improves the diagnostic yield of bronchoscopy in sarcoidosis. *Sarcoidosis Vasc Diffuse Lung Dis*. 2004; 21: 147-151.
- 30 Oki M, Saka H, Kitagawa C, et al. Prospective study of endobronchial ultrasound-guided transbronchial needle aspiration of lymph nodes versus transbronchial lung biopsy of lung tissue for diagnosis of sarcoidosis. *J Thorac Cardiovasc Surg*. 2012; 143: 1324-1329.
- 31 Halme M, Piilonen A, Taskinen E. Comparison of endobronchial and transbronchial biopsies with high-resolution CT (HRCIT) in the diagnosis of sarcoidosis. *APMIS*. 2001; 109: 289-294.
- 32 Descombes E, Gardiol D, Leuenberger P. Transbronchial lung biopsy: an analysis of 530 cases with reference to the number of samples. *Monaldi Arch Chest Dis*. 1997; 52: 324-329.