

# A diabetic patient with suppurative thyroiditis due to *Salmonella enterica* complicated by acute kidney injury

Aleksandra Hernik<sup>1\*</sup>, Ewelina Szczepanek-Parulska<sup>1\*</sup>, Bogusz Falkowski<sup>1</sup>, Hanna Komarowska<sup>1</sup>, Michał Drews<sup>2</sup>, Marek Ruchala<sup>1</sup>

1 Department of Endocrinology, Metabolism and Internal Medicine, Poznan University of Medical Sciences, Poznań, Poland

2 Department of General, Endocrine and Gastrointestinal Oncological Surgery, Poznan University of Medical Sciences, Poznań, Poland

The incidence of acute bacterial thyroiditis is estimated at 0.1% of thyroid gland conditions requiring surgical treatment. The main pathogen causing acute thyroiditis is *Staphylococcus aureus*, while *Salmonella enterica* is extremely rare.<sup>1</sup>

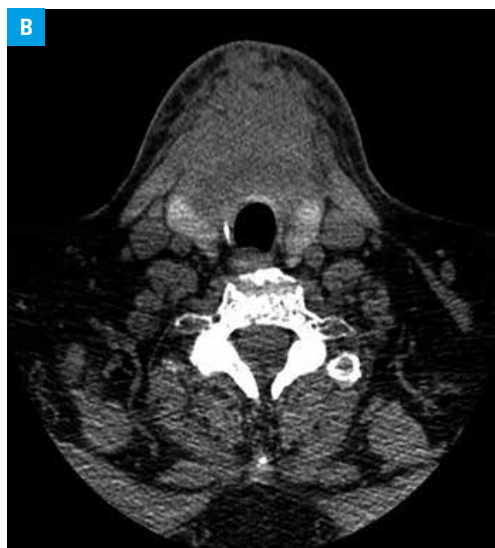
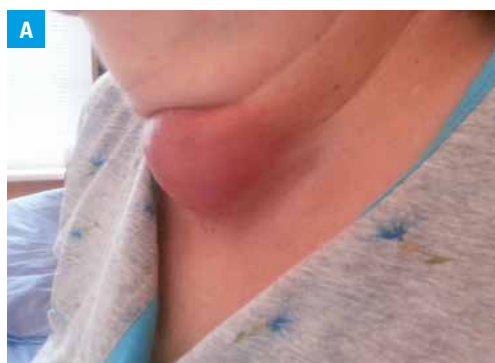A 61-year-old woman presented with sore throat and fever (up to 39.8°C), without cough, rhinitis, or diarrhea. She had obesity (body mass index, 33.3 kg/m<sup>2</sup>), chronic atrial fibrillation treated with acenocoumarol and digoxin, hypertension for the past 14 years (well controlled with ramipril and spironolactone),<sup>2</sup> and well-controlled type 2 diabetes (glycated hemoglobin, 5.5%) for the past 3 years (treated with metformin and gliclazide). Her medical history was negative for thyroid and renal disorders.

Initially, she was consulted by a laryngologist, who performed an ultrasound examination of the neck. It demonstrated a mixed solid and cystic lesion (47 × 40 × 42 mm). Empirical therapy with clindamycin was introduced (600 mg twice daily), and the patient was referred to the department of endocrinology.

On admission, she was weak and dehydrated. She reported a weight loss of 22 kg (from 117 kg to 95 kg) in the previous month. A physical examination revealed restricted, swollen, tender, and painful lesion in the lower part of the neck (FIGURE 1A). Laboratory tests indicated inflammation, acute kidney injury, and hyperthyroidism (Supplementary material online, Table S1). Fine-needle aspiration biopsy (FNAB) of the lesion was performed. A cytological examination revealed the presence of inflammatory cells, while microbiological tests identified *Salmonella enterica* subsp. *enterica* as a pathogenic factor. Blood and stool cultures were both negative for *Salmonella*. Due to acute kidney injury, noncontrast computed tomography of the neck was performed (FIGURE 1B).

During hospitalization, the patient received adequate therapy for acute kidney injury, which was most probably iatrogenic and induced by clindamycin therapy. Intravenous antibiotic

**FIGURE 1** Lesion on the neck found on admission to the hospital; **A** – local erythema and warming of the skin; **B** – a computed tomography scan showing an extensive pathological mass (68 × 65 × 88 mm) characterized by low density and numerous enlarged lymph nodes



Correspondence to: Prof. Marek Ruchala, MD, PhD, Katedra i Klinika Endokrynologii, Przemiany Materii i Chorób Wewnętrznych, Uniwersytet Medyczny im. Karola Marcinkowskiego w Poznaniu, ul. Przybyszewskiego 49, 60-355 Poznań, Poland, phone: +48 61 869 13 30, e-mail: mruchala@ump.edu.pl

Received: January 14, 2017.

Revision accepted:

January 31, 2017.

Published online: February 28, 2017.

Conflict of interests: none declared.

Pol Arch Intern Med. 2017;

127 (2): 131–132

doi:10.20452/pamw.3957

Copyright by Medycyna Praktyczna,

Kraków 2017

\*AH and ES-P contributed equally to

this work.

treatment (ceftazidime, 1 g twice daily) was administered according to antibiogram. Moreover, thiamazole therapy was introduced due to features of hyperthyroidism (40 mg/d). The patient was referred for incision and percutaneous drainage, and 7 days after treatment her clinical condition improved. On discharge (after 11 days of hospitalization), she received a combination therapy with trimethoprim and sulfamethoxazole (at a dose of 960 mg twice daily for 7 days), as well as thiamazole.

An ultrasound performed 3 weeks later in an endocrine clinic revealed a gradual decrease in the maximum depth of the lesion from 68 mm to 25 mm. Eventually, all symptoms resolved. A follow-up ultrasound performed a year later revealed 6 mixed solid and cystic lesions of less than 1 cm in size. All lesions were shown to be benign in a FNAB, and the patient currently remains clinically and biochemically euthyroid.

A literature review revealed only 33 cases of *Salmonella* thyroiditis (Supplementary material online, *Table S2*). Typical infections with *Salmonella* affect the gastrointestinal tract, while atypical infections are possible in conditions associated with compromised immune system (human immunodeficiency virus-positive patients, transplant recipients), diabetes mellitus, thyroid disorders (ie, in nodular goiter as a complication of FNAB), anatomical abnormalities (pyriform sinus fistula), corticosteroid therapy, advanced age, neoplastic disease, and contact with breeding animals.<sup>3-5</sup> The only detected risk factor for the development of acute thyroiditis in our patient was diabetes mellitus, although it was well controlled on 2 medications. Other risk factors were excluded.

**Supplementary material online** Supplementary material online is available with the online version of the article at [www.pamw.pl](http://www.pamw.pl).

## REFERENCES

- 1 Chenguir M, Souldi H, Loufad FZ, et al. Thyroid abscess revealing Graves-Basedow disease: about a case and review of the literature. *Pan Afr Med J*. 2016; 24: 204.
- 2 Brimble KS. Targeting blood pressure in people with diabetes mellitus. *Pol Arch Med Wewn*. 2016; 126: 411-418.
- 3 Ambroziak U, Pachucki J, Bednarczuk T, et al. Suppurative thyroiditis caused by *Salmonella* enteritidis. *Endokrynol Pol*. 2011; 62: 466-470.
- 4 Maraj A, Kiss A, Luvhengo TE. *Salmonella* thyroiditis: a case report and review of the literature. *South Afr J Surg*. 2013; 51: 149-150.
- 5 Swanson SJ, Snider C, Braden CR, et al. Multidrug-resistant *Salmonella* enterica serotype Typhimurium associated with pet rodents. *N Engl J Med*. 2007; 356: 21-28.