

Endosonography-guided treatment of a large infected pseudocyst sustained after posttraumatic acute pancreatitis in a critically ill patient

Łukasz Krupa¹, Joanna Lorenc¹, Robert Staroń¹, Mariusz Partyka^{1,2},
Łukasz Chmielarz³, Krzysztof Gutkowski^{1,2}

¹ Department of Gastroenterology and Hepatology with the Internal Diseases Unit, Teaching Hospital No. 1, Rzeszów, Poland

² Faculty of Medicine, University of Rzeszów, Rzeszów, Poland

³ Department of Radiology, Teaching Hospital No. 1, Rzeszów, Poland

A 54-year-old patient with a history of posttraumatic pancreatitis complicated by a large infected pancreatic pseudocyst was transferred to our department. A severe systemic inflammatory response was a contraindication to surgical drainage, and once the patient was stabilized in the intensive care unit, a decision was made to attempt endosonography (EUS)-guided drainage.

Contrast-enhanced abdominal computed tomography revealed a large fluid collection extending from the pancreatic tail to the mediastinum (FIGURE 1A). EUS-guided cystogastrostomy was performed, using a single-step Hot AXIOS stent, which created a tract and anastomosis between

the lumen of the stomach and infected pseudocyst. The procedure was performed under conscious sedation. Successful drainage of pus was achieved.

Unfortunately, after 24 hours the stent migrated into the lumen of the cyst, which was confirmed by control gastroscopy. As a rescue treatment, we performed another EUS-guided cystogastrostomy, using a 3-cm fully covered, self-expanding metal stent (Hannarostent) with further drainage of purulent material (FIGURE 1B).

The patient went on to make an uneventful recovery and was discharged from the hospital 7 days after the procedure. He was readmitted

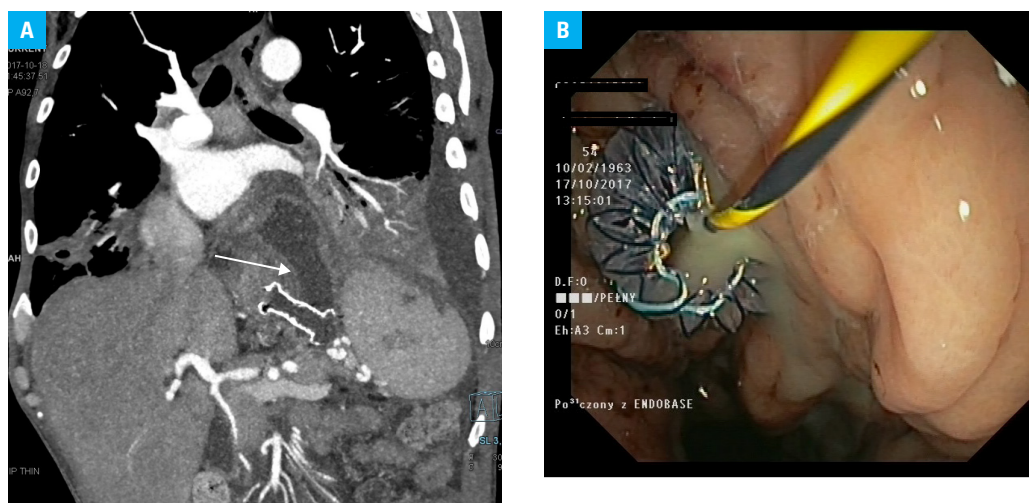
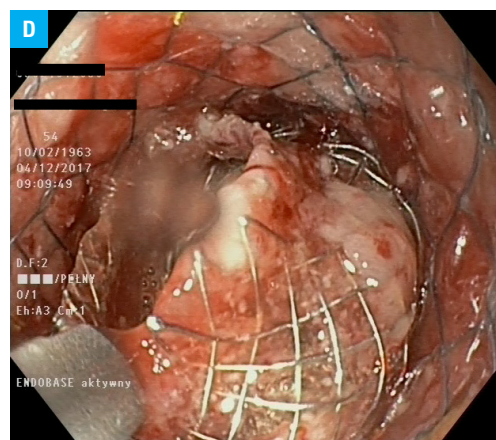
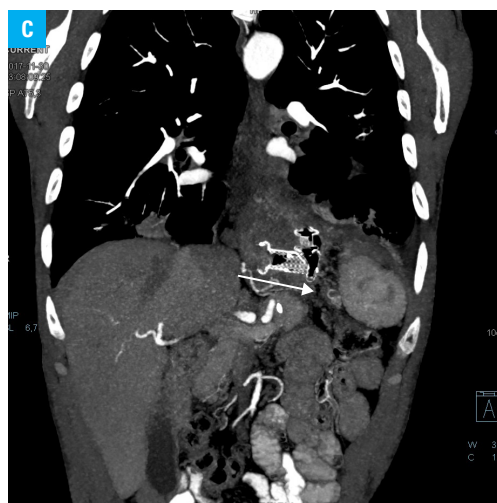


FIGURE 1 **A** – contrast-enhanced computed tomography scan of the abdomen: large fluid collection extending from the pancreatic tail to the mediastinum (arrow); **B** – endosonography-guided cystogastrostomy using a fully covered, self-expanding metal stent with very good drainage of purulent content

Correspondence to:
Robert Staroń, MD, Klinika Gastroenterologii i Hepatologii z Pododdziałem Chorób Wewnętrznych, Kliniczny Szpital Wojewódzki nr 1 w Rzeszowie, ul. Chopina 2, 35-055 Rzeszów, Poland, phone: +48 17 866 61 31, email: rob.staron@gmail.com
Received: March 12, 2018.
Revision accepted: April 17, 2018.
Published online: April 17, 2018.
Conflict of interest: none declared.
Pol Arch Intern Med. 2018; 128 (5): 317-318
doi:10.20452/pamw.4248
Copyright by Medycyna Praktyczna, Kraków 2018

FIGURE 1 C – control interval computed tomography revealed near-complete cyst resolution (arrow); **D** – endoscopic removal of both stents; the proximal part visible in the stomach lumen



a month later for reassessment and when an interval CT revealed near-complete cyst resolution (**FIGURE 1C**). Both stents were endoscopically removed with the forceps for stent retrieval (**FIGURE 1D**). The patient remains well after 6 months of follow-up.

EUS-guided drainage of pancreatic pseudocysts is a well-established treatment modality.¹ We demonstrated that this method can be successful in patients with significant systemic inflammatory response and provides an approach to the management of stent migration. The technical success of EUS-guided gastrocystostomy is over 95%, with a clinical success of 90% and the rate of procedure-related complications of approximately 5% (most commonly bleeding, perforation, and aspiration pneumonia).¹ Compared with conventional endoscopic drainage, EUS-guided drainage has superior clinical and technical success rates and a significantly better safety profile.¹⁻³ Moreover, in severely ill patients, this technique was shown to have a better treatment success and decreased mortality and morbidity rates compared with open pseudocyst gastrostomy.^{4,5} The mean length of hospital stay was significantly shorter for EUS-guided pseudocyst drainage.⁵ The procedure requires advanced endoscopic skills and should be performed only in expert endoscopy centers.

OPEN ACCESS This is an Open Access article distributed under the terms of the Creative Commons Attribution-NonCommercial-ShareAlike 4.0 International License ([CC BY-NC-SA 4.0](https://creativecommons.org/licenses/by-nc-sa/4.0/)), allowing third parties to copy and redistribute the material in any medium or format and to remix, transform, and build upon the material, provided the original work is properly cited, distributed under the same license, and used for non-commercial purposes only. For commercial use, please contact the journal office at pamw@mp.pl.

REFERENCES

1 Wang K, Zhu J, Xing L, et al. Assessment of efficacy and safety of EUS-guided biliary drainage: a systematic review. *Gastrointest Endosc.* 2016; 83: 1218-1227. [↗](#)

2 Ng PY, Rasmussen DN, Vilmann P, et al. Endoscopic ultrasound-guided drainage of pancreatic pseudocysts: medium-term assessment of outcomes and complications. *Endosc Ultrasound.* 2013; 2: 199-203.

3 Kahaleh M, Shami VM, Conaway MR, et al. Endoscopic ultrasound drainage of pancreatic pseudocyst: a prospective comparison with conventional endoscopic drainage. *Endoscopy.* 2006; 38: 355-359.

4 Varadarajulu S, Lopes TL, Wilcox CM, et al. EUS versus surgical cyst-gastrostomy for management of pancreatic pseudocysts. *Gastrointest Endosc.* 2008; 68: 649-655.

5 Varadarajulu S, Bang JY, Sutton BS, et al. Equal efficacy of endoscopic and surgical cystogastrostomy for pancreatic pseudocyst drainage in a randomized trial. *Gastroenterology.* 2013; 145: 583-590.