

Pneumothorax in a young nonsmoking patient: a manifestation of Langerhans cell histiocytosis

Emilia Borowska¹, Elżbieta Radzikowska², Beata Maksymiuk³, Lila Jakubowska⁴

1 Mazovia Centre for Treatment of Lung Diseases and Tuberculosis, Otwock, Poland

2 3rd Department of Lung Diseases, National Tuberculosis and Lung Diseases Research Institute, Warsaw, Poland

3 Pathology Department, National Tuberculosis and Lung Diseases Research Institute, Warsaw, Poland

4 Radiology Department, National Tuberculosis and Lung Diseases Research Institute, Warsaw, Poland

A 15-year-old medium-height male patient was admitted to the thoracic surgery department with a right-sided pneumothorax with persistent air leak. He was a nonsmoker and had not been exposed to pneumotoxic factors. One month earlier, he developed right-sided chest pain, and pneumothorax was diagnosed in a district hospital. Positional therapy was started, but subsequently drainage of the right pleural cavity was implemented, initially passively and then actively. This treatment was ineffective, and the patient was referred to our hospital.

On admission, he was in good condition. Laboratory blood and urine tests were normal. Chest x-ray showed right-sided pneumothorax with a partially collapsed right lung. He underwent video-assisted thoracoscopy, and a small bulla in the right upper lobe was resected. The lung

re-expanded, and the chest tube was removed 2 days later. Histological examination of the lung sample revealed an infiltration consisting of large cells with folded nuclei, forming granulomas (FIGURE 1A). These cells were positive for langerin (FIGURE 1B) and CD1a antigen (FIGURE 1C), but negative for *BRAF*^{V600E}, which led us to establish a diagnosis of Langerhans cell histiocytosis (LCH). High-resolution computed tomography (HRCT) showed a few small nodules at the base of the right upper lobe (FIGURE 1D). Pulmonary function tests and 6-minute walk test were normal (forced expiratory volume in 1 second, 89% pred.; forced vital capacity, 108% pred.; total lung capacity, 88% pred.), while the transfer factor for carbon monoxide was reduced (69% pred.). Computed tomography did not show any osteolytic lesions, and there were no changes on abdominal

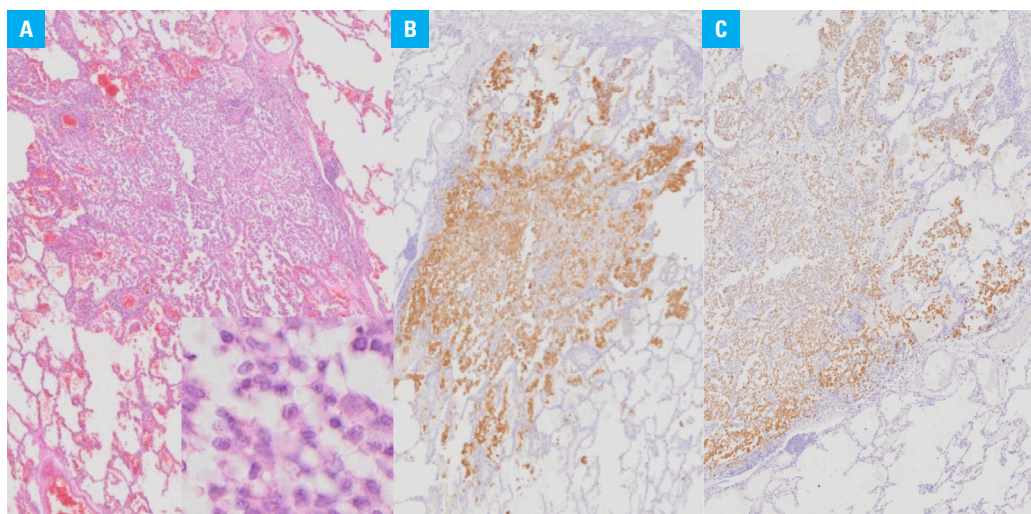


FIGURE 1 Langerhans cell histiocytosis on histological examination: **A** – low and high magnification view showing discrete nodular infiltration within lung parenchyma by large histiocytes with folded nuclei (hematoxylin and eosin staining; magnification, ×100 and ×200). **B, C** – immunohistochemistry for langerin (**B**) and CD1a (**C**), demonstrating strong positive staining in Langerhans cells (magnification, ×100)

Correspondence to:

Elżbieta Radzikowska, MD, PhD,
National Tuberculosis and Lung
Diseases Research Institute,
ul. Płocka 26, 01-138 Warszawa,
Poland, phone: +48 22 431 22 29,
email: e.radzikowska@wpi.pl

Received: August 8, 2018.

Revision accepted:

September 20, 2018.

Published online:

September 20, 2018.

Conflict of interest: none declared.

Pol Arch Intern Med. 2018;

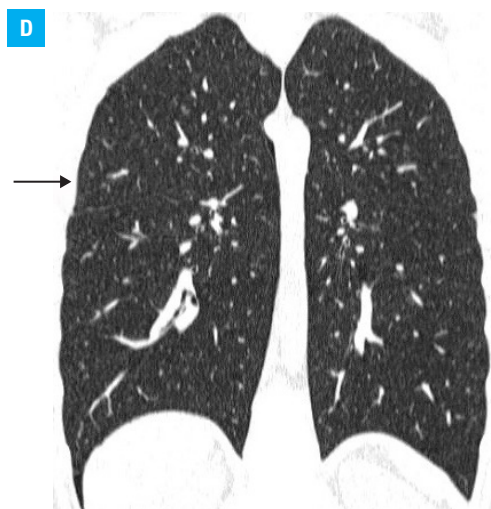
128 (10): 619-620

doi:10.20452/pamw.4335

Copyright by Medycyna Praktyczna,

Kraków 2018

FIGURE 1 Langerhans cell histiocytosis on high-resolution computed tomography scan: **D** – small nonspecific nodules at the base of the upper lobe of the right lung (arrow)



ultrasound or brain magnetic resonance imaging. HRCT performed a year later revealed complete regression of the nodules. No progression has been observed during the 5-year follow-up.

Spontaneous pneumothorax is caused by intrinsic factors. Primary spontaneous pneumothorax occurs in patients without a history of pulmonary disease, while secondary spontaneous pneumothorax is observed in patients with underlying diseases.¹ The rupture of a small subpleural cyst is the most common cause of primary spontaneous pneumothorax. The incidence of this condition is 18 to 24/100 000 in men and 6 to 9.8/100 000 in women. The peak incidence is at 15 to 34 years of age.¹ Risk factors include smoking, tall stature, and low body mass. Diseases that can cause secondary pneumothorax include chronic obstructive pulmonary disease, emphysema, lung abscess, tuberculosis, pneumonia, lymphangioleiomyomatosis, lymphoid interstitial pneumonia, Birt-Hogg-Dubé syndrome, alpha-1 antitrypsin deficiency, or pulmonary LCH (PLCH).¹⁻⁵

PLCH is a rare disease, which usually affects young people and smokers. LCH may be limited to the lungs, or the lungs may be one of the involved organs, both at the time of diagnosis and during follow-up. Pneumothorax is the first sign of PLCH in about 30% of cases. HRCT is important in the diagnosis of PLCH. The radiographic changes range from small intralobular nodules to cystic lesions with sparing of the costophrenic angles.²⁻⁵ To our knowledge, this is the first case of PLCH in a nonsmoker with such minimal lesions. The absence of obvious radiographic evidence of lung disease does not exclude the need for lung biopsy in patients undergoing surgical treatment of pneumothorax. It is essential to implement measures aimed at inhibiting the progression of the disease, especially smoking cessation.

OPEN ACCESS This is an Open Access article distributed under the terms of the Creative Commons Attribution-NonCommercial-ShareAlike 4.0 International License ([CC BY-NC-SA 4.0](https://creativecommons.org/licenses/by-nc-sa/4.0/)), allowing third parties to copy and redistribute the material in any medium or format and to

remix, transform, and build upon the material, provided the original work is properly cited, distributed under the same license, and used for non-commercial purposes only. For commercial use, please contact the journal office at pamw@mp.pl.

REFERENCES

- 1 Tschopp J.M, Bintcliffe O, Astoul P, et al. ERS task force statement: diagnosis and treatment of primary spontaneous pneumothorax. *Eur Respir J*. 2015; 46: 321-335.
- 2 Odame I, Li P, Lau L, et al. Pulmonary Langerhans cell histiocytosis: a variable disease in childhood. *Pediatr Blood Cancer*. 2006; 47: 889-893.
- 3 Girschikofsky M, Arico M, Castillo D, et al. Management of adult patients with Langerhans cell histiocytosis: recommendations from an expert panel on behalf of Euro-Histio-Net. *Orphanet J Rare Dis*. 2013; 8: 1-11.
- 4 Mendez JL, Nadrous HF, Vassallo R, et al. Pneumothorax in pulmonary Langerhans cell histiocytosis. *Chest*. 2004; 125: 1028-1032.
- 5 Radzikowska E. Pulmonary Langerhans cell histiocytosis in adults. *Adv Respir Med*. 2017; 85: 277-289.