

Supplementary material

Bańka P, Bednarek A, Grabka M, et al. A large amount of pericardial fluid: determining consecutive steps in the diagnosis and treatment of pulmonary arterial hypertension. *Pol Arch Intern Med.* 2020; 130: 539-540. doi:10.20452/pamw.15232

Please note that the journal is not responsible for the scientific accuracy or functionality of any supplementary material submitted by the authors. Any queries (except missing content) should be directed to the corresponding author of the article.

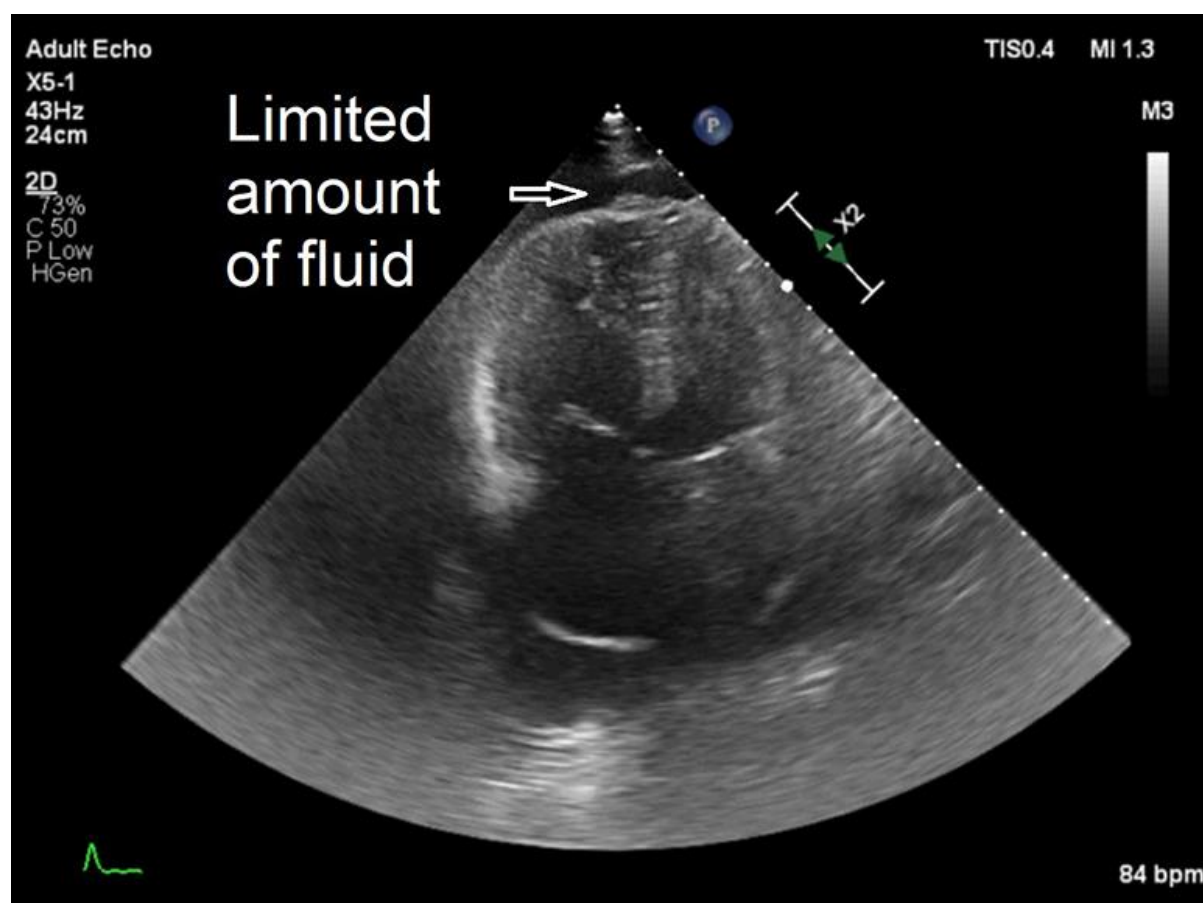


Figure S1

Echocardiography at admission: a nonhomogeneous distribution of effusion with a limited amount of fluid around the apex of the heart