

Supplementary material

Warchoł I, Dębska-Kozłowska A, Karcz-Socha I, et al. Terra incognita: clinically suspected myocarditis in a patient with severe acute respiratory syndrome coronavirus 2 infection. *Pol Arch Intern Med.* 2020; 130: 446-448. doi:10.20452/pamw.15309

Please note that the journal is not responsible for the scientific accuracy or functionality of any supplementary material submitted by the authors. Any queries (except missing content) should be directed to the corresponding author of the article.

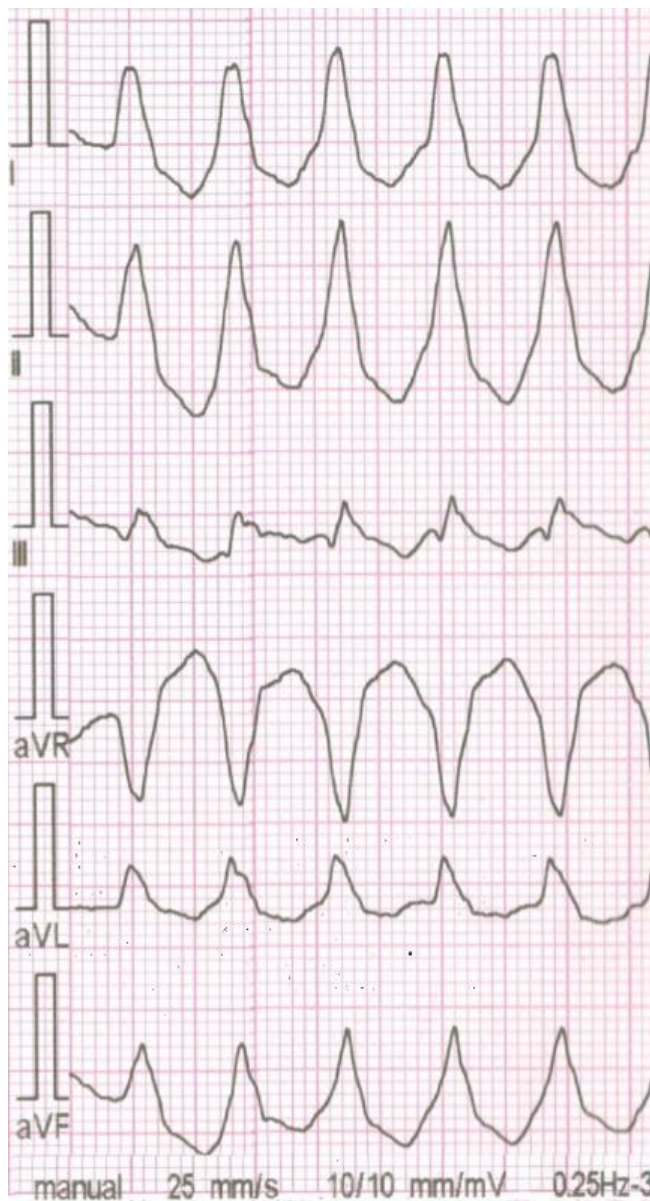


Figure S1A. Ventricular tachycardia. The 12-lead ECG. 3 bipolar and 3 unipolar limb leads.

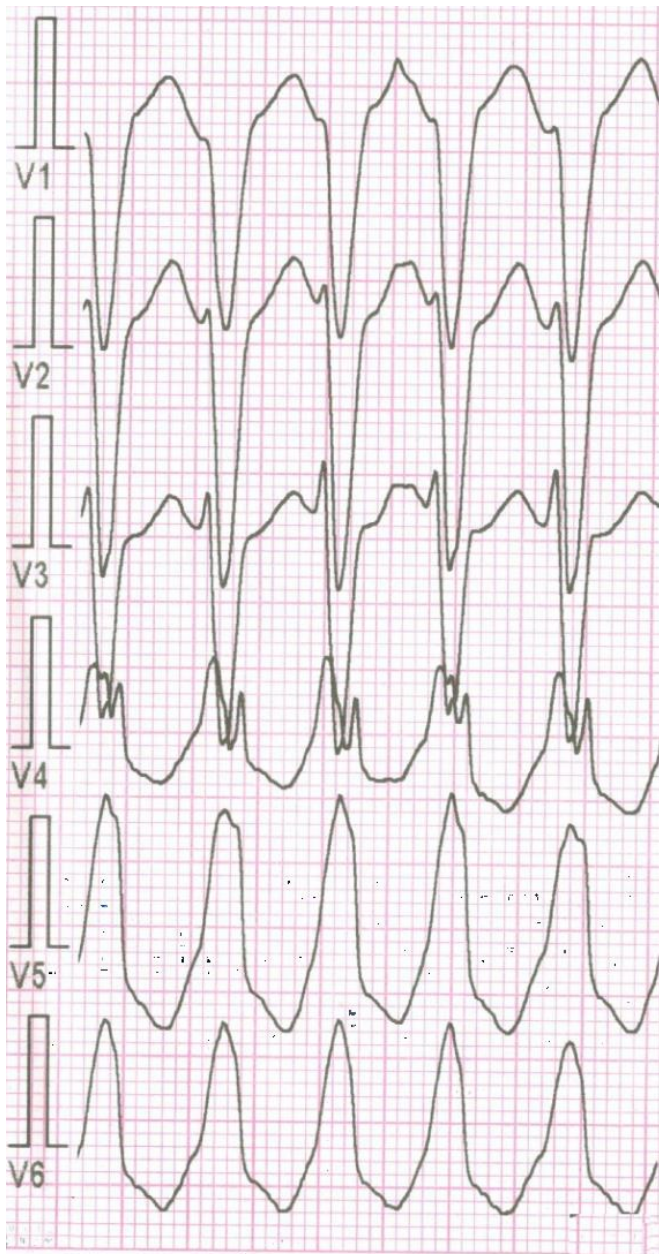


Figure S1B. Ventricular tachycardia. The 12-lead ECG. 6 precordial leads.