

Supplementary material

Klekowski J, Gajdzis P, Podgajny Z, Chabowski M. Incidental finding of diffuse malignant mesothelioma in the greater omentum during the diagnostic workup of a lung tumor. *Pol Arch Intern Med.* 2021; 131: 16106. doi:10.20452/pamw.16106

Please note that the journal is not responsible for the scientific accuracy or functionality of any supplementary material submitted by the authors. Any queries (except missing content) should be directed to the corresponding author of the article.

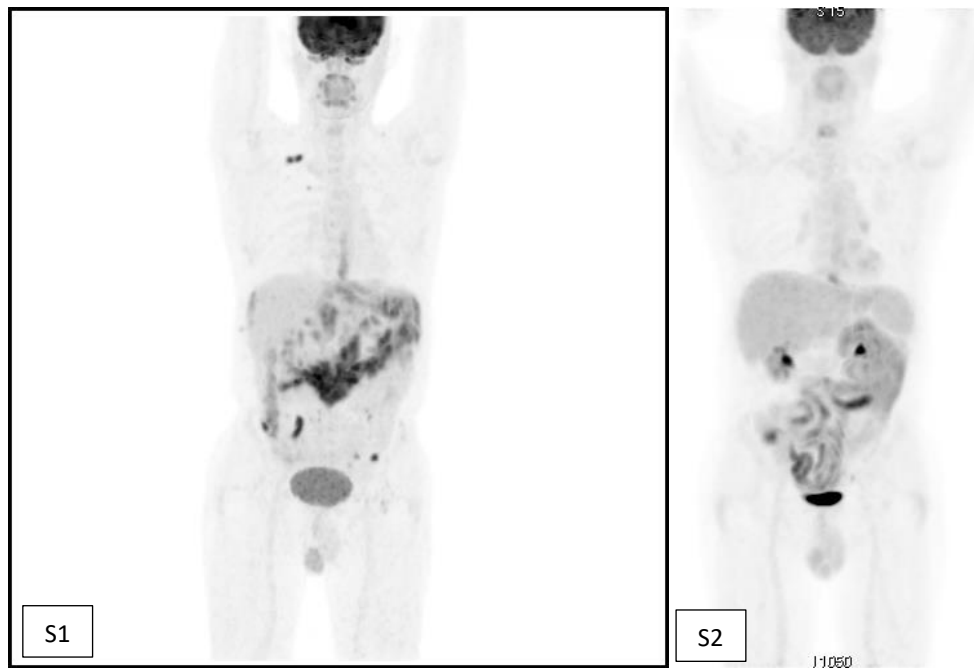


Figure S1. Before treatment - multiple lesions in the peritoneal cavity, metastatic right subclavian lymph nodes
Figure S2. After treatment - residual lesions in the left upper quadrant, visible intestinal activity

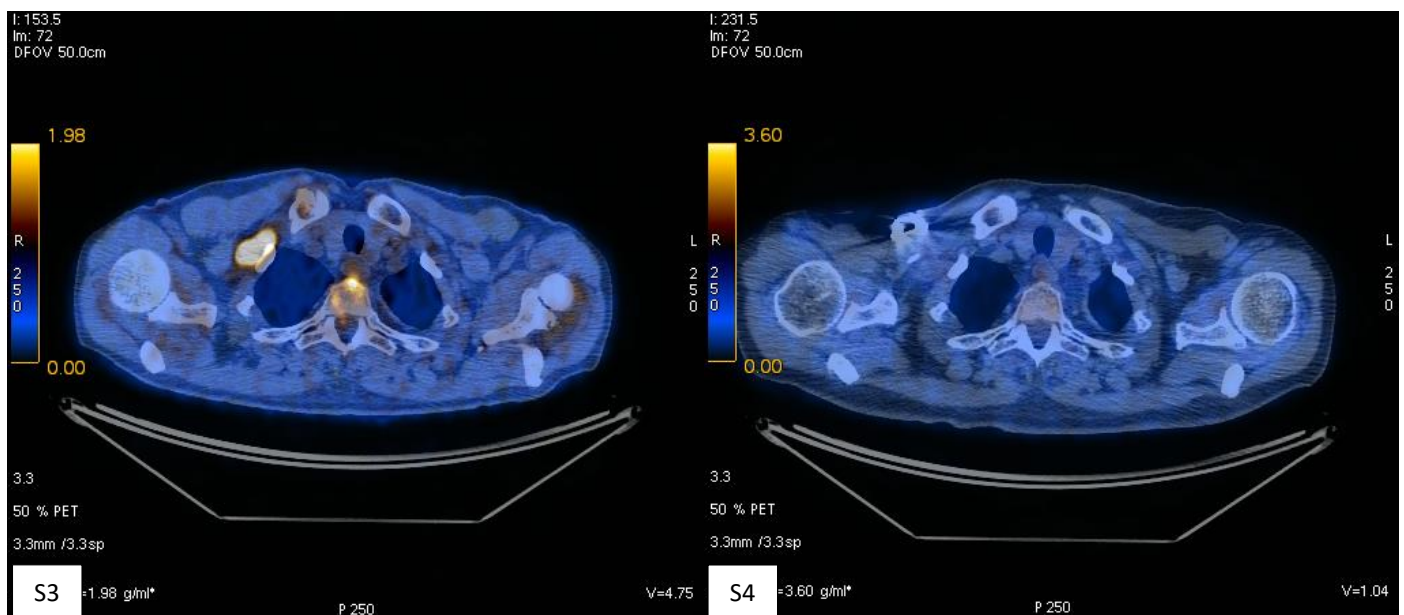


Figure S3. Before treatment - right subclavian lymph nodes

Figure S4. After treatment - right subclavian lymph nodes; full metabolic response

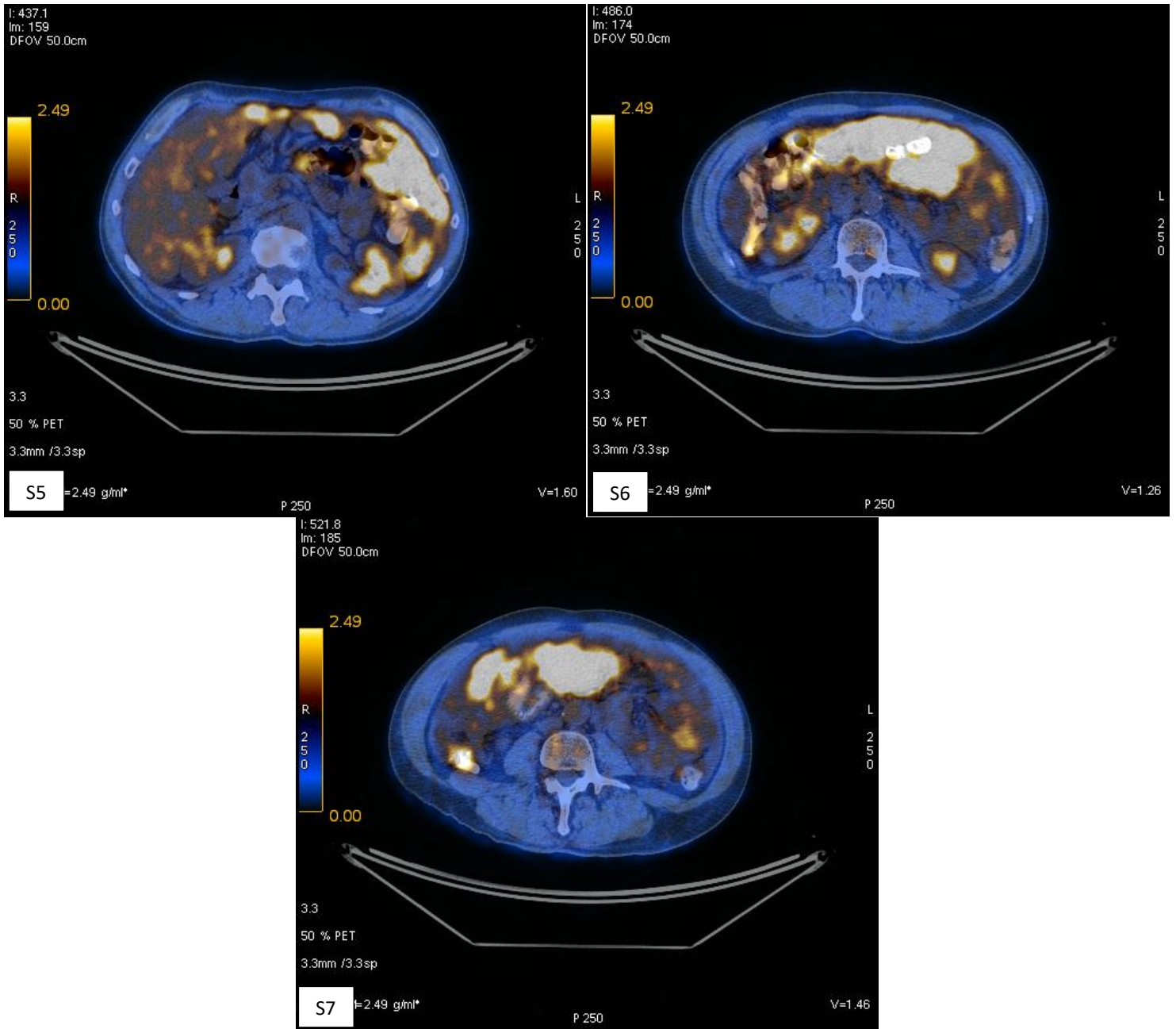


Figure S5-S7. Before treatment - abdominal lesions

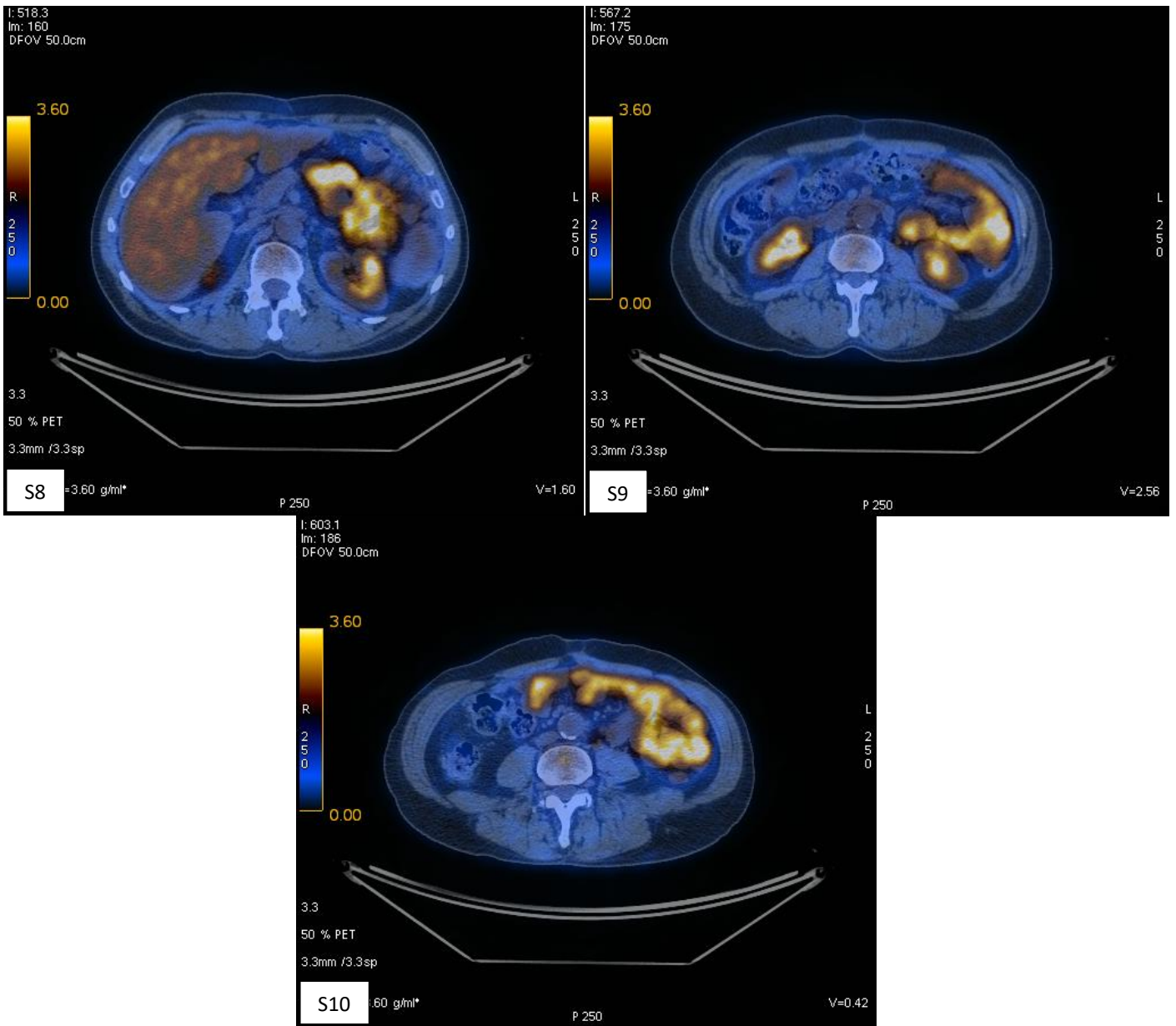


Figure S8-S10. After treatment - residual lesions max 14mm

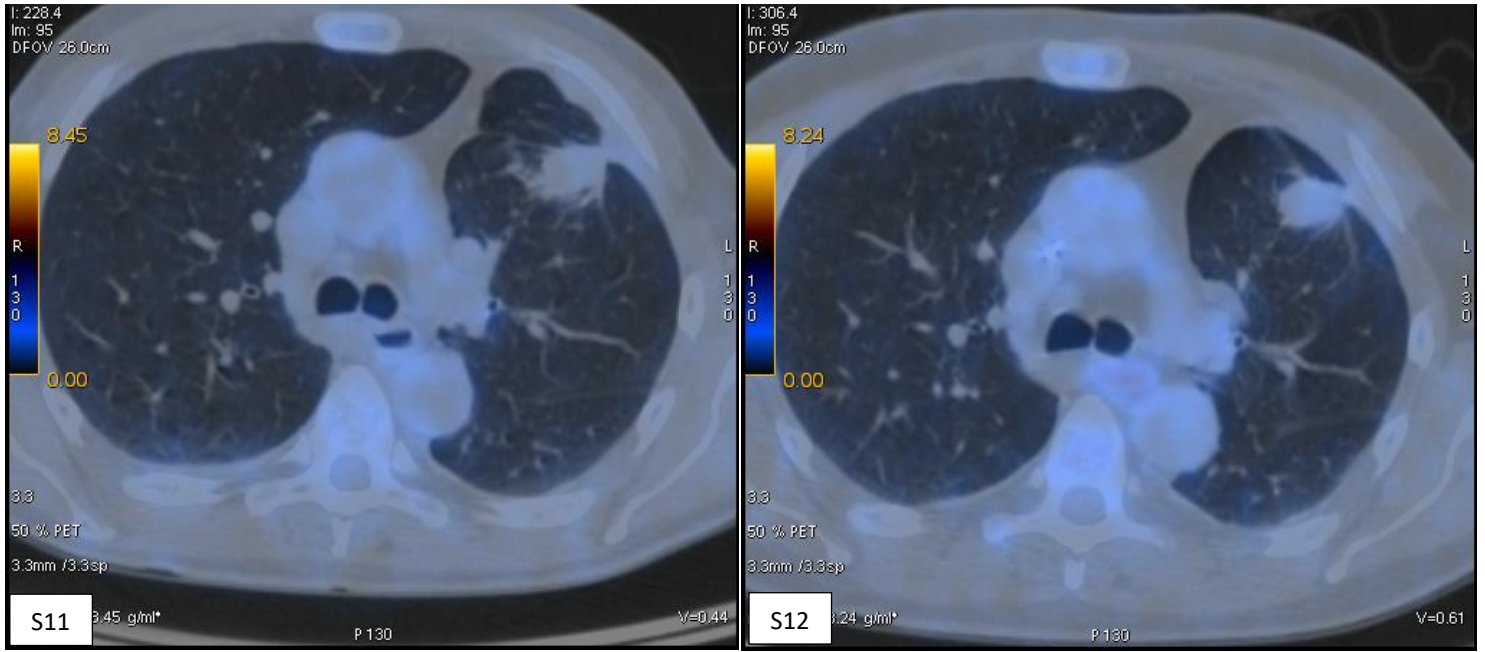


Figure S11. Before treatment - lung tumor; no metabolic signs of malignancy

Figure S12. After treatment - lung tumor; stable lesion - probably post-inflammatory