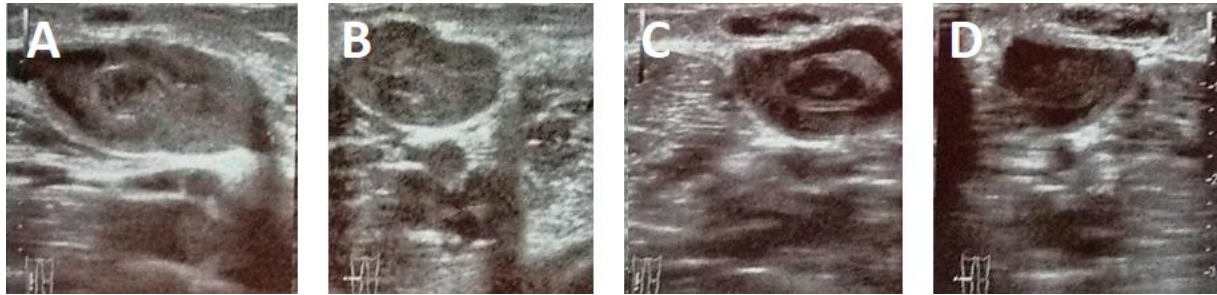


Supplementary material

Szmyd B, Jekimov R, Wysiadecki G, et al. Clinical image of short saphenous varicose vein mimicking neuroma. Pol Arch Intern Med. 2022; 132: 16215. doi:10.20452/pamw.16215

Please note that the journal is not responsible for the scientific accuracy or functionality of any supplementary material submitted by the authors. Any queries (except missing content) should be directed to the corresponding author of the article.



Supplementary Figure S1. A, B, C, D The ultrasonographical examination of left lower limb's vessels.