

Supplementary material

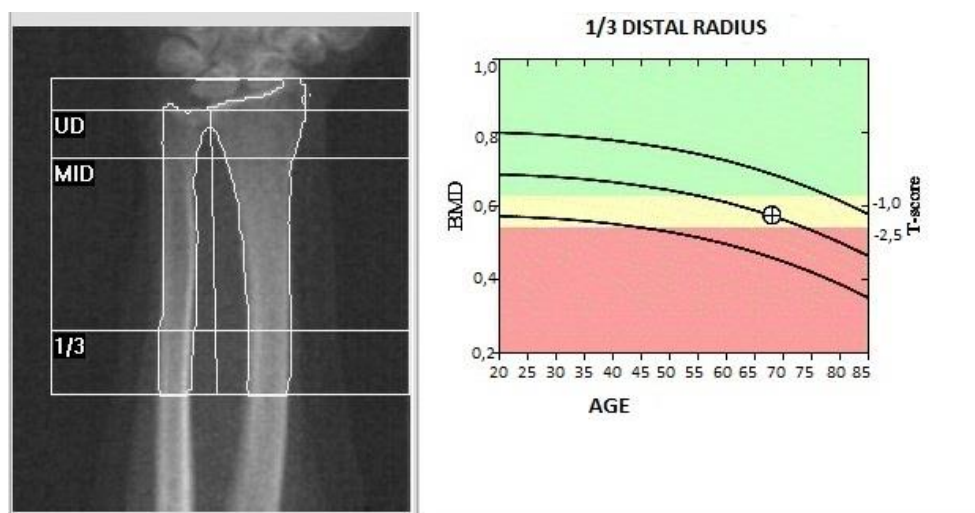
Nowakowska-Płaza A, Płaza M, Sudół-Szopińska I, Głuszko P. Usefulness of trabecular bone score in a misdiagnosed case of osteoporosis: clinical image of a woman with multiple fractures. *Pol Arch Intern Med.* 2020; 130: 150-152. doi:10.20452/pamw.15126

Please note that the journal is not responsible for the scientific accuracy or functionality of any supplementary material submitted by the authors. Any queries (except missing content) should be directed to the corresponding author of the article.

Figure S1

Report of 1/3 distal radius of the non-dominant forearm dual X-ray absorptiometry

T-score value of (-1.9) indicates osteopenia.



Region	BMD [g/cm ²]	T-score
1/3 distal radius	0.573	-1.9