Transarterial chemoembolization with radioactive seed implantation for multitumor hepatocellular carcinoma

Fu-Lei Gao[1*], Zhe Su[2*], Dong-Kai Chen[3], Xiang-Zhong Huang[1], Gao-Lei Ma[4]

1 Department of Interventional Radiology, Jiangyin Hospital Affiliated to Nantong University, Jiangyin, China
2 Department of Gastroenterology, Jiangyin Hospital Affiliated to Nantong University, Jiangyin, China
3 Department of Radiology, Binzhou People's Hospital, Binzhou, China
4 Department of Oncology, Xuzhou First People's Hospital, Xuzhou, China

KEY WORDS

hepatocellular carcinoma, multitumor, radioactive seeds, transarterial chemoembolization

ABSTRACT

INTRODUCTION Transarterial chemoembolization (TACE) combined with radioactive seed implantation has emerged as an effective locoregional strategy for treating hepatocellular carcinoma (HCC). Nevertheless, evidence supporting the use of this combined approach in patients with multitumor HCC remains limited.

AIM We aimed to evaluate the effectiveness and safety of TACE in combination with radioactive seed implantation for multitumor HCC.

MATERIALS AND METHODS This retrospective study analyzed consecutive patients with multitumor HCC who underwent TACE with or without radioactive seed implantation at our institutions between January 2022 and December 2024. Clinical data, therapeutic responses, long-term outcomes, and treatment-related adverse events were collected and compared between the 2 cohorts.

RESULTS A total of 120 individuals were enrolled, of whom 59 were treated with TACE alone, and 61 with TACE combined with radioactive seed implantation. The 2 groups were comparable in terms of demographics and clinical characteristics at baseline. As compared with TACE monotherapy, the combined treatment group demonstrated better total response rate (49.2% vs 30.5%; $P = 0.04$), objective response rate (83.6% vs 61%; $P = 0.01$), progression-free survival (PFS; 14 vs 11 mo; $P = 0.001$), and overall survival (OS; 24 vs 20 mo; $P = 0.02$). The multivariable analysis showed that the combined treatment was independently predictive of better PFS and OS. Adverse event incidence was comparable between the groups.

CONCLUSIONS In comparison with TACE alone, TACE combined with radioactive seed implantation significantly enhances treatment efficacy without compromising safety in patients with multitumor HCC.

Correspondence to:
Gao-Lei Ma, MD, Department of Oncology, Xuzhou First People's Hospital, 269 Daxue Road, 221002 Xuzhou, China, phone: +86 051 685803289, email: mgaolei@126.com
Received: December 20, 2025.
Revision accepted: February 2, 2026.
Published online: February 9, 2026.
Wideochir Inne Tech Maloinwazyjne. 2026; 21 (1): 78-84
doi:10.20452/wiitm.2026.18015
Copyright by the Author(s), 2026

*F-LG and ZS contributed equally to this work.

INTRODUCTION Hepatocellular carcinoma (HCC) has high mortality rates.[1-3] While surgical resection and liver transplantation represent the preferred curative choices, fewer than 30% of the patients are eligible for surgical intervention at the time of diagnosis.[4] In addition, the widespread application of liver transplantation is constrained by donor organ shortages.[5]

Approximately 35%–40% of the patients with HCC present with multiple tumors, and this subgroup has a reported 5-year overall survival (OS) of only 19.5%.[6,7] Transarterial chemoembolization (TACE) remains a standard approach for managing unresectable multitumor HCC.[8,9] To further improve the therapeutic effectiveness of TACE, several adjunctive locoregional therapies, such as percutaneous ablation and radioactive seed implantation, have been introduced.[10,11] However, the simultaneous ablation of multiple lesions is often poorly tolerated in patients with multitumor disease.[6] Moreover, tumors located adjacent to critical organs may be unsuitable for ablative procedures due to safety concerns.[12]

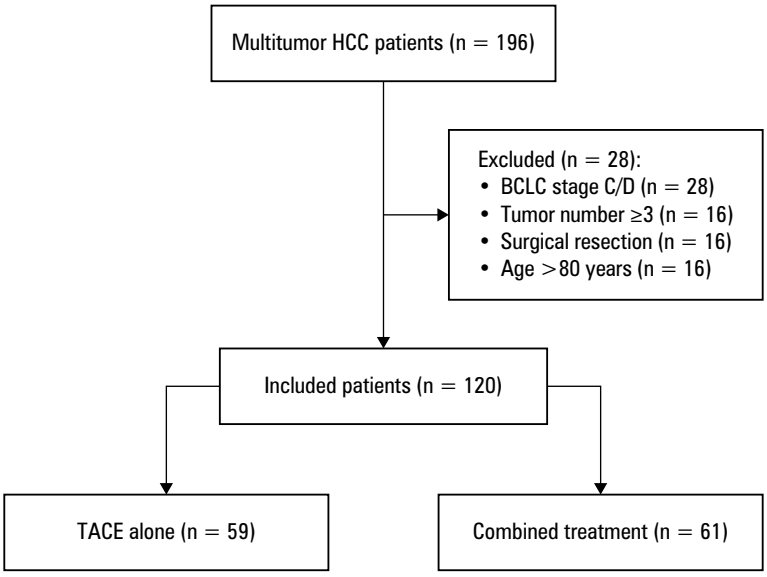

FIGURE 1 Flowchart of the study

Abbreviations: BCLC, Barcelona Clinic Liver Cancer; HCC, hepatocellular carcinoma; TACE, transarterial chemoembolization

In comparison with ablation, radioactive seed implantation offers several advantages, such as improved patient tolerance, fewer anatomical limitations related to tumor location, and sustained local radiation delivery. Despite these benefits, studies specifically investigating the role of TACE combined with radioactive seed implantation in multitumor HCC remain scarce.

AIM This study investigated the effectiveness and safety of TACE used together with radioactive seed implantation in individuals with multitumor HCC.

MATERIALS AND METHODS **Study description** The study was approved by the Ethics Committees of Jiangyin Hospital Affiliated with Nantong University (2023–002) and the Xuzhou First People's Hospital (Xyyll-2025-198). Given the retrospective study design, written informed consent requirements were waived.

Consecutive patients with multitumor HCC who underwent either TACE alone or TACE combined with radioactive seed implantation between January 2022 and December 2024 at our institutions were enrolled. The treatment options were decided based on the patients' economic conditions. Inclusion criteria comprised: 1) unresectable HCC or refusal of surgical resection; 2) presence of 2 tumors; and 3) Barcelona Clinic Liver Cancer (BCLC) stage below C. Patients were excluded if they had concurrent malignancies, were aged over 80 years, or had undergone prior anticancer therapy.

HCC diagnosis followed the American Association for the Study of Liver Diseases guidelines.[13] Baseline features, treatment response, survival, and adverse events were systematically collected and analyzed.

Transarterial chemoembolization procedures Fluoroscopically guided TACE was conducted under local anesthesia, advancing a 5F catheter (Terumo, Tokyo, Japan) into the celiac artery, and angiography facilitated tumor-feeding vessel identification. Subsequently, a 2.7F microcatheter (Terumo) was selectively inserted into the arterial supply of each tumor. A chemotherapeutic emulsion consisting of 5-fluorouracil (150 mg), mitomycin (10 mg), epirubicin (50 mg), and lipiodol (10–20 ml) was administered. All target lesions were treated during a single session. Upon completion, angiography was performed using a 5F catheter to confirm embolization success.

Radioactive seed placement A treatment planning system (TPS; Fei-Tan, Beijing, China) was used to import images acquired during abdominal computed tomography (CT). The optimal number, distribution, and spatial arrangement of the radioactive seeds (^{125}I seeds; length, 4.5 mm; diameter, 0.8 mm; activity, 0.6–0.8 mCi; and half-life, 59.6 d) were calculated. Radioactive seed implantation was usually conducted within a maximum of 14 days of TACE, under CT guidance. Puncture sites, patient positioning, and needle trajectories were determined based on TPS-generated plans. Multiple 18G needles (XinKe Pharmaceutical Ltd., Shanghai, China) were inserted into the target lesions, and radioactive seeds were deployed at intervals of 5–10 mm along the needle tracks. After seed placement, the needles were withdrawn, leaving the seeds in situ. All target tumors were treated in a single implantation session.

Assessment Follow-up assessments were conducted at 1 and 3 months, and subsequently every 3 months, with the final follow-up on June 30, 2025. These assessments involved physical examinations, laboratory workup (liver and renal function, electrolytes, and α-fetoprotein), and imaging studies. Repeat TACE was performed if tumor recurrence or residue was detected on contrast--enhanced CT or magnetic resonance imaging, with treatment response assessed using the Modified Response Evaluation Criteria in Solid Tumors criteria.[14] Complete response was defined as disappearance of any intratumoural arterial enhancement in all typical intrahepatic target lesions, and disappearance of all atypical intrahepatic target lesions and extrahepatic target lesions.[14] Partial response was defined as at least a 30% decrease in the sum of diameters of the target lesions, taking as reference the baseline sum of the longest diameters.[14] Objective response was understood as the total number of cases with complete and partial responses. Progression-free survival (PFS) was defined as the time between treatment initiation and disease progression, death, or last follow-up, while OS was determined as the time between first treatment and death or last follow-up. The grading of adverse events followed the National Cancer Institute Common Terminology Criteria for Adverse Events, version 5.0.[15]

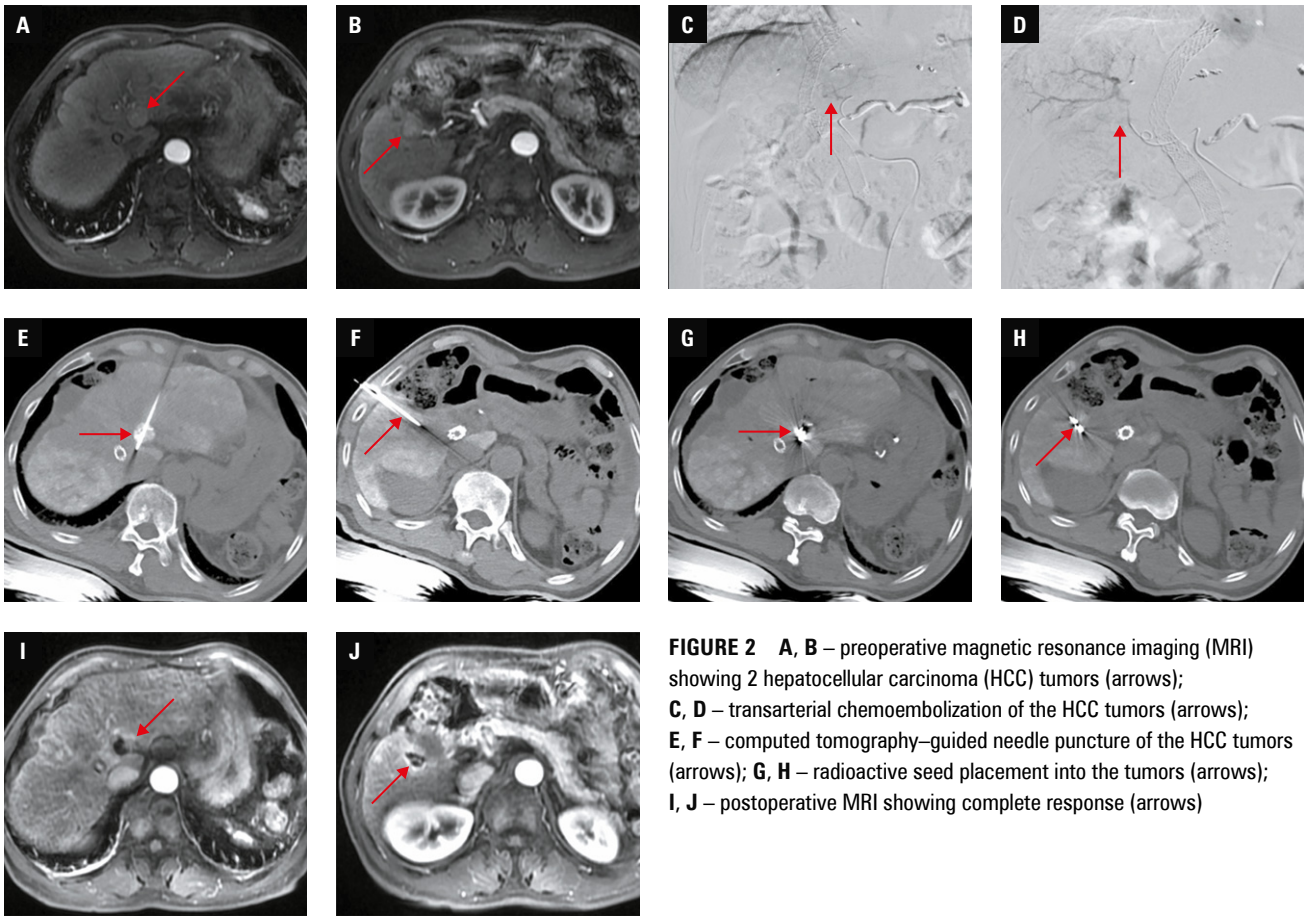

FIGURE 2 **A**, **B** – preoperative magnetic resonance imaging (MRI) showing 2 hepatocellular carcinoma (HCC) tumors (arrows); **C**, **D** – transarterial chemoembolization of the HCC tumors (arrows); **E**, **F** – computed tomography–guided needle puncture of the HCC tumors (arrows); **G**, **H** – radioactive seed placement into the tumors (arrows); **I**, **J** – postoperative MRI showing complete response (arrows)

TABLE 1 Baseline characteristics of the patients

Characteristic		TACE alone (n = 59)	Combined treatment (n = 61)	*P* value
Age, y, mean (SD)		61.8 (8.6)	60.5 (6.6)	0.36
Sex	Men	45 (76.3)	49 (80.3)	0.59
	Women	14 (23.7)	12 (19.7)	
Hepatitis type	None	4 (6.8)	12 (19.7)	0.09
	B	45 (76.3)	37 (60.6)	
	C	10 (16.9)	12 (19.7)	
Child–Pugh grade	A	45 (76.3)	48 (78.7)	0.75
	B	14 (23.7)	13 (21.3)	
BCLC stage	A	24 (40.7)	20 (32.8)	0.37
	B	35 (59.3)	41 (67.2)	
ECOG score	0	30 (50.8)	32 (52.5)	0.86
	1	29 (49.2)	29 (47.5)	
AFP, ng/ml, median (IQR)		122.5 (10.8–442.2)	191.2 (28.7–301.3)	0.57
ALBI grade	1	16 (27.1)	12 (19.7)	0.49
	2	41 (69.5)	48 (78.7)	
	3	2 (3.4)	1 (1.6)	
Largest tumor size, mm, mean (SD)		3.1 (0.4)	3 (0.3)	0.3

Data are presented as number (percentage) unless indicated otherwise.

Abbreviations: AFP, α-fetoprotein; ALBI, albumin-bilirubin grade; ECOG, Eastern Cooperative Oncology Group; IQR, interquartile range; others, see FIGURE 1

Statistical analysis All data analyses were conducted with SPSS Statistics software, version 16.0 (IBM Corp., Armonk, New York, United States). Numerical data with normal distributions are shown as mean (SD), and were analyzed using the *t* test, while variables with skewed distributions are given as median (interquartile range [IQR]), with comparisons conducted using the Mann–Whitney test. Categorical data were analyzed using the χ^2 test. Kaplan–Meier curves

TABLE 2 Treatment responses

Response	TACE alone (n = 59)	Combined treatment (n = 61)	*P* value
Complete response	18 (30.5)	30 (49.2)	0.04
Partial response	18 (30.5)	21 (34.4)	0.65
Stable disease	20 (33.9)	6 (9.8)	0.001
Progressive disease	3 (5.1)	4 (6.6)	0.73
Objective response	36 (61)	51 (83.6)	0.01

Data are presented as number (percentage).

Abbreviations: see **FIGURE 1**

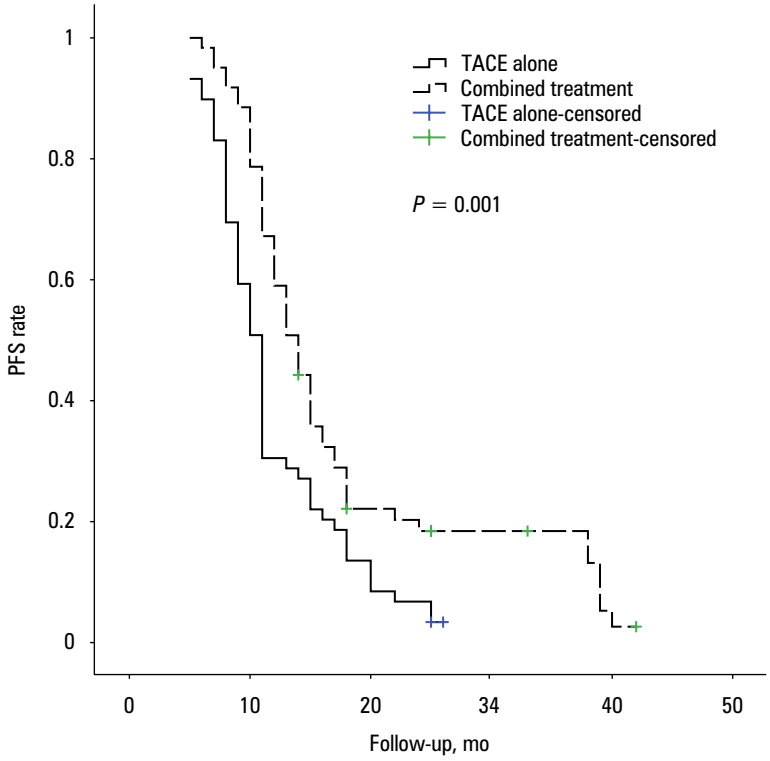

FIGURE 3 Progression-free survival of the groups

Abbreviations: PFS, progression-free survival; others, see **FIGURE 1**

and log-rank tests were utilized for survival assessments. Multivariable Cox proportional hazards regression was applied to identify factors independently predictive of PFS and OS, with those demonstrating a *P* value below 0.1 in univariable analyses entered into the multivariable model. A 2-sided *P* value below 0.05 was deemed significant.

RESULTS **Participant characteristics** The study flowchart is illustrated in **FIGURE 1**. A total of 120 patients were included, of whom 59 underwent TACE alone and 61 received TACE combined with radioactive seed implantation (**FIGURE 2**). The demographics and clinical features of the groups at baseline were comparable (**TABLE 1**).

Treatment response Detailed treatment responses are summarized in **TABLE 2**. The participants who received the combined treatment achieved markedly higher complete response rates than those who underwent TACE alone (49.2% vs 30.5%; *P* = 0.04). In contrast, the partial response rate did not differ substantially between the cohorts (34.4% vs 30.5%; *P* = 0.65). Consequently, the objective response rate (complete plus partial response) was markedly higher in the individuals who underwent the combined therapy, relative to those treated with TACE alone (83.6% vs 61%; *P* = 0.01).

Survival outcomes Median (IQR) follow-up was 20 (15–25) months. Median (IQR) PFS was markedly extended in the combined treatment group, as compared with the TACE-alone cohort (14 [12–16] vs 11 [10–12] mo; *P* = 0.001; **FIGURE 3**). The 1- and 3-year PFS rates were 67.2% and 18.4% in the combined treatment cohort, and 30.5% and 3.4% in the TACE-alone group, respectively. Multivariable Cox regression analysis identified female sex (*P* = 0.03) and albumin-bilirubin (ALBI) grade 3 (*P* = 0.01) as independent predictors of shorter PFS, whereas the combined treatment was independently predictive of prolonged PFS (*P* = 0.002; **TABLE 3**).

During follow-up, 49 individuals in the combined treatment cohort and 45 in the TACE-alone group died. Median (IQR) OS was substantially longer in the patients receiving the combined therapy than those treated with TACE alone (24 [21–27] vs 20 [18–22] mo; *P* = 0.02; **FIGURE 4**). The 1- and 3-year OS rates were 98.4% and 20.2% in the combined treatment group, and 96.5% and 14.4% in the TACE-alone cohort, respectively. The combined treatment was identified as an independent predictor of improved OS (*P* = 0.03; **TABLE 4**).

Adverse events Treatment-related adverse events are detailed in **TABLE 5**. Overall, the adverse event incidence was comparable between the 2 cohorts, with an absence of grade 3–4 adverse events in either. Importantly, no complications related to radioactive seed implantation occurred in the combined treatment group.

DISCUSSION Multitumor HCC encompasses a heterogeneous disease spectrum, ranging from limited oligofocal lesions to diffuse hepatic involvement.[7] Accordingly, treatment strategies for patients with multitumor HCC should be individualized and determined through multidisciplinary

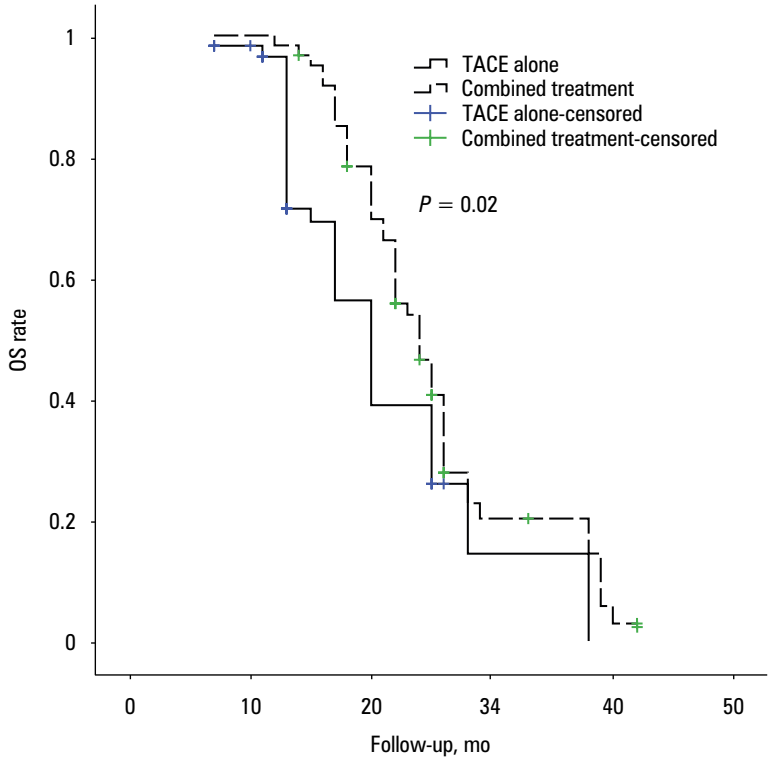

FIGURE 4 Overall survival rate of the groups

Abbreviations: OS, overall survival; others, see **FIGURE 1**

collaboration. Although selected patients may benefit from surgical approaches, current BCLC guidelines recommend TACE as the primary treatment option for most patients with multitumor disease.[7]

In recent years, transarterial radioembolization (TARE) and drug-eluting bead (DEB)-TACE have emerged as alternatives to conventional TACE for the management of liver cancers, including HCC and intrahepatic cholangiocarcinoma.[16,17] In comparison with conventional TACE, TARE, and DEB-TACE have been associated with higher tumor response and improved OS rates in selected populations.[16,17] However, both DEB-TACE and TARE rely on arterial tumor perfusion for effective delivery of therapeutic agents, limiting their efficacy in tumors with poor vascularization.[11,17,18] In contrast, CT-guided radioactive seed implantation is performed via a transhepatic approach, allowing for more homogeneous intratumoral radiation delivery independent of tumor blood supply.[19,20]

A previous meta-analysis showed that TACE with radioactive seed placement was associated with significantly better efficacy and longer survival than TACE alone.[20] However, that meta-analysis mainly included cases with single-tumor HCC, and research focusing on multitumor HCC is still lacking. Our study undertook a direct comparison of the effectiveness and safety of TACE

TABLE 3 Cox regression analysis of progression-free survival

Variable		Univariable analysis			Multivariable analysis		
		Hazard ratio	95% CI	*P* value	Hazard ratio	95% CI	*P* value
Age		0.992	0.966–1.019	0.57	–	–	–
Sex	Men	1	–	–	1	–	–
	Women	1.732	1.111–2.698	0.02	1.692	1.069–2.679	0.03
Hepatitis type	None	1	–	–	–	–	–
	B	1.51	0.845–2.697	0.16	–	–	
	C	1.013	0.517–1.984	0.97	–	–	
ECOG performance status	0	1	–	–	1	–	–
	1	1.478	0.999–2.186	0.05	1.444	0.954–2.186	0.08
Child–Pugh grade	A	1	–	–	–	–	–
	B	1.392	0.886–2.187	0.15	–	–	
BCLC stage	A	1	–	–	–	–	–
	B	0.868	0.59–1.275	0.47	–	–	
ECOG score	0	1	–	–	–	–	–
	1	0.978	0.674–1.419	0.91	–	–	
AFP		1	1–1	0.93	–	–	–
ALBI grade	1	1	–	–	1	–	–
	2	1.352	0.868–2.105	0.18	1.322	0.835–2.092	0.23
	3	5.22	1.507–18.074	0.01	5.267	1.519–18.265	0.01
Largest tumor size		1.037	0.625–1.72	0.89	–	–	–
Treatment methods	TACE alone	1	–	–	1	–	–
	Combined treatment	0.557	0.379–0.817	0.003	0.542	0.368–0.799	0.002

Abbreviations: see **FIGURE 1** and **TABLE 1**

TABLE 4 Cox regression analysis of overall survival

Variable		Univariable analysis			Multivariable analysis		
		Hazard ratio	95% CI	*P* value	Hazard ratio	95% CI	*P* value
Age		0.987	0.958–1.018	0.4	–	–	–
Sex	Men	1	–	–	–	–	–
	Women	0.961	0.584–1.581	0.87	–	–	
Hepatitis type	None	1	–	–	–	–	–
	B	1.623	0.872–3.022	0.13	–	–	
	C	1.057	0.517–2.163	0.88	–	–	
ECOG performance status	0	1	–	–	–	–	–
	1	1.042	0.694–1.566	0.84	–	–	
Child–Pugh grade	A	1	–	–	–	–	–
	B	1.476	0.87–2.504	0.15	–	–	
BCLC stage	A	1	–	–	–	–	–
	B	0.77	0.46–1.288	0.32	–	–	
ECOG score	0	1	–	–	–	–	–
	1	1.042	0.694–1.566	0.84	–	–	
AFP		1	1–1	0.39		–	–
ALBI grade	1	1	–	–	1	–	–
	2	1.22	0.753–1.976	0.42	1.316	0.809–2.139	0.27
	3	3.731	0.846–16.449	0.08	3.941	0.889–17.461	0.07
Largest tumor size		0.823	0.464–1.461	0.51	–	–	–
Treatment methods	TACE alone	1	–	–	1	–	–
	Combined treatment	0.642	0.424–0.972	0.04	0.62	0.407–0.943	0.03

Abbreviations: see **FIGURE 1** and **TABLE 1**

TABLE 5 Adverse events

Adverse event	Any grade			Grade 3–4		
	TACE alone (n = 59)	Combined treatment (n = 61)	*P* value	TACE alone (n = 59)	Combined treatment (n = 61)	*P* value
Abdominal pain	26 (44.1)	30 (49.2)	0.58	0	0	Not applicable
Fever	24 (40.7)	26 (42.6)	0.83	0	0	Not applicable
Nausea	18 (30.5)	17 (27.9)	0.75	0	0	Not applicable
Vomiting	6 (10.2)	7 (11.5)	0.82	0	0	Not applicable
AST increase	6 (10.2)	6 (9.8)	0.95	0	0	Not applicable
ALT increase	7 (11.9)	5 (8.2)	0.5	0	0	Not applicable

Data are presented as number (percentage).

Abbreviations: ALT, alanine aminotransferase; AST, aspartate transaminase; others, see **FIGURE 1** and **TABLE 1**

alone vs TACE used together with radioactive seed implantation in individuals with multitumor HCC. Notably, all tumors in this cohort were treated in a single session of TACE followed by 1-stage radioactive seed implantation. From a theoretical standpoint, simultaneous or closely staged combination therapy may reduce the risk of interim tumor progression, as compared with delayed or sequential approaches.

The addition of radioactive seed implantation significantly enhanced both complete and objective response rates in this study. Although approximately 90%–95% of HCC lesions exhibit necrosis following TACE,[18] embolic agents may be unevenly distributed, particularly in hypovascular tumors. Radioactive seed implantation can therefore serve as an effective adjunct to address residual viable tumor tissue after TACE.[19] The objective response rate of 83.6% observed in the combination cohort was lower than the 92.3% reported by Wang et al,[4] which may be explained by differences in patient populations, as the present study exclusively enrolled patients with multitumor HCC, whereas Wang et al[4] primarily included patients with solitary tumors.

Both PFS and OS were markedly improved with the addition of radioactive seed implantation. ^{125}I seeds have a relatively long half-life and emit

continuous low-dose radiation over a short distance (<1 cm), enabling sustained irradiation of proliferating tumor cells and effective long-term local tumor control.[19] Multivariable Cox regression further confirmed the combined treatment as independently predictive of prolonged PFS and OS. In contrast, ALBI grade 3 was associated with shorter PFS, likely reflecting the adverse impact of impaired hepatic reserve on prognosis. Female sex also emerged as a predictor of shorter PFS, although this finding may be incidental and warrants validation in future studies.

Safety analyses indicated that the addition of radioactive seed implantation did not influence either the incidence or severity of treatment--associated adverse events. No grade 3–4 toxicities were observed, and no seed-related complications occurred, suggesting that this combined approach is well tolerated in patients with multitumor HCC.

Limitations There are multiple limitations to be acknowledged. For one, the retrospective nature of the investigation could have led to selection bias; further prospective randomized studies are required for the confirmation of our findings. Secondly, only patients with 2 HCC lesions were included, as concerns regarding cumulative radiation dose and treatment tolerability precluded the inclusion of individuals with 3 or more tumors. Consequently, the results may not be generalizable to all patients with multitumor HCC. Finally, although patients from 2 centers were included to improve external validity, variability in operator experience may have contributed to procedural heterogeneity.

CONCLUSIONS In summary, the results demonstrate that TACE used together with radioactive seed implantation markedly improves treatment efficacy without compromising safety in individuals with multitumor HCC, as compared with TACE alone. These findings support the use of combined locoregional therapy as a viable treatment option for this patient population.

ARTICLE INFORMATION

ACKNOWLEDGMENTS None.

FUNDING This study was funded by a grant within a program of the Wuxi Health Committee (Z202222; to X-ZH).

CONTRIBUTION STATEMENT G-LM conceived the concept of the study. F-LG and ZS contributed to the design of the research. F-LG, ZS, X-ZH, and G-LM were involved in data collection. D-KC analyzed the data. All authors edited and approved the final version of the manuscript.

CONFLICT OF INTEREST None declared.

AI STATEMENT Artificial intelligence was not used in the preparation of this manuscript.

OPEN ACCESS This is an Open Access article distributed under the terms of the Creative Commons Attribution-NonCommercial-ShareAlike 4.0 International License (CC BY-NC-SA 4.0), allowing third parties to copy and redistribute the material in any medium or format and to remix, transform, and build upon the material, provided the original work is properly cited, distributed under the same license, and used for noncommercial purposes only.

HOW TO CITE Gao F-L, Su Z, Chen D-K, et al. Transarterial chemoembolization with radioactive seed implantation for multitumor hepatocellular carcinoma. Wideochir Inne Tech Maloinwazyjne. 2026; 21: 78-84. doi:10.20452/wiitm.2026.18015

JOURNAL INFORMATION

Videosurgery and Other Miniinvasive Techniques is an official journal of the Videosurgery Foundation.

REFERENCES

1 Ganesan P, Kulik LM. Hepatocellular carcinoma: new developments. Clin Liver Dis. 2023; 27: 85-102.

2 Alawyia B, Constantinou C. Hepatocellular carcinoma: a narrative review on current knowledge and future prospects. Curr Treat Options Oncol. 2023; 24: 711-724.

3 Hartke J, Johnson M, Ghabril M. The diagnosis and treatment of hepatocellular carcinoma. Semin Diagn Pathol. 2017; 34: 153-159.

4 Wang YB, Zhang W, Bao L, et al. Transarterial chemoembolization with insertion of radioactive seeds for hepatocellular carcinoma. Wideochir Inne Tech Maloinwazyjne. 2023; 18: 645-654.

5 Ren Y, Cao Y, Ma H, et al. Improved clinical outcome using transarterial chemoembolization combined with radiofrequency ablation for patients in Barcelona Clinic Liver Cancer stage A or B hepatocellular carcinoma regardless of tumor size: results of a single-center retrospective case control study. BMC Cancer. 2019; 19: 983.

6 Wang YB, Zhang Y, Li PF, et al. Transarterial chemoembolization with ^{125}I seed insertion for multifocal hepatocellular carcinoma. Front Oncol. 2024; 14: 1384293.

7 Risaliti M, Bartolini I, Campani C, et al. Evaluating the best treatment for multifocal hepatocellular carcinoma: a propensity score-matched analysis. World J Gastroenterol. 2022; 28: 3981-3993.

8 Yin L, Li H, Li AJ, et al. Partial hepatectomy vs. transcatheter arterial chemoembolization for resectable multiple hepatocellular carcinoma beyond Milan Criteria: a RCT. J Hepatol. 2014; 61: 82-88.

9 Cassese G, Han HS, Cho JY, et al. Selecting the best approach for the treatment of multiple non-metastatic hepatocellular carcinoma. Cancers (Basel). 2022; 14: 5997.

10 Liu B, Zhang Y, Chen H, et al. The combination of transcatheter arterial chemoembolisation (TACE) and thermal ablation versus TACE alone for hepatocellular carcinoma. Cochrane Database Syst Rev. 2022; 1: CD013345.

11 Gao FL, Wang Y, Huang XZ, et al. I-125 seeds brachytherapy withtranscatheter arterial chemoembolization for subcapsular hepatocellular carcinoma. BMC Gastroenterol. 2022; 22: 273.

12 Hou JP, Shi YB, Fu YF, et al. I-125 seeds insertion with TACE for advanced HCC: a meta-analysis of randomized controlled trials. Minim Invasive Ther Allied Technol. 2022; 31: 848-855.

13 Chalasani N, Younossi Z, Lavine JE, et al. The diagnosis and management of nonalcoholic fatty liver disease: practice guidance from the American Association for the Study of Liver Diseases. Hepatology. 2018; 67: 328-357.

14 Llovet JM, Lencioni R. mRECIST for HCC: performance and novel refinements. J Hepatol. 2020; 72: 288-306.

15 Freites-Martinez A, Santana N, Arias-Santiago S, et al. Using the common terminology criteria for adverse events (CTCAE – Version 5.0) to evaluate the severity of adverse events of anticancer therapies. Actas Dermosifiliogr (Engl Ed). 2021; 112: 90-92.

16 Lu W, Zhang T, Xia F, et al. Transarterial radioembolization versus chemoembolization for hepatocellular carcinoma: a meta-analysis. Front Oncol. 2025; 14: 1511210.

17 Pan SR, Wo XW, Zhu HF, et al. Conventional and drugeluting bead transarterial chemoembolization in patients with inoperable intrahepatic cholangiocarcinoma: a metaanalysis. Wideochir Inne Tech Maloinwazyjne. 2024; 19: 407-413.

18 Ikeda K, Kumada H, Saitoh S, et al. Effect of repeated transcatheter arterial embolization on the survival time in patients with hepatocellular carcinoma. An analysis by the Cox proportional hazard model. Cancer. 1991; 68: 2150-2154.

19 Li J, Zhang L, Xie Q, et al. ^{125}I seeds implantation for treating residual hepatocellular carcinoma located beneath the diaphragm after transcatheter arterial chemoembolization. Brachytherapy. 2019; 18: 420-425.

20 Zhu R, Mao K, Lu XZ, et al. Transarterial chemoembolization with ^{125}I seed insertion for unresectable hepatocellular carcinoma: a meta-analysis. Wideochir Inne Tech Maloinwazyjne. 2025; 20: 30-35.