

This is a provisional PDF only. Copyedited and fully formatted version will be made available soon.

Surgical technique for vesicovaginal fistula repair using the transvaginal flap-fistula offset method

Authors: Xing-Qi Wang, Yi-Ling Cui, Ling Li, Ji-Hong Shen

Article type: Technical note

Received: April 5, 2026.

Revision accepted: June 5, 2026.

Published online: July 9, 2026.

Online ISSN: 2299-0054

Wideochir Inne Tech Maloinwazyjne

DOI: 10.20452/wiitm.2026.18039

Copyright by the Authors, 2026

This is an Open Access article distributed under the terms of the Creative Commons Attribution-NonCommercial-ShareAlike 4.0 International License ([CC BY-NC-SA 4.0](https://creativecommons.org/licenses/by-nc-sa/4.0/)), allowing third parties to copy and redistribute the material in any medium or format and to remix, transform, and build upon the material, provided the original work is properly cited, distributed under the same license, and used for noncommercial purposes only

TECHNICAL NOTE

Surgical technique for vesicovaginal fistula repair using the transvaginal flap-fistula offset method

Xing-Qi Wang*, Yi-Ling Cui*, Ling Li, Ji-Hong Shen

Department of Urology, First Affiliated Hospital of Kunming Medical University, Kunming, China

Correspondence to: Ji-Hong Shen, PhD, Department of Urology, First Affiliated Hospital of

Kunming Medical University, 295 Xichang Road, Kunming, China, phone: +86

13577009705, email: shenjihong@kmmu.edu.cn

Received: April 5, 2026.

Revision accepted: June 5, 2026.

Published online: July 9, 2026.

Wideochir Inne Tech Maloinwazyjne

doi:10.20452/wiitm.2026.18039

Copyright by the Author(s), 2026

* X-QW and Y-LC contributed equally to this work.

Abstract

Vesicovaginal fistula (VVF) is the most common type of urogenital fistula. It is typically caused by iatrogenic injuries, such as those sustained during pelvic surgery. Transvaginal repair is considered the preferred approach due to its minimally invasive advantages.

However, the traditional Latzko procedure or layered closure techniques often sacrifice an

excessive amount of vaginal wall tissue, which can lead to postoperative vaginal shortening and dyspareunia. This study aims to introduce a modified transvaginal flap-fistula offset repair technique. This technique utilizes the offset suturing of anatomical layers. This not only improves the fistula closure rate but also maximally preserves vaginal length and function. A 48-year-old patient who developed a VVF following a total hysterectomy successfully underwent this procedure. The operative time was 45 minutes, with an estimated intraoperative blood loss of 5 ml. The urinary catheter was removed 4 weeks postoperatively, and the patient experienced no urinary leakage. At the 3-month postoperative follow-up, cystoscopy revealed complete closure of the fistula. Her vaginal anatomical morphology and length recovered well, without any sexual dysfunction. The postoperative Female Sexual Function Index questionnaire score improved from 6 preoperatively to 27. The transvaginal flap-fistula offset method can construct a robust tissue barrier and avoid overlapping suture lines. It is a safe, effective, and minimally invasive repair option that maintains vaginal length.

Key words

minimally-invasive surgery, offset flap, transvaginal repair, vesicovaginal fistula

Introduction

Vesicovaginal fistula (VVF) is the most common type of urogenital fistula. It is frequently secondary to iatrogenic injuries caused by pelvic surgeries (such as a hysterectomy), or it results from radiotherapy and chemotherapy for pelvic tumors. Chronic urinary leakage imposes severe psychological, physiological, and social burdens on patients [1]. Currently,

transvaginal repair is regarded as the preferred approach due to its advantages of being minimally invasive and allowing for rapid recovery [2]. However, the commonly used clinical Latzko operation and layered closure techniques involve multi-layer suturing of the vaginal wall. This results in the shortening of the vaginal canal, thereby causing functional complications such as postoperative dyspareunia [3-4]. This study proposes a modified transvaginal flap-fistula offset method. The core concept of this technique is no longer simply excision and approximation. Instead, through extensive flap mobilization and the transposition of the fistula site, the fistula and the vaginal incision are completely separated spatially. This creates an “offset flap” coverage. While improving the success rate of the repair, this approach maximally preserves the functional anatomy of the vagina.

Aim

This study aims to detail the key surgical steps of a novel transvaginal flap-fistula offset method for the repair of vesicovaginal fistula, supplemented with a video vignette.

Materials and methods

Patients This study presents a 48-year-old patient with a vesicovaginal fistula. The patient underwent a total hysterectomy for uterine fibroids 1 year ago and presented with continuous vaginal urinary leakage 3 months postoperatively, which showed no significant change with positional alterations. This severely affected her daily activities and quality of life. A methylene blue test revealed blue staining of the vaginal gauze, confirming the presence of a fistulous tract. Cystoscopy revealed a single fistula in the bladder trigone, located approximately 1.5 cm from the right ureteral orifice. It measured approximately 2 mm × 2 mm, with smooth margins and mild hyperemia of the surrounding mucosa (Figure 1).

Preoperative intravenous pyelography demonstrated the leakage of contrast medium from the bladder into the vagina. Concurrently, the bilateral ureters were well-visualized without dilation or contrast extravasation. This ruled out the possibility of a concomitant ureterovaginal fistula (Figure 2). The preoperative score on the Female Sexual Function Index questionnaire was 6 (2 = low sexual function, 36 = good sexual function). The perineal area and vaginal cavity were irrigated with a diluted povidone-iodine solution for three days preoperatively. This aimed to alleviate the inflammatory edema surrounding the fistula. Upon admission, routine urinalysis indicated a urinary tract infection, and the urine culture was positive for *Escherichia coli*. Susceptible antibiotics were administered for three days preoperatively until the repeat urinalysis and urine culture turned negative.

Surgical technique The procedure was performed by an experienced urogynecologist under general anesthesia, according to the following: 1) Positioning and exposure: The patient was placed in a prone, “frog-leg” position with bilateral lower limb abduction (Figure 3A). Vaginal retractors were utilized to achieve optimal exposure of the anterior vaginal wall and the fistulous orifice. 2) Fistula traction: A 16F Foley catheter was inserted transurethrally. Diluted povidone-iodine solution was instilled into the bladder to irrigate the fistula. A guidewire was passed through the fistula into the bladder to confirm its precise anatomical location (Figure 3B). 3) Hydrodissection: Normal saline was injected into the subvaginal mucosa around the fistula to create a water cushion, facilitating the dissection of anatomical planes (Figure 3C). 4) Flap mobilization: A circular incision was made approximately 0.5 cm from the margin of the fistula (Figure 3D). The vaginal mucosa and muscularis layer were mobilized at least 2 cm circumferentially around the fistula. The dissection length of the left

vaginal flap exceeded 3 cm (Figure 3E). 5) Fistula closure: Fibrotic scar tissue surrounding the fistula was excised. Subsequently, the vesical side of the fistula was closed using a continuous suture with 3-0 absorbable thread (Figure 3F). 6) Fistula transposition and imbrication: The sutured fistula was positioned behind the left vaginal flap, ensuring it was completely transposed beneath the flap (Figure 3G and 3H). 7) Vaginal mucosal closure: The vaginal mucosal incision was closed with 2-0 absorbable sutures using an offset technique to ensure complete spatial misalignment between the incision and the fistula (Figure 3I). 8) Intraoperative testing: 150 ml of diluted methylene blue solution was instilled via the urinary catheter to fill the bladder. The vaginal suture line and surrounding tissues were meticulously inspected for any blue dye egress, confirming a watertight repair. The entire procedure is demonstrated in the *Video*.

Finally, the vagina was packed with povidone-iodine gauze for compressive hemostasis. The urinary catheter was maintained for continuous drainage to keep the bladder in a low-pressure state, thereby reducing tissue tension. This served to minimize the irritation of the anastomosis by urine. The urinary catheter was removed 4 weeks postoperatively. An outpatient follow-up was conducted at 3 months postoperatively to evaluate healing via cystoscopy and vaginal examination.

Ethics This study was approved by the hospital's Ethics Committee (2024-L-240), and written informed consent was obtained from the patient, including explicit consent for the publication of images and video demonstrations.

Results

The patient underwent the surgical procedure successfully. The operative time was 45

minutes, with an estimated intraoperative blood loss of 5 mL. The vaginal packing was removed 24 hours postoperatively. The length of the postoperative hospital stay was 3 days. During the period of catheterization, the patient was administered oral antimuscarinics to prevent elevated intravesical pressure induced by bladder spasms. Topical estrogen cream was applied intravaginally on a daily basis to promote mucosal healing. The urinary catheter was removed 4 weeks postoperatively, at which point the patient reported no symptoms of urinary leakage. At the 3-month outpatient follow-up, cystoscopy revealed a smooth and completely closed mucosa at the site of the original fistula. A vaginal speculum examination demonstrated excellent mucosal healing, well-preserved vaginal length, and an absence of complications such as dyspareunia. The preoperative Female Sexual Function Index questionnaire score was 27, representing a significant improvement compared to the preoperative baseline. No recurrence was observed during the 12-month follow-up period.

Discussion

Advantages and current status of transvaginal repair Surgical approaches for vesicovaginal fistula (VVF) repair include purely transvaginal, transabdominal, transvesical, and combined multimodality approaches. It is generally accepted that transvaginal surgical repair offers multiple advantages [2]. These include minimal surgical trauma, reduced intraoperative blood loss, and shorter operative times. Furthermore, it provides additional benefits such as shorter postoperative hospital stays, high cost-effectiveness, fewer complications, and strong reproducibility. It is primarily indicated for simple fistulas and low-lying fistulas located below the bladder trigone. It is also suitable for VVF patients with severe abdominal organ adhesions or a history of multiple transabdominal surgeries [5]. A

study by Rajamaheswari et al [6] demonstrated that approximately three-quarters of primary VVF repairs can be performed via the transvaginal route; the surgical success rate shows no statistically significant difference when compared to transabdominal repair. Warner et al [7] analyzed and compared the surgical costs associated with transvaginal and transabdominal procedures. Compared to transabdominal surgery, transvaginal repair is more cost-effective due to its shorter operative times and hospital stays. Hillary et al [8] conducted a retrospective analysis of 49 articles. They found that the success rate of transvaginal surgical repair (90.8%) was significantly superior to that of transabdominal repair (83.9%). Theofanides et al [9] reported relevant findings in a retrospective study of 200 patients undergoing VVF repair. Compared with transabdominal repair, transvaginal repair was associated with fewer complications (7% vs. 22%, $P = 0.003$), a shorter length of stay (1.6 ± 2 vs. 3.5 ± 2.3 days, $P = 0.00$), a lower incidence of sepsis (0% vs. 4.3%, $P = 0.02$), a lower blood transfusion rate (0.8% vs. 7.1%, $P = 0.017$), and a lower readmission rate (0.8% vs. 10.1%, $P = 0.003$). Furthermore, in multivariate analysis, transabdominal repair was identified as a significant predictor of complications occurring within 30 days postoperatively. Consequently, the transvaginal repair approach is increasingly valued and favored in clinical practice.

Transvaginal vesicovaginal fistula (VVF) repair primarily includes the Latzko procedure and layered closure techniques. Luo et al [10] combined the traditional Latzko procedure with colpocleisis to pioneer a "deep embedding" method for VVF repair. This technique involves multilayer suturing of the muscularis of the anterior vaginal wall while simultaneously completing the reconstruction of the vaginal apex. This configuration ensures that the vesical suture margin of the fistula is positioned relatively far from the vaginal suture margin. This

achieves the principle of "multilayer coverage and multiple safeguards", thereby enhancing the surgical success rate. However, due to the multilayer suturing of the vaginal wall during the closure process, such procedures inevitably result in vaginal shortening. In a retrospective study of 102 VVF patients who underwent transvaginal surgical repair, Singh et al [11] reported a surgical success rate of 86.3%. Postoperative complications included stress urinary incontinence (9.8%), urgency urinary incontinence (7.8%), and dyspareunia (5.9%).

Panaiyadiyan et al [12] retrospectively analyzed 81 VVF patients following successful surgical repair with a mean follow-up of 29.8 months; the results demonstrated that 24 patients (29.6%) experienced postoperative sexual dysfunction.

Technical advantages of the transvaginal flap-fistula offset repair technique The modified surgical technique introduced in this study overcomes the limitations of traditional procedures. This is achieved through an ingenious flap design and anatomical reduction. Its technical advantages are primarily manifested in the following six aspects: 1) Positional advantage: A prone "frog-leg" position is adopted. This places the fistula at the most dependent point of the surgical field. Concurrently, upward retraction of the vagina by the surgeon provides a more expansive operative exposure than the traditional lithotomy position, facilitating meticulous manipulation. 2) Traction assistance: Intraoperative traction using a guidewire allows for the eversion of the fistula margins. This not only facilitates the identification of the fistula but also provides counter-tension through traction during the procedure. 3) Hydrodissection technique: The subvaginal mucosal injection of normal saline to accomplish hydrodissection is crucial for minimally invasive separation. It effectively expands the tissue spaces, enabling the natural separation of the mucosa from the muscularis

layer, thereby achieving precise anatomical dissection. This avoids injury to the surrounding healthy tissues and creates optimal conditions for tension-free suturing. 4) Extensive mobilization: Extensive intraoperative mobilization of 2 to 3 cm is performed on the flaps surrounding the fistula, particularly the left vaginal flap. An adequate flap area constitutes the foundation for achieving offset coverage. 5) Offset suturing mechanism: The failure of traditional repair methods is frequently attributed to the overlapping of the vesical and vaginal aspects of the fistula. Upon the occurrence of even a minor leakage on the vesical side, urine directly impacts the vaginal incision. This highly predisposes the patient to the formation of a recurrent fistula. This technique involves transposing the vesical aspect of the fistula beneath the mobilized flap (Figure 4A), followed by the closure of the vaginal mucosal incision to ensure complete spatial misalignment between the incision and the fistula (Figure 4B). This artificially creates a lengthy and tortuous potential tract. Even in the presence of micro-leakage on the vesical side, the urine is obstructed by the overlying healthy flap and cannot directly penetrate into the vaginal cavity, thereby allowing sufficient time for spontaneous tissue healing.

It must be emphasized that this study represents a single-case demonstration of a novel surgical procedure. The primary objective of this technical note is to delineate the surgical anatomy and procedural details associated with this approach. In our previous research, we completed a retrospective cohort study including 37 patients who underwent transvaginal flap-fistula offset repair for vesicovaginal fistula (32 single fistulas and 5 multiple fistulas, with fistula diameters ranging from 0.4 to 5.0 cm). With a mean postoperative follow-up of 22.8 months, the anatomical cure rate reached 92% [1]. However, among the 37 patients, 30

underwent offset suturing utilizing an apical flap. At the 3-month postoperative outpatient follow-up, vaginal speculum examinations revealed partial vaginal shortening accompanied by dyspareunia in these cases. Consequently, we modified the surgical approach by selecting a lateral flap for the offset suturing, with the explicit aim of preserving the patient's native vaginal length. The primary objective of this current article is to meticulously detail the operative steps of this modified, innovative surgery. We are conducting large-scale, long-term comparative studies to fully validate its safety and efficacy relative to established therapeutic modalities.

Conclusions

The transvaginal flap-fistula offset suturing technique is a safe, effective, and minimally invasive novel procedure for VVF repair. Through its unique design of "fistula transposition" and "flap coverage," this procedure successfully establishes a multiple anti-leakage barrier. Concurrently, it effectively resolves the dilemma of vaginal shortening associated with traditional transvaginal surgeries. The accumulation of additional clinical cases in the future remains necessary to further validate the long-term efficacy of this technique.

Article information

Video The video file is available online at <https://dx.doi.org/10.20452/wiitm.2026.xxxx>.

Acknowledgments We would like to express our gratitude to the women who participated in this study.

Funding This research was funded by the National Natural Science Foundation of China (82260297) and the Research on the Development and Application of a Biomechanical

Prediction Model and Intelligent Clinical Diagnosis and Treatment for Pelvic Floor Dysfunction Caused by Pregnancy- and Childbirth-Related Injuries and Age-Related Structural Degeneration (202502AA310034).

Contribution statement XQW and JHS conceived the concept of the study. XQW and YLC contributed to the design of the research. All authors were involved in the data collection. YLC and LL analyzed the data. XQW and YLC drafted the original manuscript. XQW and YLC reviewed and edited the manuscript. JHS coordinated the funding for the project. All authors edited and approved the final version of the manuscript.

Conflict of interest None declared.

AI statement Artificial intelligence was not used in the preparation of this manuscript.

Open access This is an Open Access article distributed under the terms of the Creative Commons Attribution-NonCommercial-ShareAlike 4.0 International License (CC BY-NC-SA 4.0), allowing third parties to copy and redistribute the material in any medium or format and to remix, transform, and build upon the material, provided the original work is properly cited, distributed under the same license, and used for noncommercial purposes only.

How to cite Wang XQ, Cui YL, Li L, et al. Surgical technique for vesicovaginal fistula repair using the transvaginal flap-fistula offset method. *Wideochir Inne Tech Maloinwazyjne*. 2026 Jul 9. [Epub ahead of print]. doi:10.20452/wiitm.2026.18039

Journal information

Videosurgery and Other Miniinvasive Techniques is an official journal of the Videosurgery Foundation.

References

- 1 Wang X, Gao Z, Li L, et al. Clinical efficacy of flap transfer coverage in the treatment of vesicovaginal fistula. *Int Urogynecol J.* 2023; 34: 1797-1802.
- 2 Iyer SM, Singh S, Srivastav A. Analysis of various surgical approaches to supratrigonal vesicovaginal fistula repair: a tertiary care centre experience. *Int Urogynecol J.* 2025; 36: 1273-1279.
- 3 Goh J, Browning A, Slinger G, Trautvetter L. FIGO expert opinion management of post-obstetric fistula repair incontinence for vesicovaginal fistula. *Int J Gynaecol Obstet.* 2026; 172: 210-214.
- 4 Wei N, Pfeuti C, Linder BJ. Contemporary genitourinary fistula management: treatment, trends, and innovations. *Curr Opin Obstet Gynecol.* 2025; 37: 432-437.
- 5 Giusti G, Lucci Chiarissi M, Abate D, et al. Early repair of post-hysterectomy vesicovaginal fistulae through a laparoscopic transperitoneal extravesical approach. Experience of a single center. *Urology.* 2018; 119: 44-48.
- 6 Rajamaheswari N, Chhikara AB, Seethalakshmi K, et al. Trans-vaginal repair of gynecological supratrigonal vesicovaginal fistulae: a worthy option! *Urol Ann.* 2012; 4: 154-157.
- 7 Warner R, Beardmore-Gray A, Pakzad M, et al. The cost effectiveness of vaginal versus abdominal repair of vesicovaginal fistulae. *Int Urogynecol J.* 2020; 3: 1363-1369.
- 8 Hillary CJ, Osman NI, Hilton P, Chapple CR. The aetiology, treatment, and outcome of urogenital fistulae managed in well- and low-resourced countries: a systematic review. *Eur Urol.* 2016; 70: 478-492.

9 Theofanides MC, Sui W, Sebesta EM, et al. Vesicovaginal fistulas in the developed world: An analysis of disease characteristics, treatments, and complications of surgical repair using the ACS-NSQIP database. *Neurourol Urodyn.* 2017; 36: 1622-1628.

10 Luo DY, Shen H. Transvaginal repair of apical vesicovaginal fistula: a modified Latzko technique - outcomes at a high-volume referral center. *Eur Urol.* 2019; 76: 84-88.

11 Singh V, Sinha RJ, Sankhwar SN, et al. Transvaginal repair of complex and complicated vesicovaginal fistulae. *Int J Gynaecol Obstet.* 2011; 114: 51-55.

Panaiyadiyan S, Nayyar BU, Nayyar R, et al. Impact of vesicovaginal fistula repair on urinary and sexual function: patient-reported outcomes over long-term follow-up. *Int Urogynecol J.* 2021; 32: 2521-2528.

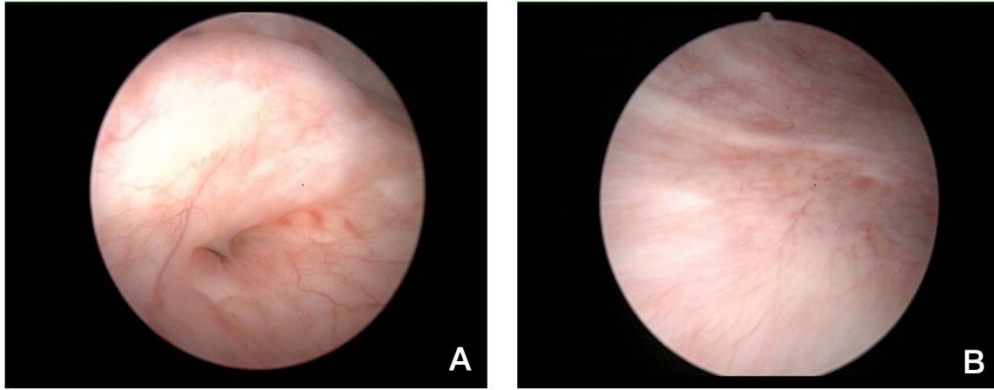


Figure 1 Pre- and postoperative cystoscopic views; **A** – cystoscopy reveals a fistula in the bladder trigone; **B** – cystoscopy shows an old scar in the bladder trigone

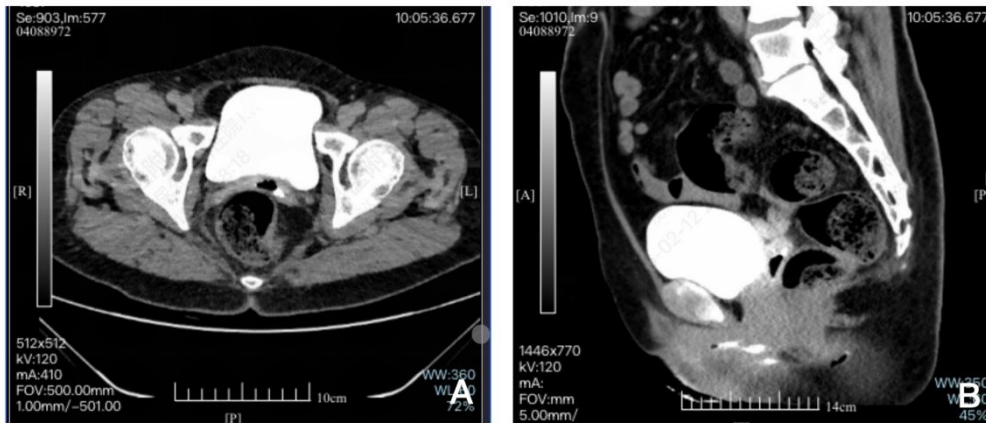


Figure 2 Preoperative intravenous pyelography demonstrates contrast medium leaking into the vagina; **A** – axial plane; **B** – sagittal plane

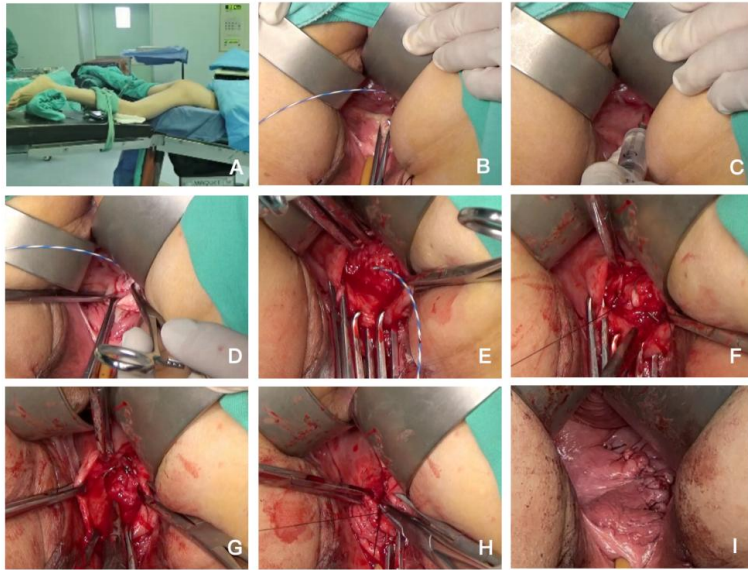


Figure 3 Schematic diagram of the transvaginal flap-fistula offset technique;

A – surgical positioning; **B** – placement of a guidewire for fistula traction; **C** – adequate hydrodissection performed around the fistula; **D** – a circular incision made 0.5 cm from the margin of the fistula; **E** – mobilization of the fistula and the surrounding vaginal flaps; **F** – continuous suturing of the fistula; **G, H** – transposition and imbrication of the fistula beneath the vaginal flap; **I** – offset suturing of the vaginal mucosa

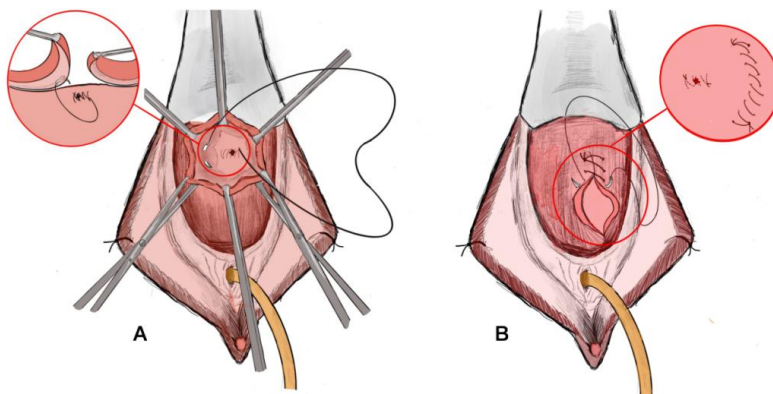


Figure 4 Schematic diagram of the offset suturing mechanism; **A** – transposition and imbrication of the fistula beneath the vaginal flap; **B** – offset suturing of the vaginal mucosa

Short title: Flap-fistula offset for vesicovaginal fistula repair